

# Biomechanical and Clinical Assessment for Jaw Movement and the Related TMJ Loading in Patients with Temporomandibular Joint Disorders

E. Tanaka\*, M. Hirose, E. Yamano, and K. Tanne

Department of Orthodontic and Craniofacial Developmental Biology, Hiroshima University Graduate School of Biomedical Sciences, 1-2-3 Kasumi, Minami-ku, Hiroshima 734-8553, Japan. \*corresponding author, etanaka@hiroshima-u.ac.jp

## ABSTRACT

Temporomandibular joint disorders (TMD) have been demonstrated to be a multifactorial in nature. Possible explanations for the causes have been documented in the literature indicating excessive loading during jaw movement and the subsequent biomechanical imbalance in the TMJ may be assumed as an initial factor for a series of degenerative changes, resulting in condylar resorption and deformity. Therefore, an evaluation of the biomechanical environment in the TMJ would lead to a better understanding of the inducing mechanism of TMJ pain and disability, which result in proper diagnosis and available treatment planning for TMD. Recently, we developed an individual three-dimensional modeling system for the TMJ components based on the magnetic resonance (MR) image and the subsequent analysis of the TMJ loading during jaw movement. The present study was thus designed to introduce biomechanical and clinical assessment of jaw movement and the subsequent joint loading in patients with TMD. Furthermore, we would like to show a case of TMD patient treated with orthodontic approach to introduce an example of the assessment with this system.

**KEY WORDS:** temporomandibular joint disorders, joint loading, jaw movement, orthodontic treatment

## INTRODUCTION

In the field of clinical dentistry, temporomandibular joint disorders (TMDs) are one of the major diseases as well as dental caries and periodontitis. TMDs have been defined as intraarticular morphologic abnormalities, such as different forms of disc displacement, degenerative joint disease, inflammatory arthritis, synovitis and congenital and neoplastic anomalies. Epidemiologic surveys report that 20% to 25% of the population have symptoms of TMD (Solberg *et al.*, 1979; Carlsson, 1999), although only one fifth of those with TMD symptoms require treatment (Gray *et al.*, 1995). Interestingly, it has been observed that up to 70% of patients with TMD suffer from displacement of the disc (Farrar and McCarty, 1979), which is so-called internal derangement of the temporomandibular joint (TMJ-ID).

TMJ-ID defined as an abnormal positional relationship of the disc relative to the mandibular condyle and the glenoid fossa, is accompanied with TMJ pain, clicking

and/or crepitus, muscle tenderness, and limitation of mouth opening as the symptoms (Katzberg *et al.*, 1980; Westesson *et al.*, 1986). The return to prominence of the concept of TMJ-ID has contributed greatly to treatment of the TMJ dysfunction. The role of the disc in the progression of TMJ-ID is controversial. Initially, it was postulated that disc displacement preceded the onset of osteoarthritic changes in the TMJ (Nickerson and Boering, 1989). The high association of articular degradation with disc malposition, however, has led some investigators to suggest that the degenerative process predisposes to disc displacement (Dijgraaf *et al.*, 1995; Nitzan, 2001).

From a review of etiological events of TMJ disc displacement, trauma, functional overloading, joint laxity, degenerative joint disease and increased joint friction are considered to play a major role in the etiology of disc displacement (Nitzan, 2001). Therefore, an evaluation of the biomechanical environment in the TMJ would lead to a better understanding of the inducing mechanism of TMJ pain and disability, which result in proper diagnosis and available treatment planning for TMDs.

Recently, we have developed an individual three-dimensional (3-D) modeling system for the TMJ based on the magnetic resonance (MR) image and the subsequent analysis of TMJ loading during jaw movement (Tanaka *et al.*, 2001). The present study was thus designed to introduce biomechanical and clinical assessment for jaw movement and the subsequent joint loading in patients with TMDs. Furthermore, we would like to present a case of TMD patient treated with orthodontic approach to introduce the assessment by this system.

## CLINICAL AND RADIOGRAPHICAL ASSESSMENT

Most of patients visit orthodontic clinic in Hiroshima University Hospital with a chief complaint of malocclusion, occlusal disturbance and facial esthetic problem. However, recently, the number of patients with a complaint of TMD increases, and 20% or more patients in our clinic have at least one symptom and/or sign of TMD such as TMJ pain, muscle pain, limited mouth opening, and unidentified complaint at the initial stage.

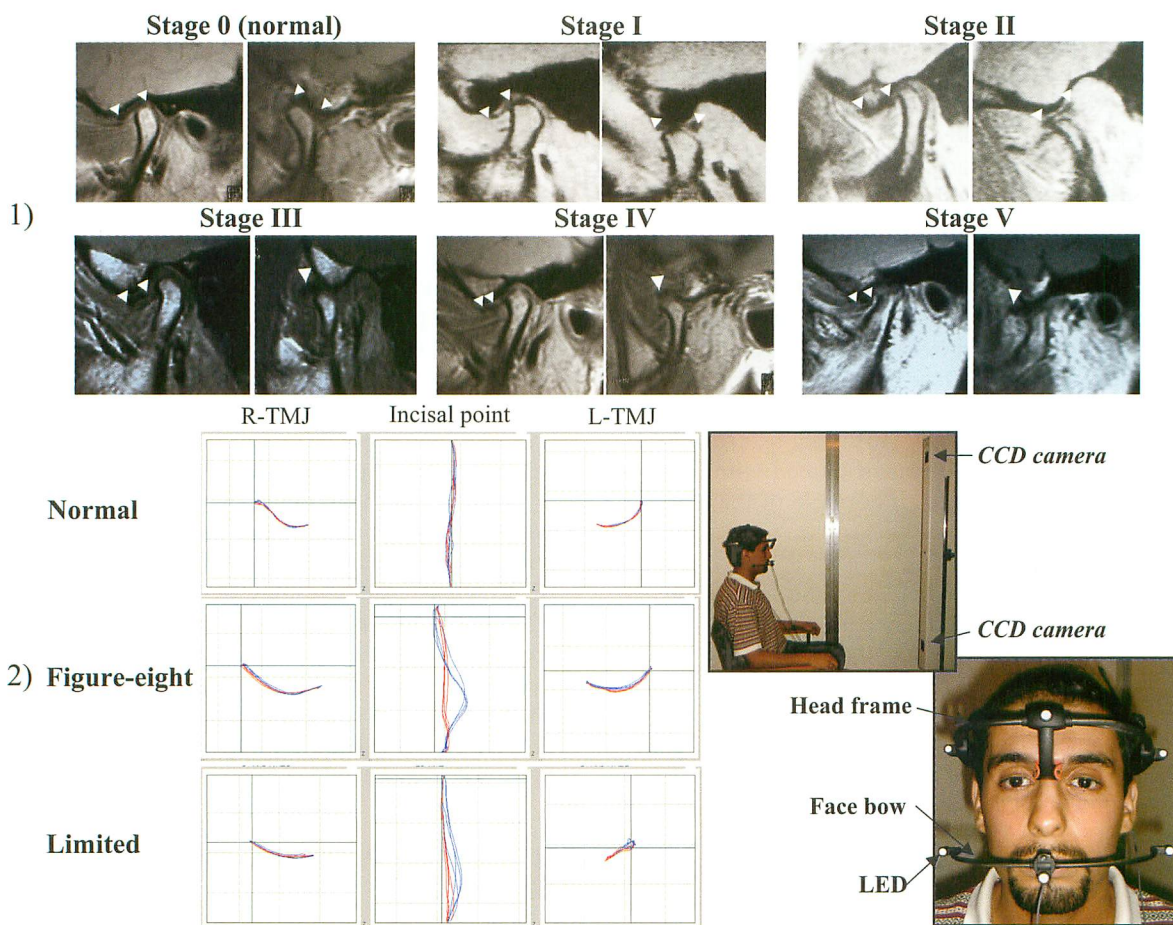
When the patient comes to our clinic, irrespective of presence of TMD complaint, differential diagnosis for TMD and the intraarticular pathology are conducted prior to orthodontic treatment. At first, we evaluate a his-

tory of the present illness, and conduct clinical examination. The three cardinal components in the clinical examination are range of mandibular movement, palpation tenderness, and joint sounds. After initial interview for a history of TMD and clinical examination, if the patient has any symptom and sign of TMD, radiographic examinations are performed; Panoramic radiograph and Schuller's method as a simple radiographs, and CT as a 3-D precise radiograph. From radiographic findings, dysfunctional bone remodeling and degenerative bone deformation can be detected. If these abnormal bony changes are present, the patient is diagnosed as osteoarthritis in the TMJ (TMJ-OA). However, radiographs could not provide the spatial and structural information for the TMJ disc.

After radiographic evaluation, each patient undergoes a MR examination. Specific note is made in each case of the presence or absence and radiologic stage of

TMD (Figure 1-1) (Wilkes, 1989), as well as such findings as joint effusion, articular surface irregularities, and alterations of bone marrow signal in the mandibular condyle, condylar neck, and temporal bone. Stage I indicating a simple disc displacement, is minimal early stage of TMJ derangement. Stage II and III, intermediate stage of TMJ derangement, reveal anterior disc displacement with or without reduction but not bony remodeling and deformation. Stage IV is intermediate-late stage of TMJ derangement with abnormal bone deformation. Stage V shows severe disc and bony degeneration or remodeling such as severe sclerosis, osteophyte, flattening and erosion in the condylar cortical bone.

In order to assess gnathostomatologic functions in TMD patients, analysis of condylar movement is conducted. Jaw movement is analyzed using a six-degree-of-freedom optoelectric mandibular motion recording system (Gnathohexagraph<sup>®</sup>, JM-1000, Ono Sokki,



**Fig. 1** MR images of the TMJ (1) and condylar trajectory during jaw-opening and -closing movements (2)  
 From MR images, radiographical stage of TMD was distinguished: Stage 0 indicates a normal TMJ. The white arrowheads indicate the anterior and posterior borders of the disc. Both at closing and opening positions, the disc locates between condylar and temporal bone surfaces. Stage I indicates a simple disc displacement. This is minimal early stage of TMJ derangement. Stage II is intermediate stage of TMJ derangement. MR image at the intercuspal position reveals anterior disc displacement but not bony remodeling and deformation. Stage III is also intermediate stage of TMJ derangement with disc displacement without reduction. Through mandibular movements, the disc is displaced from its normal position and on full opening. Stage IV is intermediate-late stage of TMJ derangement. The disc displaces anteriorly without reduction. The bony abnormal deformity was clearly detected. Stage V shows severe disc and bony degeneration or remodeling such as severe sclerosis, osteophyte, flattening and erosion in the condylar cortical bone.  
 By Gathohexagraph, condylar movements are recorded during voluntary maximum jaw-opening and -closing movement. Blue lines indicate jaw-opening movement and red lines jaw-closing movement.

Yokohama, Japan), which consists of a head frame, a face bow, light-emitting diodes (LEDs), CCD cameras, and a personal computer (Figure 1-2). The head frame with three LEDs was placed on the head parallel to the Frankfort horizontal (FH) plane of the subject, and the face bow was set to the mandible through the use of a dental clutch. The dental clutch was attached to the labial surface of the lower anterior teeth by means of cryanoacrylate adhesive. Two CCD cameras were placed in front of the subject. The position of each LED was determined three-dimensionally according to the parallax principle. The condylar points of the both sides are recorded by use of a pointer with two LEDs and calculated based on the respective three-dimensional positions of 6 LEDs attached to the head frame and face bow recorded by the pointer.

Condylar movements are recorded during voluntary maximum jaw-opening and -closing movement (Figure 1-2). Movement of the central point between the right and left central incisors is also recorded as a reference for definition of opening- and closing-phases. Sagittal condylar movement pattern (SCMP) can be categorized into six patterns: normal, figure-eight (early/intermediate/late), limited and other irregularities (Ozawa and Tanne, 1997). Limited pattern is likely to indicate closed lock (disc displacement without reduction) in stage III, IV or V. Figure-eight pattern was also regarded as stage I or II with reducible disc displacement in the radiographical stage of TMD although SCMP is not yet accurate enough

for diagnosing a specific TMJ condition especially a condition of chronic and/or adaptive TMJ-ID (Ozawa and Tanne, 1997).

### BIOMECHANICAL ASSESSMENT OF TMJ LOADING

We developed an individual 3-D modeling program for the TMJ based on MR images in order to conduct the biomechanical assessment for TMJ loading during jaw movement.

#### Reconstruction of 3-D TMJ model

For each patient, the MR images are taken in the axial, sagittal and coronal directions (Figure 2). The axial scans parallel to the Frankfort plane are taken in order to determine the long axis of the condyle. Based on the axial images, the sagittal plane of imaging is designed to be perpendicular to the long axis of the condyle. The coronal plane of imaging is determined to be perpendicular to the median sagittal plane and the Frankfort plane. The two sets of parallel lines in axial slice indicated the positions of the imaged sagittal and coronal planes (Figure 2). The sagittal images of the TMJ for each subject are acquired with the dentition in full intercuspal occlusion and maximum mouth opening. The coronal images were obtained and used for reconstruction of the medial and lateral portions.

The reconstruction technique used in this study has

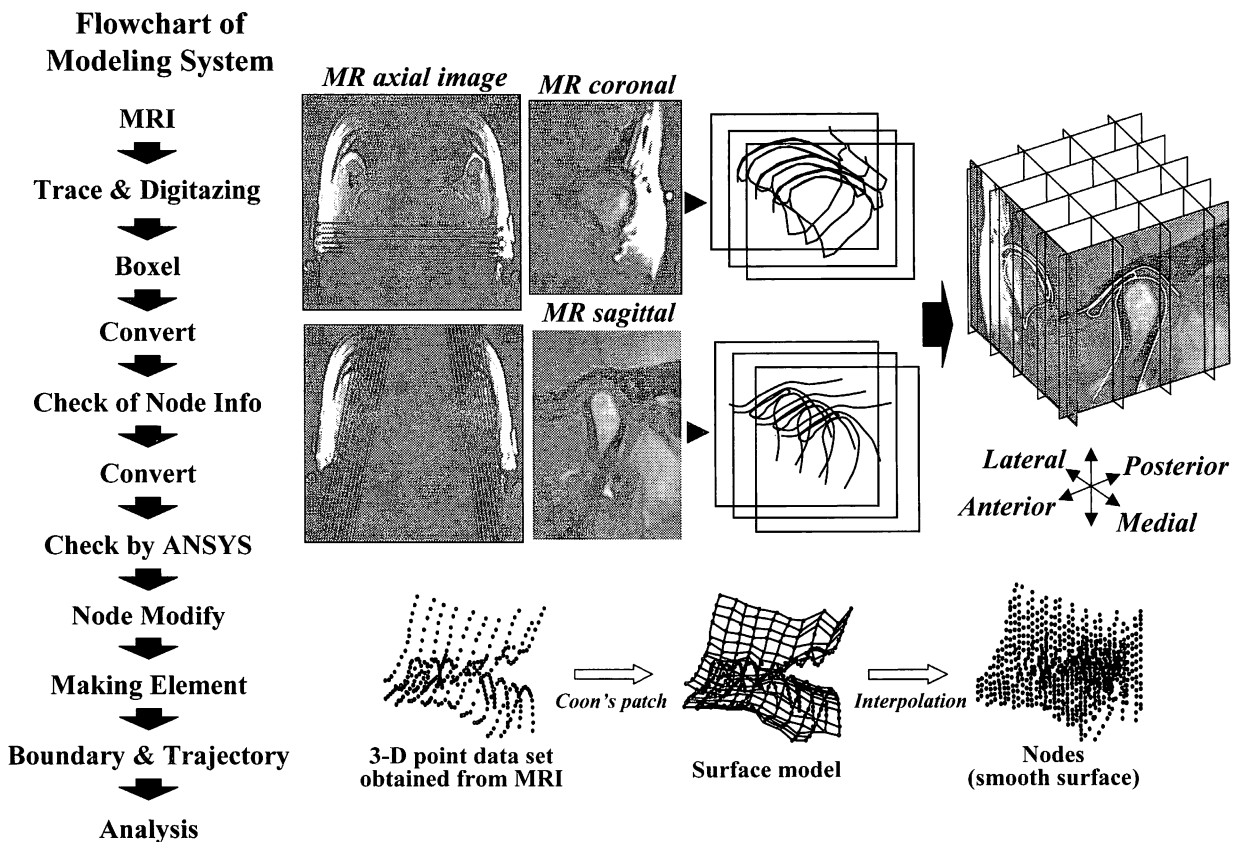


Fig. 2 Reconstruction procedure of TMJ from MR images.

already been described in detail elsewhere (Tanaka *et al.*, 2001). Briefly, from both the sagittal and coronal tracings the articular surfaces were approximated separately by using Coon's patches (Figure 2). Both approximations were fitted to each other and averaged. The shapes of the lateral and medial end portions of the condyle and articular disc could not be traced from the sagittal slices of the MR images. Therefore, the shapes of these areas were determined only by use of the coronal slices. The upper and lower boundaries of the articular disc were shaped according to the upper and lower articular surfaces. Interface elements were placed at the bone-disc crossing so as to allow the disc to deform and to move along the articulating surfaces without penetration. Because of the detective limit of the MR images, the tissue surrounding to the articular disc was modeled as a single connective tissue mass. As a consequence, the number of nodes for each model was 380 in the condyle, 1047 in the glenoid fossa and 697 in the soft tissues including the articular disc. Finally, the TMJ model has been constructed, consisting of 2024 nodes and 8056 elements (Figure 3-1).

**Stress analysis in the TMJ during jaw opening**

The material properties of TMJ components used in this analysis were assumed to be linear elastic and were taken from literatures (Tanaka *et al.*, 2000, 2001). The model of

the glenoid fossa was restrained for all degrees of freedom at its superior region.

TMJ receives various loading not only during clenching but also during jaw opening. Furthermore, the condylar movement during various mandibular movements especially jaw opening, produces remarkable disc motion. Then, stress analysis in the TMJ is commonly performed during jaw opening. The condylar displacement was enforced at the distal end of the condylar part as the loading condition (Chen and Xu, 1994). The condylar movements during jaw opening were recorded by use of Gnathohexagraph as described above. Thus, this set of recordings gives us the 3-D condylar pathway and its time course during function. By enforcing the calculated displacement to the distal end of the condylar model, the condyle moves incrementally along the condylar trajectory recorded by Gnathohexagraph. The stress analysis was executed on a personal computer with the finite element software, ANSYS from ANSYS Inc. (Houston, USA). In this analysis, von Mises stress distributions in the TMJ soft tissues are commonly evaluated from 0% to 100% opening with 10% increments of opening.

Figure 3-2 shows the results of stress analysis in the TMJ disc during jaw opening (del Pozo *et al.*, 2003; Tanaka *et al.*, 2004). During jaw opening, stress distributions in the asymptomatic patients showed relatively

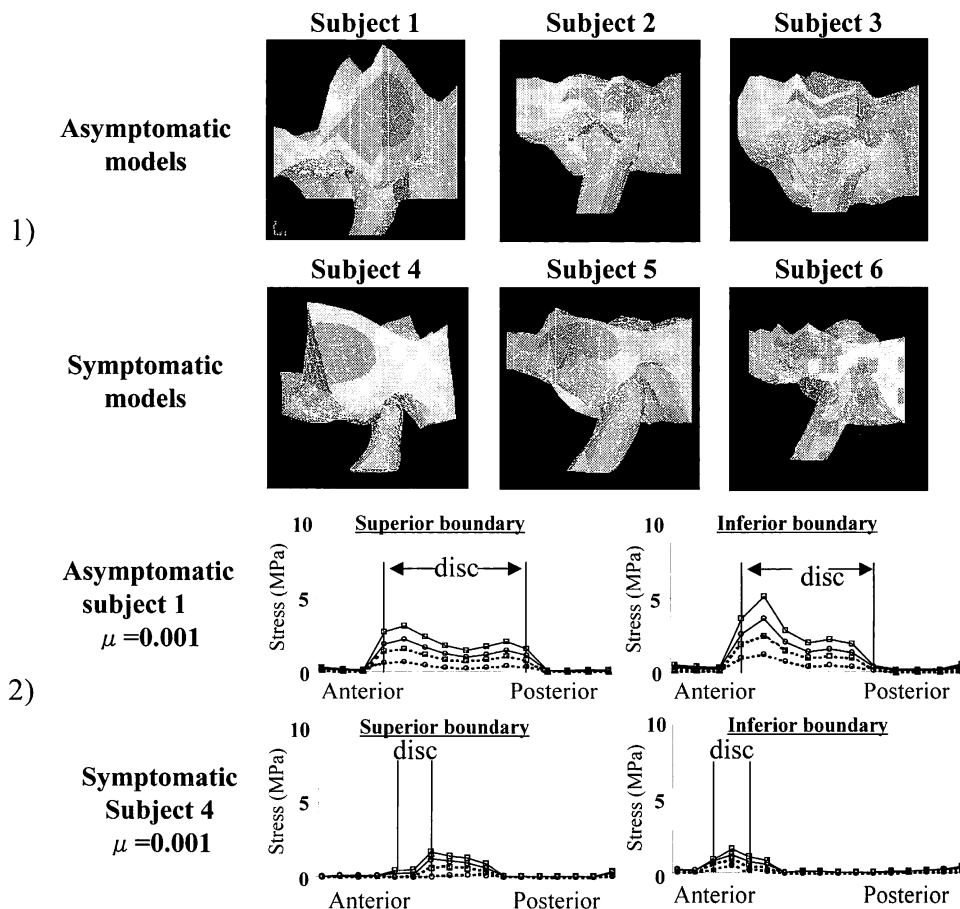


Fig. 3 Three-dimensional finite element models of TMJ (1) and stress distribution on the surfaces of the disc and retrodiscal tissue during jaw opening (2).

high von Mises stresses in the anterior and lateral portions of the disc. The stress distribution pattern on the superior boundary of the disc was similar to that on the inferior boundary. In the soft tissues, the stress level through opening was much lower than in the disc. Meanwhile, a common characteristic in the symptomatic patients was the fact that von Mises stresses were higher in the central and posterior portions of the disc and progressively increased through jaw opening. In the soft tissues stress values were higher in the retrodiscal tissue adjacent to the disc through jaw opening comparing to those in the asymptomatic subjects. The retrodiscal tissue is vessel- and nerve-rich connective tissue, and normally it is not load-bearing organ. Therefore, the TMJ pain assumes to be due to compression in the retrodiscal tissue during jaw opening.

These results provide an important clinical indication such that the best way to reduce the symptoms complained is antero-inferior repositioning of the condyle against the glenoid fossa, resulting in achievement of stress reduction in the retrodiscal tissues.

### AN EXAMPLE OF BIOMECHANICAL AND CLINICAL ASSESSMENT FOR A TMD PATIENT TREATED WITH ORTHODONTIC APPROACH

The patient was a 24-year 6-month-old female who had a severe anterior open bite and crowding with a Class II molar relationship (Figure 4-1). She complained of occlusal disturbances and difficulty of lip closure because of her open bite. For TMJ signs and symptoms, she had been TMJ pain during mastication and temporal difficulty of mouth opening for at least 3 years. Her facial profile was convex with a long anterior facial height. Overjet and overbite were +3 mm and -3 mm, respectively. Maximum mouth opening without pain was 31 mm, and TMJ crepitus was detected on both sides.

From the model analysis, the arch length discrepancy was -5.1 mm on the upper and -6.6 mm on the lower arch. The cephalometric analysis indicated the features of a skeletal open bite. The mandible exhibited a backward and downward rotation. MR images showed stage III with no reducible disc displacement in both TMJs

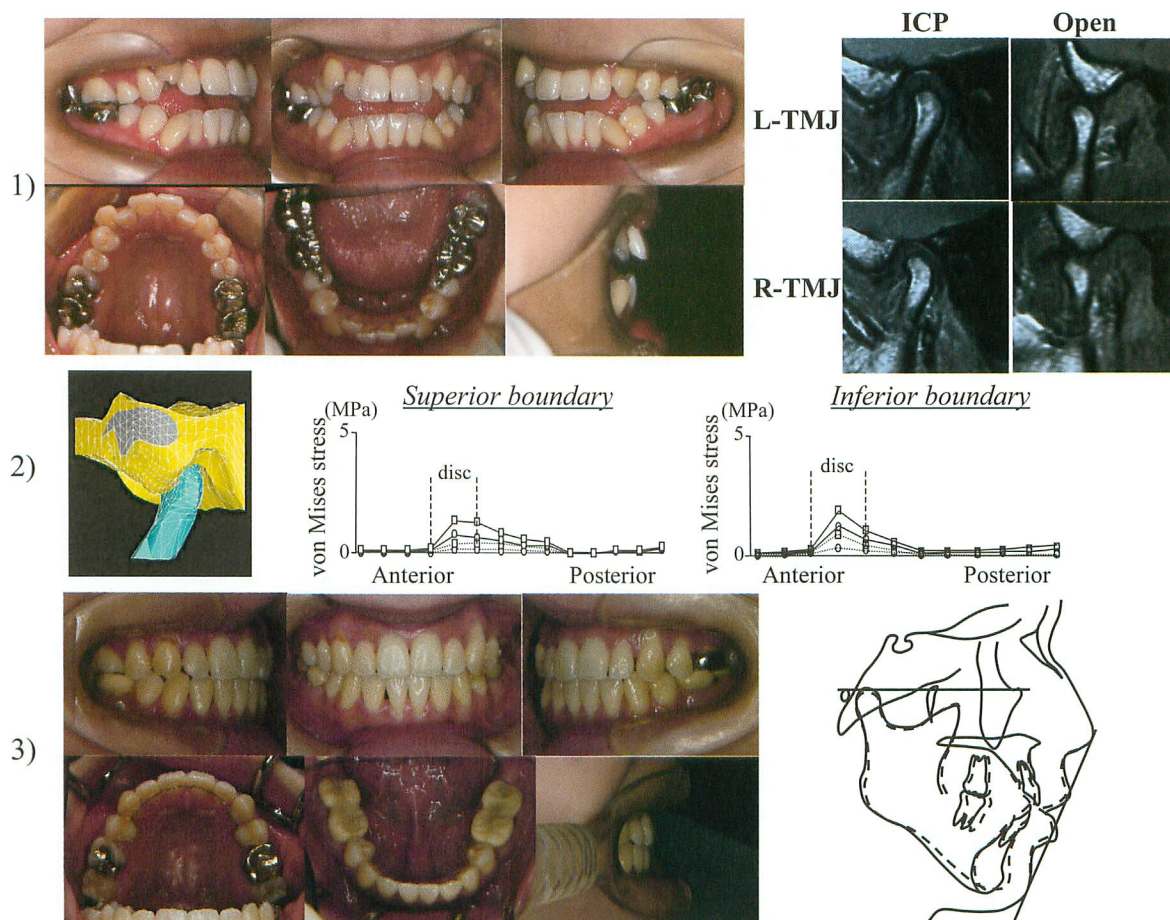


Fig. 4 Example case diagnosed by biomechanical assessment system and treated with orthodontic approach.  
 (1) Intraoral photos and MR images at the initial stage.  
 (2) Three-dimensional TMJ model and stress distribution on the surfaces of the disc and retrodiscal tissue during jaw opening.  
 (3) Intraoral photos after treatment and superimposition of cephalometric tracings before (solid line) and after (dotted line) treatment.

although both condyle showed no abnormal bony changes (Figure 4-2). The degree of disc displacement was very severe on the both sides, and at closed position, the posterior band of the disc had no contact with the condyle, and the retrodiscal tissue might replace the disc as a stress absorber. Then, using our 3-D modeling program, biomechanical assessment of TMJ loading during jaw opening was conducted (Figure 4-2). As the result, the relatively high stress was found at the posterior band of the disc, and the stress level progressively increased in opening (Figure 4-2). With respect to the retrodiscal tissue, the stress level was almost similar to that in the disc. This implies that the retrodiscal tissue suffered from excessive stress during mouth opening.

From these findings, this case was diagnosed as a skeletal open bite with a long lower anterior facial height and TMJ-ID. The treatment plan is 1) initial splint therapy for anteroinferior repositioning of the condyle and calmness of TMJ symptom, 2) bilateral extraction of the upper second and lower third molars and the upper and lower second premolars for correction of anterior open bite and crowding, 3) placement of multi-bracket appliances for tooth alignment, and 4) mesial movement of the upper and lower molars in order to induce a counterclockwise mandibular rotation.

After 2-year orthodontic treatment, a well-balanced facial profile and an acceptable occlusion were achieved and the multibracket appliances were removed. Overall facial balance and her profile were improved. The lower anterior facial height was decreased and the lips showed less tension in a lip closure. Acceptable occlusion was achieved, and the overbite was improved to 1.2 mm and the overjet to 1.5 mm (Figure 4-3). The molar relationships were changed to Class I in the both sides. With respect to TMD, since most of the symptom and signs were reduced or disappeared by the initial splint therapy, no recurrences were not detected. Cephalometric analysis indicated a counterclockwise rotation of the mandible, resulting in anteroinferiorly repositioning of the condyles (Figure 4-3).

## CONCLUSIONS

Up to present, more than 30 patients with TMJ-ID or -OA were diagnosed by this biomechanical and clinical assessment of jaw movement and the subsequent TMJ loading, and underwent the orthodontic treatment for occlusal reconstruction. Most of the patients, but not all, recognized reduction of TMD symptoms and achieved functional and acceptable occlusion with long-term stability. Thus, it is confirmed that stress reduction in the TMJ with this therapeutic system is effective in most TMD cases.

## REFERENCES

- Carlsson GE (1999). Epidemiology and treatment need for temporomandibular disorders. *J Orofac Pain* 13:232-237.
- Chen J, Xu L (1994). A finite element analysis of the human temporomandibular joint. *J Biomech Engng* 116: 401-407.
- del Pozo R, Tanaka E, Tanaka M, Kato M, Iwabe T, Hirose M, Tanne K (2003). Influence of friction at articular surfaces of the temporomandibular joint on stresses in the articular disk: A theoretical approach with the finite element method. *Angle Orthod* 73:319-327.
- Dijkgraaf LC, de Bont LGM, Boering G, Liem RSB (1995). The structure, biochemistry and metabolism of osteoarthritic cartilage: a review of the literature. *J Oral Maxillofac Surg* 53:1182-1192.
- Farrar WB, McCarty WL Jr (1979). The TMJ dilemma. *J Ala Dent Assoc* 63:19-26.
- Gray RJM, Davies SJ, Quayle AA (1995). Temporomandibular Disorders: a clinical approach. Brit Dent Assoc, London.
- Katzberg RW, Dolwick MF, Helms CA, Hopens T, Bales DJ, Cogg GC (1980). Arthrotomography of the temporomandibular joint. *Am J Roentgenol* 134: 995-1003.
- Nickerson JW, Boering G (1989). Natural Course of osteoarthritis as it relates to internal derangement of the temporomandibular joint. *Oral Surg Clin NA* 1:27-45.
- Nitzan DW (2001). The process of lubrication impairment and its involvement in temporomandibular joint disc displacement: a theoretical concept. *J Oral Maxillofac Surg* 59:36-45.
- Ozawa S, Tanne K (1997). Diagnostic accuracy of sagittal condylar movement patterns for identifying internal derangement of the temporomandibular joint. *J Orofac Pain* 11:222-231.
- Solberg WK, Woo MW, Houston JB (1979). Prevalence of mandibular dysfunction in young adults. *JADA* 98:25-34.
- Tanaka E, Rodrigo DP, Miyawaki Y, Lee K, Yamaguchi K, Tanne K (2000). Stress distribution in the temporomandibular joint affected by anterior disc displacement: a three-dimensional analytic approach with the finite-element method. *J Oral Rehabil* 27:754-759.
- Tanaka E, Rodrigo DP, Tanaka M, Kawaguchi A, Shibazaki T, Tanne K (2001). Stress analysis in the TMJ during jaw opening by use of a three-dimensional finite element model based on magnetic resonance images. *Int J Oral Maxillofac Surg* 30: 21-430.
- Tanaka E, del Pozo R, Tanaka M, Asai D, Hirose M, Iwabe T, Tanne K (2004). Three-dimensional finite element analysis of human temporomandibular joint with and without disc displacement during jaw opening. *Med Eng Phys* 26:503-511.
- Westesson P-L, Bronstein SL, Leiberg JL (1986). Temporomandibular joint: correlation between single-contrast videoarthrography and postmortem morphology. *Radiol* 160:767-771.
- Wilkes CH (1989). Internal derangements of the temporomandibular joint. Pathological variations. *Archs Otolaryngol* 115:469-477.