

## Subsequent Rupture after Clip on Wrap Method for Ruptured Dissecting Aneurysm of the Distal Middle Cerebral Artery: A case report and review of the literature

Shigeyuki SAKAMOTO, Fusao IKAWA, Hitoshi KAWAMOTO, Naohiko OHBAYASHI  
and Tetsuji INAGAWA

*Department of Neurosurgery, Shimane Prefectural Central Hospital, Himebara-cho, Izumo-shi, Shimane  
693-8555, Japan*

### ABSTRACT

Dissecting aneurysms rarely occur in the middle cerebral artery (MCA). Furthermore, recurrent subarachnoid hemorrhage from ruptured dissecting aneurysms is rare with no published report of subsequent rupture after treatment by the clip on wrap method.

The case reported is a 41-year-old man with subarachnoid hemorrhage. Angiography demonstrated aneurysm at the right M2 portion. We performed surgery to prevent rebleeding during the acute stage. Surgery revealed a discolored protrusion of the arterial wall of the lesion. The lesion was clipped on wrapping with Bemsheet. At one month postoperatively, angiography showed neither aneurysmal formation nor stenosis at the right M2, but after 5 months a subsequent rupture occurred. Angiography demonstrated pseudoaneurysm formation at the same portion of the right M2. The lesion was trapped with anastomosis of the superficial temporal artery (STA) to the MCA. He was discharged following a good recovery.

The rate of subsequent rupture in ruptured dissecting aneurysm in the MCA is 14.3% in published papers. Acute surgery must be performed to prevent the risk of re-rupture. In our single case report, trapping was effective treatment.

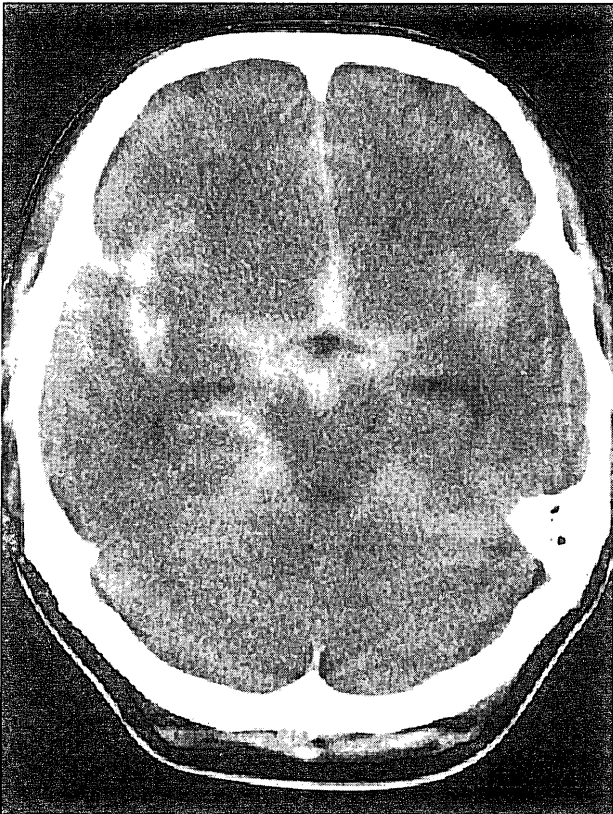
**Key words:** *Middle cerebral artery, Ruptured dissecting aneurysm, Subarachnoid hemorrhage, Subsequent rupture, Treatment*

Dissecting aneurysms have been recognized to be the cause of ischemic or hemorrhagic stroke. The reported number of dissecting aneurysms in the anterior circulation is small compared to the number in the posterior circulation<sup>23-25</sup>. To date, there have been only 31 reported cases of spontaneous dissecting aneurysms of the middle cerebral artery (MCA)<sup>1-14,16-22,25-27</sup>. Whether trapping, wrapping, or flow reversal proximal to a bypass procedure is the optimal management for these cases is uncertain.

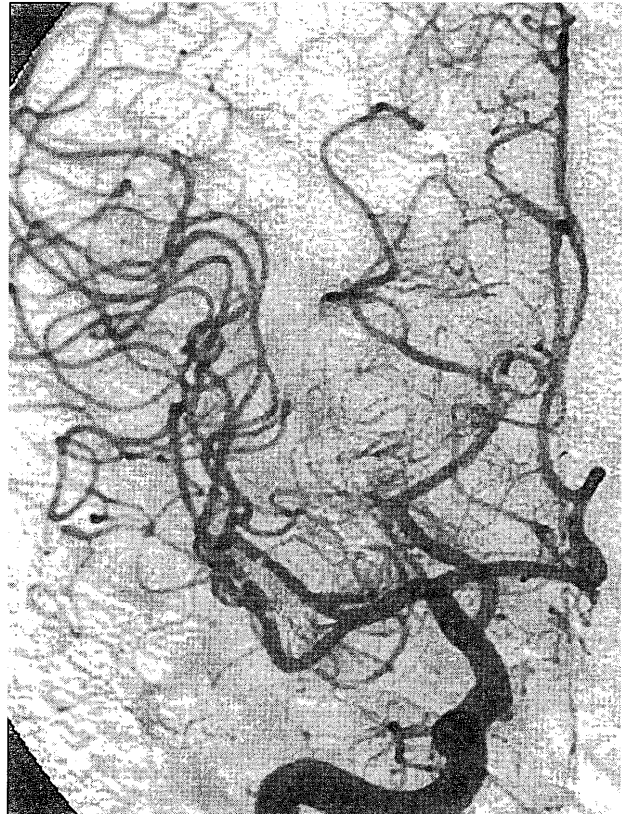
We report a case of recurrent subarachnoid hemorrhage from ruptured dissecting aneurysms of the M2 portion of the MCA secondary to treatment through trapping of the aneurysm and anastomosis of the superficial temporal artery (STA) to the MCA. A review of the literature is made on dissecting aneurysms of the MCA, especially ruptured dissecting aneurysms of the MCA.

### CASE REPORT

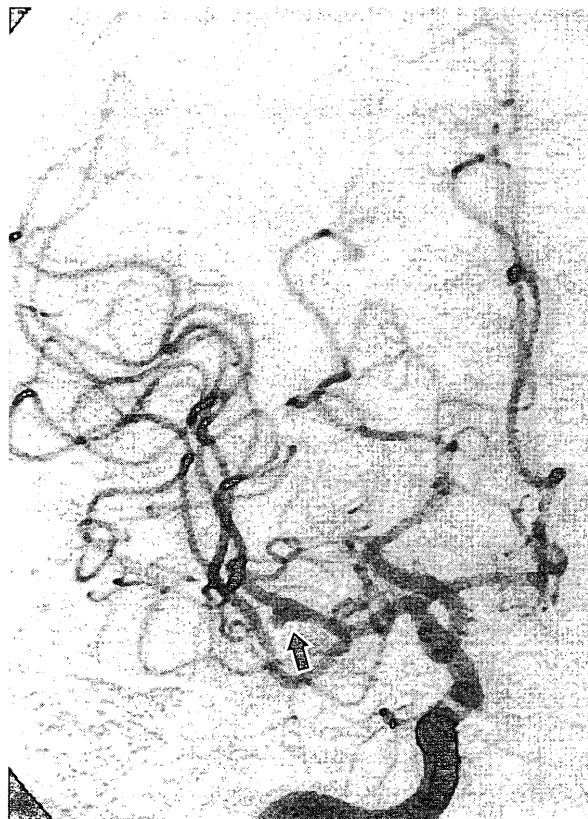A 41-year-old man with a sudden onset of headache and vomiting was referred to our hospital on November 18, 1999. A computed tomographic (CT) scan on day 0 revealed a subarachnoid hemorrhage (Fig. 1). The Hunt & Hess grade was II. Angiography performed on day 0 showed an aneurysm at the M2 portion unrelated to the branching zones of the right MCA (Fig. 2). After ruling out infectious disease, we conducted surgery to prevent re-bleeding from the spontaneous aneurysm on day 0. During the operation, we diagnosed that the aneurysm was a ruptured dissecting aneurysm due to the following reason. The wall of the aneurysm was thin and had a discolored protrusion, and the parent artery of the proximal and distal branch of the aneurysm was normal. The lesion was clipped on wrapping with Bemsheet in order to avoid possible perforator



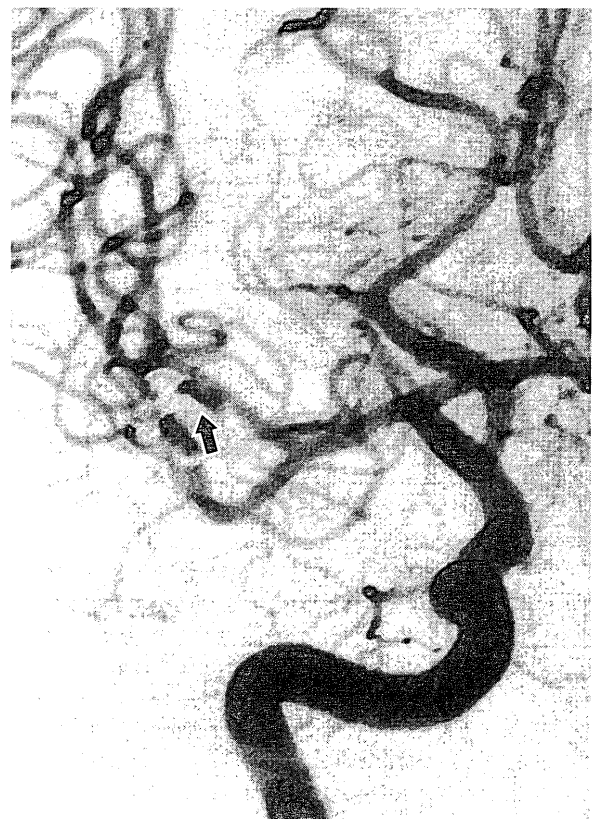
**Fig. 1.** Axial CT scan on admission revealed subarachnoid hemorrhage.



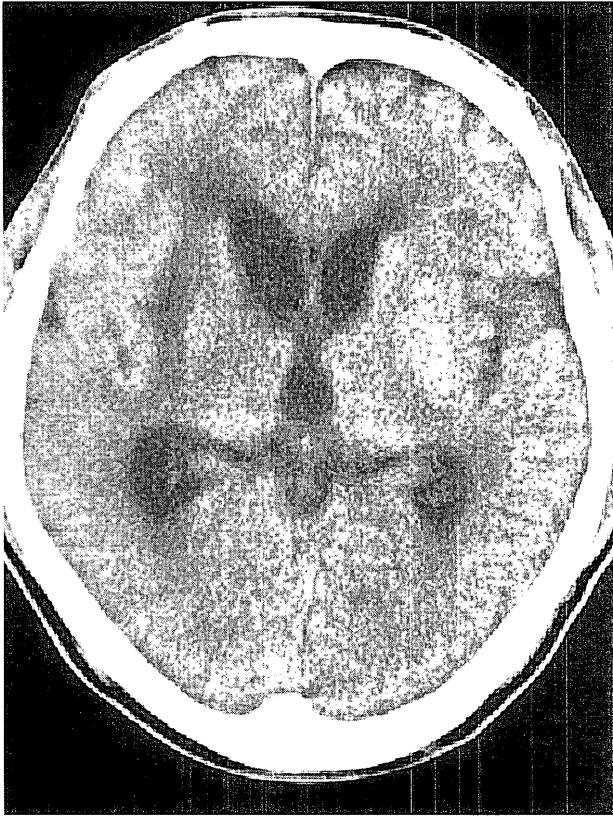
**Fig. 3.** Postoperative angiography demonstrated disappearance of aneurysm.



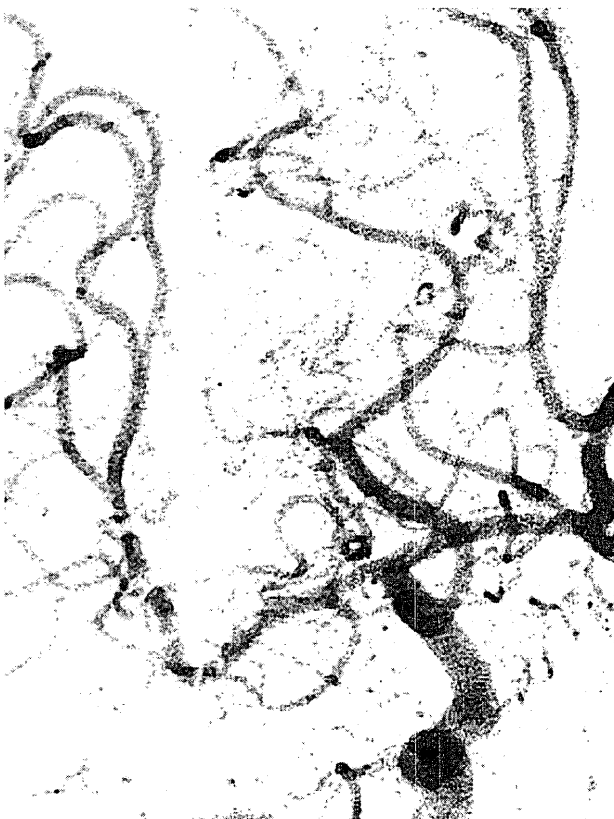
**Fig. 2.** Right carotid angiogram on admission. Arterial phase, AP view. Aneurysm at the M2 portion unrelated to the branching zones of the right MCA is shown (arrow).



**Fig. 4.** Right carotid angiogram on re-admission. Arterial phase, AP view. Angiography showed pseudoaneurysm formation at the M2 portion (arrow).



**Fig. 5.** CT scan revealed lacunar infarction.



**Fig. 6.** Postoperative angiography demonstrated disappearance of aneurysm.

injury. Postoperative angiography demonstrated the disappearance of the aneurysm (Fig. 3). The

patient was discharged without neurological deficit on December 22, 1999. However, on April 6, 2000, he again suffered a sudden onset of headache. A CT scan revealed a subarachnoid hemorrhage limited to the right sylvian fissure. The Hunt & Hess grade was III. Angiography showed a pseudoaneurysm formation at the same clipped portion of the M2 (Fig. 4). To prevent risk of rebleeding under the diagnosis of re-ruptured dissecting aneurysm, he was surgically treated. The lesion was trapped and flow to the distal MCA was preserved with anastomosis of the STA to the MCA. The patient awoke from surgery with left hemiparesis due to a small infarction of the perforating area on CT scan (Fig. 5). Postoperative angiography demonstrated the disappearance of the aneurysm (Fig. 6). He gradually recovered after rehabilitation. He was discharged after a favorable recovery on June 6, 2000.

### DISCUSSION

The reported number of dissecting aneurysms in the anterior circulation is small compared to the number in the posterior circulation. To our knowledge, there have been 31 reported cases of spontaneous dissecting aneurysms of the MCA<sup>1-14,16-22,25-27</sup>. On the other hand, dissecting aneurysms in the anterior circulation have been recognized as the cause of ischemic stroke. However, spontaneous dissecting aneurysms of the MCA tend to be caused by hemorrhagic stroke, because 17 including our present case occurred with hemorrhage<sup>1,2,5,6,9,12,14,16,18,19,21,25,26</sup>, 10 with infarction<sup>1,3,4,7,9,11,13,22,27</sup>, two with both hemorrhage and infarction<sup>10,17</sup>, and two with incidental<sup>8,20</sup>. Proximal dissecting aneurysms of the MCA might cause ischemic stroke and distal dissecting aneurysms of the MCA might cause hemorrhagic stroke<sup>1-14,16-19,21,22,25-27</sup>.

Treatment of ruptured dissecting aneurysms of the MCA has not been established because of the small number of dissecting aneurysms of the MCA and lack of knowledge of the natural history. However, surgical treatment is necessary because of the possibility of subsequent rupture or changes in the dissecting aneurysms in ruptured dissecting aneurysms of the MCA. Surgical treatment was performed in 17 (81.0%) of the 21 cases of ruptured dissecting aneurysms of the MCA (Table 1)<sup>1,2,5,6,8-11,13,14,16-19,21,25,26</sup>. Surgical treatment of the M1 portion was performed in 4 of the 5 cases by 1 wrapping, 2 clipping and 1 proximal occlusion with STA-MCA anastomosis<sup>5,9,14,17</sup>. That of the M1-M2 portion was performed in 2 of the 5 cases by 1 clipping and 1 coating<sup>1,15</sup>. That of the M2 portion was performed in 6 of the 6 cases by 2 trapping, 2 trappings with STA-MCA anastomosis, 1 wrapping with STA-MCA anastomosis and 1 ligation with STA-MCA anastomosis<sup>2,9,10,16</sup>. That of the M3 portion was performed in 5 of the 5 cases

**Table 1.** Ruptured Dissecting Aneurysm of the Middle Cerebral Artery

Authors (Year)	Age, Sex	Location	Re-stroke	Treatment
Kunze, et al, (1971) <sup>12)</sup>	34, M	proximal (M1)	none	conservative
Kamiyama, et al, (1990) <sup>9)</sup>	45, F	proximal (M1)	none	clipping
Mizutani, (1998) <sup>14)</sup>	41, F	proximal (M1)	none	wrapping
Hashimoto, et al, (1999) <sup>5)</sup>	56, F	proximal (M1)	none	proximal occlusion with STA-MCA
Niikawa, et al, (2002) <sup>17)</sup>	46, F	proximal (M1)	none	clipping and wrapping
Ramsey, et al, (1948) <sup>21)</sup>	47, M	proximal (M1~2)	none	conservative
Mizutani, (1998) <sup>14)</sup>	67, F	proximal (M1~2)	rupture	conservative
Abiko, et al, (1999) <sup>1)</sup>	59, F	proximal (M1~2)	none	clipping and wrapping
Nimura, et al, (2000) <sup>18)</sup>	61, F	proximal (M1~2)	none	coating
Ono, et al, (2001) <sup>19)</sup>	68, F	proximal (M1~2)	none	conservative
Kamiyama, et al, (1990) <sup>9)</sup>	27, F	distal (M2)	none	trapping with STA-MCA anastomosis
Kawaguchi, et al, (1997) <sup>10)</sup>	48, M	distal (M2)	none	wrapping with STA-MCA anastomosis
Anzai, et al, (1999) <sup>2)</sup>	26, M	distal (M2)	none	ligation with STA-MCA anastomosis
Anzai, et al, (1999) <sup>2)</sup>	24, M	distal (M2)	none	trapping
Nakashima, et al, (2002) <sup>16)</sup>	29, M	distal (M2)	none	trapping
Sasaki, et al, (1991) <sup>26)</sup>	41, F	distal (M3)	rupture	resection with STA-MCA anastomosis
Hashimoto, et al, (1995) <sup>6)</sup>	44, M	distal (M3)	none	resection
Anzai, et al, (1999) <sup>2)</sup>	52, F	distal (M3)	none	resection
Isono, et al, (2002) <sup>8)</sup>	30, M	distal (M3)	none	resection
Sakamoto, et al, (inpress)	65, F	distal (M3)	none	resection with STA-MCA anastomosis
present case	41, M	distal (M2)	rupture	trapping with STA-MCA anastomosis

\* STA-MCA = superficial temporal artery-middle cerebral artery

by 3 resections with and 2 resections without STA-MCA<sup>2,6,25,26)</sup>. Proximal ruptured dissecting aneurysms of the MCA tended to be coated rather than clipped because of the existence of a perforating artery. The distal ruptured dissecting aneurysms of the MCA tended to be trapped or resected. However, there has been no report of subsequent rupture after surgical treatment for a ruptured distal dissecting aneurysm of the MCA.

When we encounter a subarachnoid hemorrhage with aneurysm or aneurysmal dilatation demonstrated on angiogram, the lesion might be a ruptured dissecting aneurysm. There is a possibility that ruptured dissecting aneurysms may cause subsequent rupture. We consider that acute surgery must be performed immediately after detection of the aneurysm to prevent the risk of a second stroke. Subsequent stroke of dissecting aneurysms of the MCA occurred in 5 (15.6%) of the 32 cases, including our present case, with 3 cases caused by hemorrhagic stroke<sup>14,26)</sup> and 2 caused by ischemic stroke<sup>4,11)</sup>. In ruptured dissecting aneurysms of the MCA, subsequent rupture occurred in 3 (14.3%) of the 21 cases<sup>14,26)</sup>. In our case, subsequent rupture occurred at 5 months after treatment with clip on wrapping. On the other hand, in two cases of ruptured dissecting aneurysms, preoperative repeat angiograms demonstrated enlargement of the aneurysm for short periods, although subsequent rupture did not occur<sup>6,17)</sup>. In our case, we performed clipping on wrapping with Bemsheet to prevent perforator occlusion for the ruptured dissecting aneurysm of the M2 portion. Postoperative angiography demonstrated the disappearance of the aneurysm

and patency of the parent artery. However, subsequent regrowth and rupture was caused at a short period after treatment by this method. The dissecting wall of the vessel was weak because of acute widespread disruption of the internal elastic lamina<sup>15)</sup>. In ruptured dissecting aneurysms of the M2 or M3 portion, trapping is likely to be a more useful method than coating or wrapping, if necessary, in preserving the circulation distal to the aneurysm.

(Received December 20, 2002)

(Accepted February 10, 2003)

## REFERENCES

1. **Abiko, S., Okamura, T., Kurokawa, Y., Ikeda, N., Ideguchi, M. and Watanabe, K.** 1999. Diagnosis and treatment of nontraumatic dissecting aneurysm in the middle cerebral artery. *No Shinkei Geka* **27**: 743-749. (Jpn, with Eng abstract)
2. **Anzai, K., Sasaki, T., Nakagawara, J., Hayase, K. and Nakamura, H.** 1999. Three dissecting aneurysms of the middle cerebral artery with subarachnoid hemorrhage. *Surgery for Cerebral Stroke* **27**: 198-202. (Jpn, with Eng abstract)
3. **Fu, Y., Komiyama, M., Inoue, T., Ohata, K., Matsuoka, Y. and Hakuba, A.** 1996. A case of middle cerebral artery occlusion caused by dissecting aneurysm. *No Shinkei Geka* **24**: 955-959. (Jpn, with Eng abstract)
4. **Grosman, H., Fornasier, V.L., Bonder, D., Livingston, K.E. and Platts, M.E.** 1980. Dissecting aneurysm of the cerebral arteries. *J. Neurosurg.* **53**: 693-697.
5. **Hashimoto, H., Iida, J., Shin, Y., Hironaka, Y. and Sakaki, T.** 1999. Subarachnoid hemorrhage

- from intracranial dissecting aneurysms of the anterior circulation: Two case reports. *Neurol. Med. Chir. (Tokyo)*. **39**: 442–446.
6. **Hashimoto, N., Suzuki, O., Takakubo, Y., Mori, I. and Nagai, H.** 1995. A dissecting aneurysm of the middle cerebral artery: A case report. *No Shinkei Geka Journal* **4**: 281–286. (Jpn, with Eng abstract)
  7. **Hochberg, F.H., Bean, C., Fisher, C.M. and Robertson, G.H.** 1975. Stroke in a 15-year-old girl secondary to terminal carotid dissection. *Neurology* **25**: 725–729.
  8. **Isono, M., Abe, T., Goda, M., Ishii, K. and Kobayashi, H.** 2002. Middle cerebral artery dissecting aneurysm causing intracerebral hemorrhage 4 years after the non-hemorrhagic onset: a case report. *Surg. Neurol.* **57**: 346–349.
  9. **Kamiyama, H., Nomura, M., Abe, H., Abumiya, T., Saito, H., Yamauchi, T., Mitsumori, K., Yoshimoto, T., Takigawa, S., Ito, T., Houkin, K., Isu, T., Kawamoto, S., Ishikawa, T. and Yasui, N.** 1990. Diagnosis for the intracranial dissecting aneurysms. *Surgery for Cerebral Stroke* **18**: 50–56. (Jpn, with Eng abstract)
  10. **Kawaguchi, T., Kawano, T., Kazekawa, K., Honma, T., Kaneko, Y., Koizumi, T. and Dousaka, Y.** 1999. Dissecting aneurysm of the middle cerebral artery with subarachnoid hemorrhage and brain infarction. *No Shinkei Geka* **25**: 1033–1037. (Jpn, with Eng abstract)
  11. **Kitani, R., Itouji, T., Noda, Y., Kimura, M. and Uchida, S.** 1987. Dissecting aneurysms of the anterior circle of Willis arteries. *J. Neurosurg.* **67**: 296–300.
  12. **Kunze, S. and Schiefer, W.** 1971. Angiographic demonstration of a dissecting aneurysm of the middle cerebral artery. *Neuroradiology* **2**: 201–206.
  13. **Mizutani, T.** 1996. Middle cerebral artery dissecting aneurysm with persistent patent pseudolumen. *J. Neurosurg.* **84**: 267–268.
  14. **Mizutani, T.** 1998. Subarachnoid hemorrhage associated with angiographic stenotic or occlusive lesions in the carotid circulation. *Surg. Neurol.* **49**: 495–504.
  15. **Mizutani, T., Miki, Y., Kojima, H. and Suzuki, H.** 1999. Proposed classification of nonatherosclerotic cerebral fusiform and dissecting aneurysm. *Neurosurgery* **45**: 253–260.
  16. **Nakashima, S., Nomura, S., Tomokiyo, M., Furukawa, Y., Shimokawa, S., Nakagawa, S., Anegawa, S. and Hayashi, T.** 2002. Dissecting aneurysm of the middle cerebral artery with subarachnoid hemorrhage showing complete occlusion at the M2 portion of the middle cerebral artery on preoperative angiograms: case report. *No Shinkei Geka* **30**: 541–545.
  17. **Niikawa, S., Yamada, J., Sumi, Y. and Yamakawa, H.** 2002. Dissecting aneurysm of the middle cerebral artery manifesting as subarachnoid hemorrhage and hemorrhagic infarctions—case report. *Neurol. Med. Chir. (Tokyo)*. **42**: 62–66.
  18. **Nimura, T., Oku, T., Narita, N. and Higuchi, H.** 2000. Dissecting aneurysm of the middle cerebral artery: case report. *No Shinkei Geka* **28**: 61–65. (Jpn, with Eng abstract)
  19. **Ono, Y., Kawamura, T., Ito, J. and Kanayama, S.** 2001. Dissecting aneurysm of the middle cerebral artery (M1–2 portion) with subarachnoid hemorrhage: a case report. *No Shinkei Geka* **29**: 347–352. (Jpn, with Eng abstract)
  20. **Piepgras, D.G., McGrail, K.M. and Tazelaar, H.D.** 1994. Intracranial dissection of the distal middle cerebral artery as an uncommon cause of distal cerebral artery aneurysm. *J. Neurosurg.* **80**: 909–913.
  21. **Ramsey, T. and Mosquera, V.** 1948. Dissecting aneurysm of the middle cerebral artery. *Ohio Med. J.* **44**: 168–170.
  22. **Robert, F., Maltais, R. and Giroux, J.C.** 1964. Dissecting aneurysm of middle cerebral artery. *J. Neurosurg.* **21**: 413–415.
  23. **Sakamoto, S., Inagawa, T., Ikawa, F., Kawamoto, H., Ohbayashi, N., Sakoda, E. and Hidaka, T.** 2001. Dissecting aneurysm of the anterior cerebral artery with persistent pearl & string sign on cerebral angiograms over a period of eight years. *No Shinkei Geka* **29**: 1093–1098. (Jpn, with Eng abstract)
  24. **Sakamoto, S., Inagawa, T., Ikawa, F., Kawamoto, H. and Ohbayashi, N.** 2002. Anterior cerebral artery dissections manifesting as cerebral hemorrhage and infarction, and presenting as dynamic angiographical changes—case report. *Neurol. Med. Chir. (Tokyo)*. **42**: 250–254.
  25. **Sakamoto, S., Ikawa, F., Kawamoto, H., Ohbayashi, N. and Inagawa, T.** (in press). Acute surgery for ruptured dissecting aneurysm of the M3 portion of the middle cerebral artery: case report. *Neurol. Med. Chir. (Tokyo)*.
  26. **Sasaki, O., Koike, T., Tanaka, R. and Ogawa, H.** 1991. Subarachnoid hemorrhage from a dissecting aneurysm of the middle cerebral artery. *J. Neurosurg.* **74**: 504–507.
  27. **Sato, O., Bascom, J.F. and Logothetis, J.** 1971. Intracranial dissecting aneurysm. *J. Neurosurg.* **35**: 483–487.