



Retinal detachment with retinal pigment epithelial tear under hypotony after trabeculectomy: A case report

Yosuke Harada^{*}, Hideaki Okumichi, Mayuko Miyata, Tomona Hiyama, Yoshiaki Kiuchi

Department of Ophthalmology and Visual Science, Graduate School of Biomedical Sciences, Hiroshima University, 1-2-3 Kasumi, Minami-ku, Hiroshima City, Hiroshima, 734-8551, Japan

ARTICLE INFO

Keywords:

Retinal detachment
Retinal pigment epithelial tear
Hypotony
Glaucoma filtering surgery

ABSTRACT

Purpose: To report a case of retinal detachment with retinal pigment epithelium (RPE) tear, under hypotony after trabeculectomy, which immediately resolved upon elevation of intraocular pressure.

Observations: A 67-year-old man who had undergone trabeculectomy presented for treatment of a visual field defect in his left eye. His glaucoma surgery was uneventful. At his first visit to our clinic, the patient's visual acuity was 15/20 in the right eye and 20/40 in the left; intraocular pressure was 18 mmHg in the right and 5 mmHg in the left. Fundus examination of the left eye revealed a retinal detachment, overlying a choroidal detachment, and an RPE tear. The retinal detachment did not resolve with systemic steroid pulse therapy or vitrectomy. The patient was then diagnosed with an exudative retinal detachment with RPE tear under hypotony, and transconjunctival sutures were applied to tighten the scleral flap, to elevate intraocular pressure. After the transconjunctival sutures were applied, intraocular pressure increased to 10 mmHg and the exudative retinal detachment immediately resolved. There was no recurrence of retinal detachment after the intervention.

Conclusions and importance: Because there have been few case reports of retinal detachment with an RPE tear after glaucoma filtering surgery, no therapeutic strategy has yet been proposed. The findings in this case indicate that intraocular pressure elevation is effective for treating exudative retinal detachment with RPE tear in cases of hypotony after glaucoma filtering surgery.

1. Introduction

Retinal detachment with a retinal pigment epithelium (RPE) tear was first described in 1981.¹ Various etiologies cause RPE tears.² The most common cause is vascularized RPE detachment in patients with exudative age-related macular degeneration.¹ Other etiologies include central serous chorioretinopathy,³ angioid streak,⁴ high myopia,⁵ uveitis,⁶ proliferative vitreoretinopathy,⁷ and complications of scleral buckling⁸ or glaucoma surgery.^{9–11} RPE tears as a complication of glaucoma filtering surgery (trabeculectomy) are rare and lack an established method of treatment. We report a case of retinal detachment with RPE tear, in the context of decreased intraocular pressure (IOP) (hypotony) after a trabeculectomy. The detachment was immediately resolved through elevation of IOP.

2. Case report

A 67-year-old man presented to our clinic complaining of a visual

field defect in his left eye; he had undergone trabeculectomy in the left eye 2 months prior. He was diagnosed with uveitis-associated glaucoma in the left eye during the preoperative examination. The glaucoma surgery was uneventful. At his first visit to our clinic, the patient's corrected decimal visual acuity was 15/20 in the right eye and 20/40 in the left, and his IOP was 18 mmHg in the right eye and 5 mmHg in the left. He had a diffuse, large filtering bleb and 1+ anterior chamber cells in the left eye. Dilated fundus examination of his left eye revealed a retinal detachment, overlying a choroidal detachment, easily shifted with alternation of head position, indicating exudative retinal detachment, and an RPE tear (Fig. 1). There were no abnormal findings in his right eye. The differential diagnosis at this point included: uveal effusion; inflammatory etiology, such as posterior scleritis or atypical Vogt-Koyanagi-Harada disease; and ocular metastasis of malignancy. Fluorescein angiography showed a window defect corresponding to the RPE tear, but no leakage or blockage (Fig. 1). Indocyanine green angiography did not show leakage or blockage. B-mode ultrasonography showed normal scleral thickness in both eyes. Axial length was 24.66 in the right eye and

^{*} Corresponding author.

E-mail address: yharada@hiroshima-u.com (Y. Harada).

<https://doi.org/10.1016/j.ajoc.2020.100853>

Received 25 January 2020; Received in revised form 23 July 2020; Accepted 30 July 2020

Available online 5 August 2020

2451-9936/© 2020 The Authors.

Published by Elsevier Inc.

This is an open access article under the CC BY-NC-ND license

(<http://creativecommons.org/licenses/by-nc-nd/4.0/>).

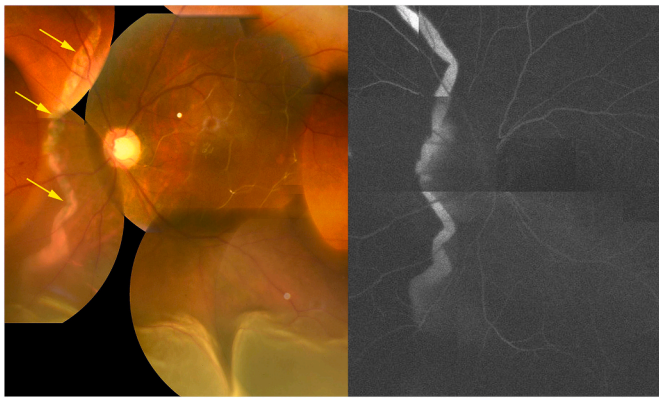


Fig. 1. Fundus photograph and fluorescein angiography image of the patient's left eye at initial presentation. The fundus photograph shows exudative retinal detachment inferiorly. A retinal pigment epithelium (RPE) tear (arrows), running vertically nasal to the optic nerve, is visible. Fluorescein angiography shows a window defect consistent with an RPE tear.

24.72 in the left eye. Full-body computed tomography and positron emission tomography did not reveal any evidence of malignancy. Lumbar puncture did not show pleocytosis. Inflammatory disease was first suspected, owing to the presence of the exudative retinal detachment and anterior chamber cells. The patient was first treated with intravenous methylprednisolone pulse therapy (1 g/day for 3 days). However, his retinal detachment worsened and the RPE tear grew wider (Fig. 2). Optical coherence tomography (OCT) showed subretinal fluid, and an RPE tear with the edge of the tear rolled peripherally (Fig. 2). The patient underwent a vitrectomy 20 days after his initial presentation at the clinic. There was no obvious retinal tear or hole. Subretinal fluid was drained through an iatrogenic retinal hole, and sulfur hexafluoride (SF_6) gas was used to fill the vitreous space. IOP increased to 10 mmHg after the vitrectomy, but gradually decreased again. After the vitrectomy, the retina remained attached for 2 weeks. However, retinal detachment recurred when IOP in the left eye had decreased to 5 mmHg. The retinal detachment seemed to occur at times of hypotony, which was thought to be caused by over-filtration after glaucoma surgery. To remedy over-filtration, transconjunctival sutures were then applied to the patient's

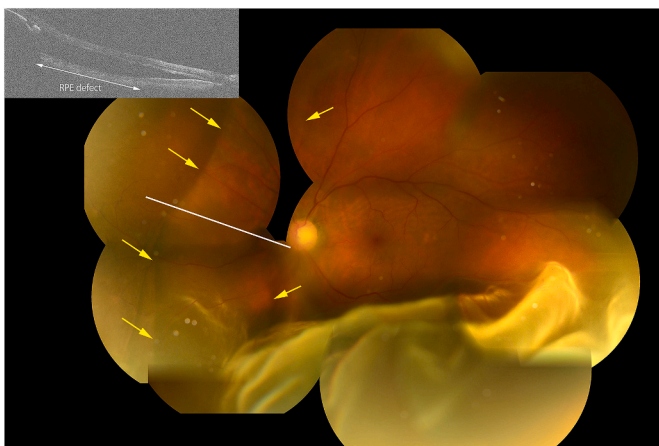


Fig. 2. Fundus photograph of the patient's left eye, taken 1 day before vitrectomy, showing a bullous macula-off retinal detachment overlying a nasal choroidal detachment with retinal pigment epithelium (RPE) tear. At the patient's first visit, the RPE tear was visible as a narrow vertical line, which grew wider (arrows). Scrolling of the RPE was visible at the edge of the tear. Optical coherence tomography (OCT) showed RPE scrolling at the edge of the tear and an RPE defect with subretinal fluid. At the periphery, the choroidal structure was masked by the back-shadowing of the RPE detachment. The line in the fundus photograph indicates the scan line for the OCT image.

left eye to tighten the scleral flap. Four hours later, both the retinal and choroidal detachments had improved with an elevation of IOP (12 mmHg). The next day, IOP was 13 mmHg, and the detachments were completely resolved (Fig. 3). The retinal detachment had not recurred for 14 months with IOP higher than 10 mmHg.

3. Discussion

RPE tears outside the macula, as in this case, are very rare.²⁻¹⁸ In particular, there have been only a few reports of RPE tears after glaucoma filtering surgery,²⁻⁴ the pathophysiology has not been clearly described and the appropriate treatment has not been established. In this report, we showed that hypotony is central to the development of this condition and that elevating IOP is essential for the treatment.

Laatikainen and Syrdalen reported two cases of RPE tears after trabeculectomy; one of those cases involved concomitant retinal detachment.⁹ Laidlaw and Poynter also reported transient exudative retinal detachment caused by a giant RPE tear after a trabeculectomy.¹⁰ McCann and Engelbert reported a case of bullous retinal detachment with a large RPE tear and choroidal detachment in a patient with a history of trabeculectomy.¹¹ What is common to these previous reports and our case is that retinal detachment with an RPE tear developed under hypotony. Whereas retinal detachment was resolved by pars plana vitrectomy and choroidal drainage in the case of McCann and Engelbert, in the other two previous reports it resolved spontaneously with increased IOP.^{9,10} Those reports, together with our case, suggest that IOP is important in the development and resolution of retinal detachment with RPE tear after filtering surgery. Choroidal detachment under hypotony is frequently experienced after filtering surgery. However, an RPE tear after surgery rarely occurs. Although choroidal detachment causes mechanical stretching of the RPE, it is not likely that an RPE tear developed simply due to choroidal detachment secondary to hypotony.¹⁰ It also seems to depend upon RPE vulnerability. One of Laatikainen and Syrdalen's cases underwent cyclocryotherapy, McCann and Engelbert's case had a history of blebitis, and our case had a history of uveitis. All of these involved ocular inflammation, possibly leading to RPE vulnerability.^{10,11}

The question arises how exudative retinal detachment develops and resolves. Laidlaw and Poynter postulated that transient exudative retinal detachment results from a loss of the barrier function of the RPE, and the resolution of it is due to either atrophy of the choriocapillaris, or healing

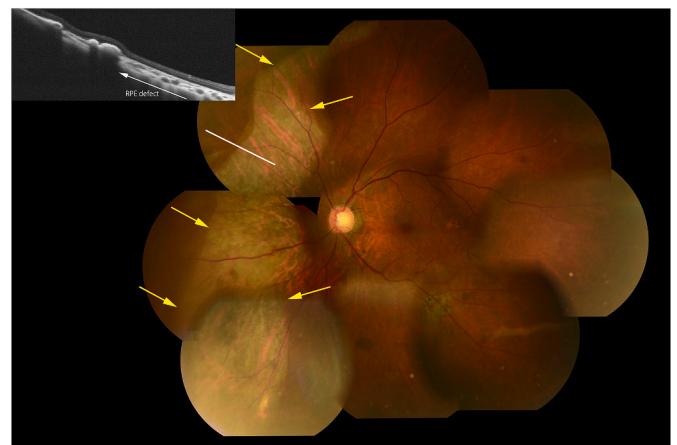


Fig. 3. Fundus photograph of the patient's left eye, 16 hours after the use of transconjunctival sutures to tighten the scleral flap. The retinal detachment and choroidal detachment had completely resolved. The choroidal vessel was clearly visible at the widened retinal pigment epithelium (RPE) tear (arrows), nasal to the optic disc. The optical coherence tomography image (corresponding to the line in the fundus photograph) reveals resolution of the retinal detachment. The scrolled RPE is seen at the edge of RPE tear.

of the defect by a layer of depigmented pigment epithelial cells, or fibrous tissue.¹⁰ This hypothesis seems plausible, especially as a mechanism for the development of exudative retinal detachment. The clinical course and OCT image of our case suggest that the subretinal fluid comes from the suprachoroidal space, through an RPE tear after it loses barrier function. Conversely, the proposed mechanism for the resolution of subretinal fluid does not seem to apply in our case because IOP elevation, by application of transconjunctival sutures to tighten the scleral flap, to remedy the over-filtration, resulted in fast resolution of the retinal detachment. Combined with the postulated mechanism by Laidlaw and Poynter and the clinical course of this case, we hypothesize that the mechanism is as follows. Hypotony after the trabeculectomy caused the RPE tear, following choroidal detachment in the eye with an RPE that was vulnerable to mechanical stretch. Fluid that accumulated in the suprachoroidal space then gradually moved to the subretinal space through the RPE tear, leading to an exudative retinal detachment. The IOP elevation to correct the choroidal detachment was the crucial factor for the resolution of the exudative retinal detachment. Accumulation of similar cases is needed for this hypothesis to be validated.

4. Conclusion

Choroidal detachment secondary to hypotony may cause an RPE tear when an eye with a vulnerable RPE undergoes glaucoma filtering surgery. Fluid in the suprachoroidal space moves to the subretinal space through the RPE tear, resulting in an exudative retinal detachment. If over-filtration after glaucoma surgery is the cause of hypotony, then intervention for elevation of the IOP may resolve the retinal detachment.

Patient consent

Informed consent was obtained from the patient for the purpose of publication.

Conflict of interest disclosure

All authors have completed and submitted the ICMJE Form for Disclosure of Potential Conflicts of Interest; no conflicts were reported.

Funding/financial

The authors have received no funding or grant support related to this article.

Intellectual property

We confirm that we have given due consideration to the protection of intellectual property associated with this work and that there are no impediments to publication, including the timing of publication, with respect to intellectual property. In so doing we confirm that we have followed the regulations of our institutions concerning intellectual property.

Research ethics

We further confirm that any aspect of the work covered in this manuscript that has involved human patients has been conducted with the ethical approval of all relevant bodies and that such approvals are acknowledged within the manuscript.

Declaration of competing interest

The authors declare that they have no known competing financial interests or personal relationships that could have appeared to influence the work reported in this paper.

Acknowledgments

We thank the patient for granting permission to publish this information. We also thank Ryan Chastain-Gross, Ph.D. and Claire Barnes, Ph.D. from Edanz Group (<https://en-author-services.edanzgroup.com/ac>) for editing drafts of this manuscript.

References

- Hoskin A, Bird AC, Sehmi K. Tears of detached retinal pigment epithelium. *Br J Ophthalmol*. 1981;65(6):417–422.
- Eroz MG, Karacorulu M, Arf S, et al. Retinal pigment epithelium tears: classification, pathogenesis, predictors, and management. *Surv Ophthalmol*. 2017;62(4):493–505.
- Ishida Y, Kato T, Minamoto A, et al. Retinal pigment epithelial tear in a patient with central serous chorioretinopathy treated with corticosteroids. *Retina*. 2004;24(4):633–636.
- Lim JI, Lam S. A retinal pigment epithelium tear in a patient with angioid streaks. *Arch Ophthalmol*. 1990;108(12):1672–1674.
- Fryczkowski P, Jedruch A, Kmera-Musqynska M. Spontaneous RPE tear in high myopia. *Klin Oczna*. 2006;108(7-9):302–306.
- Arroyo JG, Jaffe GJ. Spontaneous giant retinal pigment epithelial tear associated with panuveitis. *Retina*. 1997;17(6):992–995.
- Joyiga A, Newsom RSB. Giant retinal pigment epithelium rip secondary to subretinal proliferative vitreoretinopathy. *Eye*. 2004;18(9):960–962.
- Tsuda K, Yamamoto S, Sugahara M, et al. Giant pigment epithelial tear after scleral buckling for rhegmatogenous retinal detachment. *Retin Cases Brief Rep*. 2008;2(2):115–116.
- Laatikainen L, Syrdalen P. Tearing of retinal pigment epithelium after glaucoma surgery. *Graefes Arch Exp Ophthalmol*. 1987;225(4):308–310.
- Laidlaw DA, Poynter R. Giant retinal pigment epithelial tear and exudative retinal detachment complicating choroidal effusions. *Am J Ophthalmol*. 1998;126(3):448–450.
- McCann JT, Engelbert M. Large retinal pigment epithelial rip associated with bullous retinal and choroidal detachment. *Retin Cases Brief Rep*. 2017;11(4):361–363.
- Swanson DE, Kalina RE, Guzak SV. Tears of the retinal pigment epithelium. Occurrence in retinal detachment and a choroidal scar. *Retina*. 1984;4(2):115–118.
- Gass JD. Retinal pigment epithelial rip during krypton red laser photocoagulation. *Am J Ophthalmol*. 1984;98(6):700–706.
- Serels SR, Liebmann JM, Ritch R, et al. Tears of the retinal pigment epithelium: occurrence in association with choroidal effusion. *Ophthalmic Surg*. 1991;22(3):142–144.
- Arroyo JG, Jaffe GJ. Spontaneous giant retinal pigment epithelial tear associated with panuveitis. *Retina*. 1997;17(3):254–256.
- Levin LA, Seddon JM, Topping T. Retinal pigment epithelial tears associated with trauma. *Am J Ophthalmol*. 1991;112(4):396–400.
- Leys AM, Shields JA. Tumor-associated retinal pigment epithelial tears. *Retina*. 1997;17(3):258–260.
- Matsubara N, Kato A, Kominami A, et al. Bilateral giant retinal pigment epithelial tears in hypertensive choroidopathy. *Am J Ophthalmol Case Rep*. 2019;15:100525. <https://doi.org/10.1016/j.ajoc.2019.100525>.