

Comparative Evaluation of Angioscopy and Intravascular Ultrasound for Assessing Plaque Protrusion During Carotid Artery Stenting Procedures

Hiroshi Kondo^{1,2}, Yoshihiro Kiura^{1,2}, Shigeyuki Sakamoto², Takahito Okazaki², Fumiyuki Yamasaki², Koji Iida², Atsushi Tominaga^{1,2}, Kaoru Kurisu²

■ **BACKGROUND:** Evaluation of plaque protrusion after carotid artery stenting (CAS) is important for predicting periprocedural ischemic complications. In contrast to intravascular ultrasound (IVUS), angioscopy allows direct visualization of the plaque. The aim of this study was to evaluate utility and safety of angioscopy during CAS and compare it with IVUS.

■ **METHODS:** The study included 13 carotid artery stenosis lesions in 11 consecutive patients (mean age 70.5 years; 10 men) at a single center. During CAS procedure, poststenting plaque protrusion was evaluated with angioscopy and IVUS.

■ **RESULTS:** Mean level of internal carotid artery stenosis was 79.2%. Eight lesions were symptomatic, and 5 lesions were predicted to have vulnerable plaque by preprocedural magnetic resonance imaging. A carotid WALLSTENT was placed in all cases. After stenting, angioscopy provided good visualization in all cases. Plaque protrusions were observed in 1 case by IVUS and in 8 cases by angioscopy. Diffusion-weighted imaging showed positive lesions in 3 cases (23%). For 2 of these lesions, plaque protrusions were observed by angioscopy but not by IVUS. All lesions associated with positive diffusion-weighted imaging findings were observed to have yellow plaque on angioscopy.

■ **CONCLUSIONS:** Angioscopy provided direct visualization of stent lumens after CAS. Angioscopy detected more plaque protrusion than IVUS and allowed clearer observation of plaque characteristics. Angioscopy may be more useful than

IVUS for examination of plaque protrusion and plaque evaluation after CAS, especially for plaque identified as potentially vulnerable by preprocedural examination.

INTRODUCTION

In carotid artery stenting (CAS), plaque assessment is extremely important for identifying patients at risk of ischemic complications, such as patients with protruding, mobile, or vulnerable plaque, who may need additional treatment. A plaque assessment is usually performed before the CAS procedure using carotid artery ultrasound and magnetic resonance imaging (MRI). Intraprocedural evaluations are also important, in which intravascular ultrasound (IVUS)¹⁻³ or optical coherence tomography (OCT) is often used.⁴⁻⁶ However, IVUS and OCT provide only an indirect view of the plaque. In contrast, angioscopy can directly visualize the vascular lumen, showing the color of its surface, small thrombi, plaque protrusion, and morphology. Since the 1980s, endoscopy and then angioscopy have been recognized as useful for identifying arteriosclerosis-related plaque in coronary disease.⁷⁻¹³ However, there have been few reports about the use of angioscopy for investigating carotid artery disease.^{14,15} In this study, we observed vascular and stent lumens on angioscopy during CAS procedures and evaluated the risk of ischemic complication during the periprocedural period, comparing the utility and safety of angioscopy in CAS with that of IVUS.

Key words

- Angioscopy
- Carotid artery stenting
- Plaque protrusion

Abbreviations and Acronyms

CAS: Carotid artery stenting
CEA: Carotid artery endarterectomy
CREST: Carotid Revascularization Endarterectomy versus Stenting Trial
DWI: Diffusion-weighted imaging
ECA: External carotid artery
ICA: Internal carotid artery
IVUS: Intravascular ultrasound
MRI: Magnetic resonance imaging
OCT: Optical coherence tomography

PAES: Parodi antiemboli system

SAPPHIRE: Stenting and Angioplasty with Protection in Patients at High Risk for Endarterectomy

From the ¹Department of Neurosurgery and Neuroendovascular Therapy, Hiroshima Prefectural Hospital; and ²Department of Neurosurgery, Graduate School of Biomedical and Health Sciences, Hiroshima University, Hiroshima, Japan


To whom correspondence should be addressed: Hiroshi Kondo, M.D.
 [E-mail: springhascome0224@gmail.com]

Citation: *World Neurosurg.* (2019).
<https://doi.org/10.1016/j.wneu.2019.01.102>

Journal homepage: www.journals.elsevier.com/world-neurosurgery

Available online: www.sciencedirect.com

1878-8750/\$ - see front matter © 2019 Elsevier Inc. All rights reserved.



MATERIALS AND METHODS

Patients

The study included 13 carotid artery stenosis lesions in 11 consecutive patients (mean age 70.5 years; 10 men) between February and September 2015. The angioscopy system used in this study is recognized by insurance companies in Japan for use in coronary artery disease, but not in carotid artery disease. The ethical review board of our hospital approved its use for this study, and written informed consent was obtained from all patients. The study was conducted in accordance with the principles of the Declaration of Helsinki. The inclusion criteria were as follows: asymptomatic internal carotid artery (ICA) stenosis >80% of the lumen diameter or symptomatic ICA stenosis >50% of the lumen diameter was present; a high risk for endarterectomy existed according to the criteria of the Stenting and Angioplasty with Protection in Patients at High Risk for Endarterectomy (SAPPHIRE) study¹⁶; ICA stenosis suddenly progressed in the follow-up course and the need of CAS was considered.

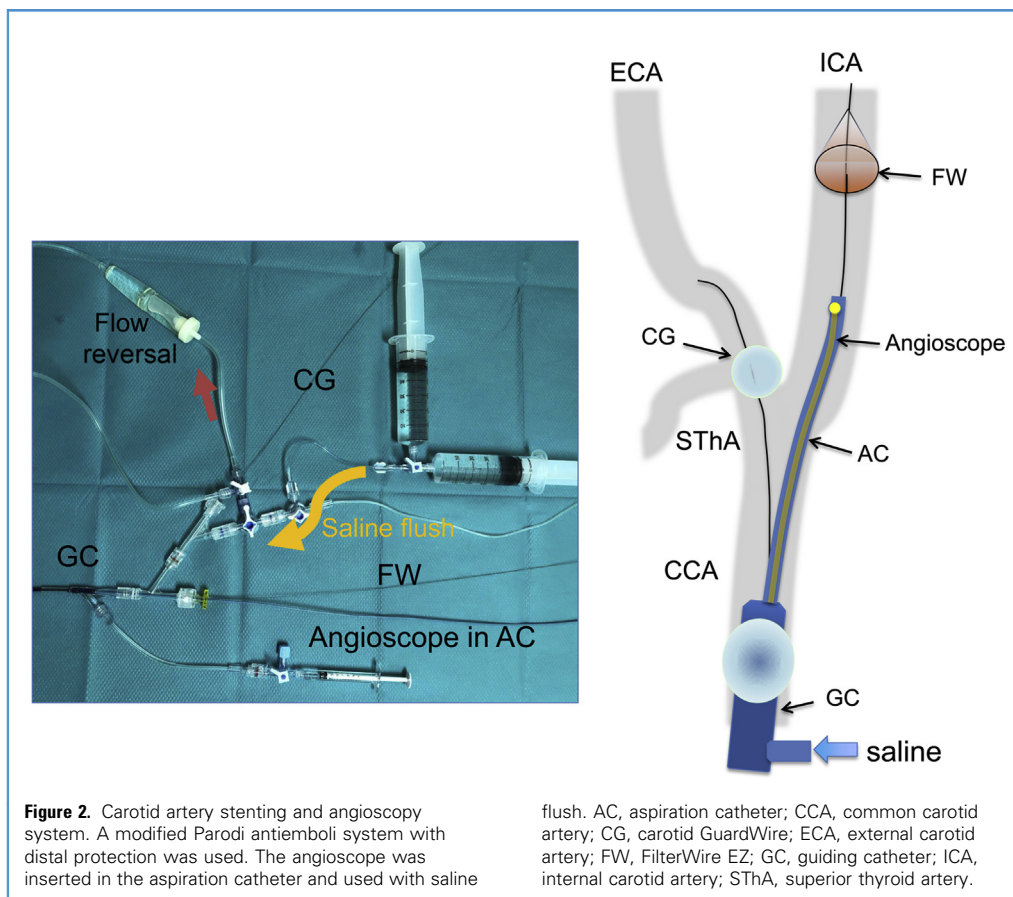
Plaque morphology and character were evaluated before the procedure by black blood imaging and time-of-flight angiography on MRI. Vulnerable plaque was defined as plaque exhibiting high signal on T1-weighted or T2-weighted imaging compared with the intensity of the parotid and maxillary glands or the existence of high signal in the plaque on time-of-flight imaging. During the CAS procedure, IVUS and angioscopy were performed and evaluated before and after stenting. All patients underwent neurologic examinations before and after the CAS procedure, and MRI diffusion-weighted imaging (DWI) was acquired the day after CAS to evaluate ischemic changes. The CAS, IVUS, and

angioscopy procedures were based on procedures reported in a previous study.¹⁴

Carotid Artery Stenting

CAS procedures were performed according to our standard technique with the modified Parodi antiemboli system (PAES) and distal protection of the ICA by FilterWire EZ (Boson Scientific, Marlborough, Massachusetts, USA) to prevent any distal embolic complications under the condition of local anesthesia.¹⁴ For at least 2 weeks before the procedure, patients received dual (1 patient) or triple (10 patients) antiplatelet therapy combining aspirin (100 mg/day) with clopidogrel (75 mg/day) and/or cilostazol (200 mg/day). Ten patients were also taking statins.

The procedure was as follows. After placing a 9-F long sheath introducer in the femoral artery and a 4-F short sheath in the femoral vein at the opposite side as a flow reversal system, the patient was systemically heparinized with a heparin bolus, followed by continued intravenous heparin throughout the CAS procedure to maintain an activated clotting time >275seconds. A 9-F guiding catheter with an occlusion balloon (OPTIMO; Tokai Medical Products, Inc., Aichi, Japan) was guided into the common carotid artery with a coaxial system using a 6-F inner catheter (JB2; Medikit Co. Ltd., Tokyo, Japan) and a 0.035-inch stiff guidewire (Radifocus Guidewire M Stiff type; Terumo Corporation, Tokyo, Japan). The OPTIMO balloon was then connected to a 4-F short sheath, which was placed in the femoral vein through a filter for blood transfusion as a flow reversal system. To prevent the backflow of blood from the external



carotid artery (ECA), a carotid GuardWire (Medtronic, Minneapolis, Minnesota, USA) was placed in the ECA at the proximal side of the bifurcation of the superior thyroid artery. Under the flow reversal condition with the OPTIMO balloon and carotid GuardWire inflated, a FilterWire EZ was gently passed through the stenotic lesion and deployed in the petrous portion of the ICA to provide distal protection. Before stenting, the OPTIMO balloon was deflated to allow IVUS to be performed and then reinflated to prevent the inflow of blood while angioscopy was performed with a saline flush to wash out blood. Then under the flow reversal condition, predilation for percutaneous transluminal angioplasty was performed with a balloon selected according to the size of a normal portion of the ICA. A carotid WALLSTENT (Boston Scientific) was placed to completely cover the plaque. After stenting, postdilation with the percutaneous transluminal angioplasty balloon was followed by blood aspiration using an aspiration catheter (Medtronic) until all debris had been removed. The aspirated blood was infused via a filter through the sheath at the femoral vein. After aspiration, IVUS and angioscopy were performed again.

Intravascular Ultrasound

IVUS was performed using an Eagle Eye Platinum IVUS catheter (Philips Corporation, San Diego, California, USA) with a Volcano s5 IVUS imaging system (Philips Corporation). Plaque protrusion

was detected by ChromaFlo (Philips Corporation) IVUS, which colorizes the flow, as defects in the flow.

Angioscopy

Angioscopy was performed using a VISIBLE Fiber angioscope (FiberTech Co., Ltd., Tokyo, Japan) (external diameter of the inserted part, 0.75 mm; effective length, 1620 mm) with an imaging system, FT-203F (FiberTech Co., Ltd.). based on 3 charge-coupled devices (Figure 1). Once the modified PAES and distal protection were in place, as described under Carotid Artery Stenting, the angioscope was inserted into the aspiration catheter and guided to the distal side of the carotid lesion. With the blood flow to the ICA interrupted by the OPTIMO balloon in the common carotid artery and the carotid GuardWire in ECA, intraluminal blood was expelled by flushing approximately 50 mL of physiologic saline through the OPTIMO balloon, allowing the vascular and stent lumens to be clearly observed (Figure 2).

Statistical Analysis

JMP Version 10 software (SAS Institute Inc., Cary, North Carolina, USA) was used for statistical analysis. Data were compared by using χ^2 test with Fisher exact test. *P* values <0.05 were considered statistically significant. Factors with *P* < 0.3 in χ^2 tests were included in multivariate logistic regression analysis.

RESULTS

This study enrolled 11 patients. Two patients had bilateral lesions; thus, 13 lesions were analyzed. In the preprocedural plaque evaluations, the mean level of ICA stenosis was 79.2%. Of lesions, 8 were symptomatic, and 5 were asymptomatic; 5 were identified as potentially having vulnerable plaque on preprocedural MRI. All lesions were treated with a carotid WALLSTENT, and additional stenting was needed in only 1 case (Table 1). No patient exhibited any new neurologic deficit after CAS.

After stenting, angiography provided good visualization in all cases with no difficulties. IVUS revealed plaque protrusion in only 1 lesion in case 4, whereas angiography showed plaque protrusions in 8 lesions (Figure 3 and Table 2); this difference in detection rate was statistically significant ($P = 0.011$). In case 4, fluttering plaque protrusion in the stent was observed by angiography but was not recognized by IVUS (Videos 1 and 2). The plaque protrusion pointed out by IVUS was described more clearly by angiography (Figure 3). In 4 lesions, yellow plaques were observed on angiography, but not on IVUS.

DWI in the postprocedural MRI showed high-intensity spots in the ipsilateral cerebral hemisphere with 3 of the lesions (23%). Two of these lesions had been identified as potentially having vulnerable plaque on preprocedural MRI. In 2 of the 3 lesions, DWI-positive plaque protrusions could not be observed by IVUS; however, in these lesions, plaque protrusion could be observed by angiography (Table 2). All DWI-positive lesions after CAS were observed on angiography to have yellow plaque protrusions. The only factor to show a statistically significant relationship with the DWI-positive lesions was the existence of yellow plaque observed by angiography ($P = 0.014$) (Table 3). Multivariate logistic regression analysis revealed that the existence of yellow plaque

was the only factor that had a significant relationship with DWI-positive lesions, as observed using postprocedural MRI ($P = 0.033$) (Table 3).

DISCUSSION

Since the SAPPHERE report in 2004 and the Carotid Revascularization Endarterectomy versus Stenting Trial (CREST) in 2010, CAS has been performed to treat patients with evidence for high risk and standard risk for carotid artery endarterectomy (CEA).^{16,17} However, the risk of periprocedural ischemic complications is higher with CAS than with CEA. The CREST study reported more frequent periprocedural cerebral ischemic complications in the CAS group than in the CEA group (4.1% vs. 2.3%).¹⁷ Various studies have reported DWI-positive findings after CAS in 17.3%–64% of cases^{3,18–22}; however, these studies differed in the technique used for the CAS procedure, such as embolic protection, the type of stent used, and whether there was predilatation or postdilatation. In a systematic review, Schnaudigel et al.¹⁹ reported that the rate of DWI-positive findings was significantly higher with CAS than with CEA (37% vs. 10%). In CAS using dual protection, the modified Parodi method, and distal protection with a filter wire in the ICA, the DWI-positive rate was reported as 17.3%,²¹ a lower rate than with other protection techniques; for this reason, we used the dual protection technique in the present study. Angiography was used in our study, and the DWI-positive rate was 23%, a level regarded as tolerable compared with rates in past reports.

DWI-positive lesions after CAS have been reported to be associated with ischemic events.²³ In addition, a relationship between the character of the plaque and the risk of periprocedural ischemic complications with CAS has been



Video available at
www.sciencedirect.com

Table 1. Basic Characteristics of Patients

Case	Age (Years)/Sex	Symptoms	Side	Stenosis Rate	Plaque Appearance	APT	Stent
1	76/M	Asymptomatic	Left	70%	Stable	A + Cl + Ci	CW
2	80/M	Symptomatic	Right	95%	Soft	A + Cl + Ci	CW
3	72/M	Symptomatic	Right	95%	Soft	A + Cl + Ci	CW
4	67/M	Symptomatic	Right	90%	Stable	A + Cl + Ci	CW + CW
4	67/M	Symptomatic	Left	84%	Stable	A + Cl + Ci	CW
5	50/F	Symptomatic	Right	87%	Stable	A + Cl + Ci	CW
6	68/M	Symptomatic	Left	95%	Stable	A + Cl + Ci	CW
7	66/M	Asymptomatic	Right	80%	Stable	A + Cl + Ci	CW
8	72/M	Asymptomatic	Left	67%	Stable	A + Cl + Ci	CW
9	70/M	Asymptomatic	Right	58%	Stable	A + Cl + Ci	CW
10	72/M	Symptomatic	Left	50%	Soft	Cl + Ci	CW
10	72/M	Symptomatic	Right	82%	Soft	Cl + Ci	CW
11	79/M	Asymptomatic	Right	86%	Soft	Cl + A + Ci	CW

APT, antiplatelet therapy; M, male; A, aspirin; Cl, clopidogrel; Ci, cilostazol; CW, carotid WALLSTENT; F, female.

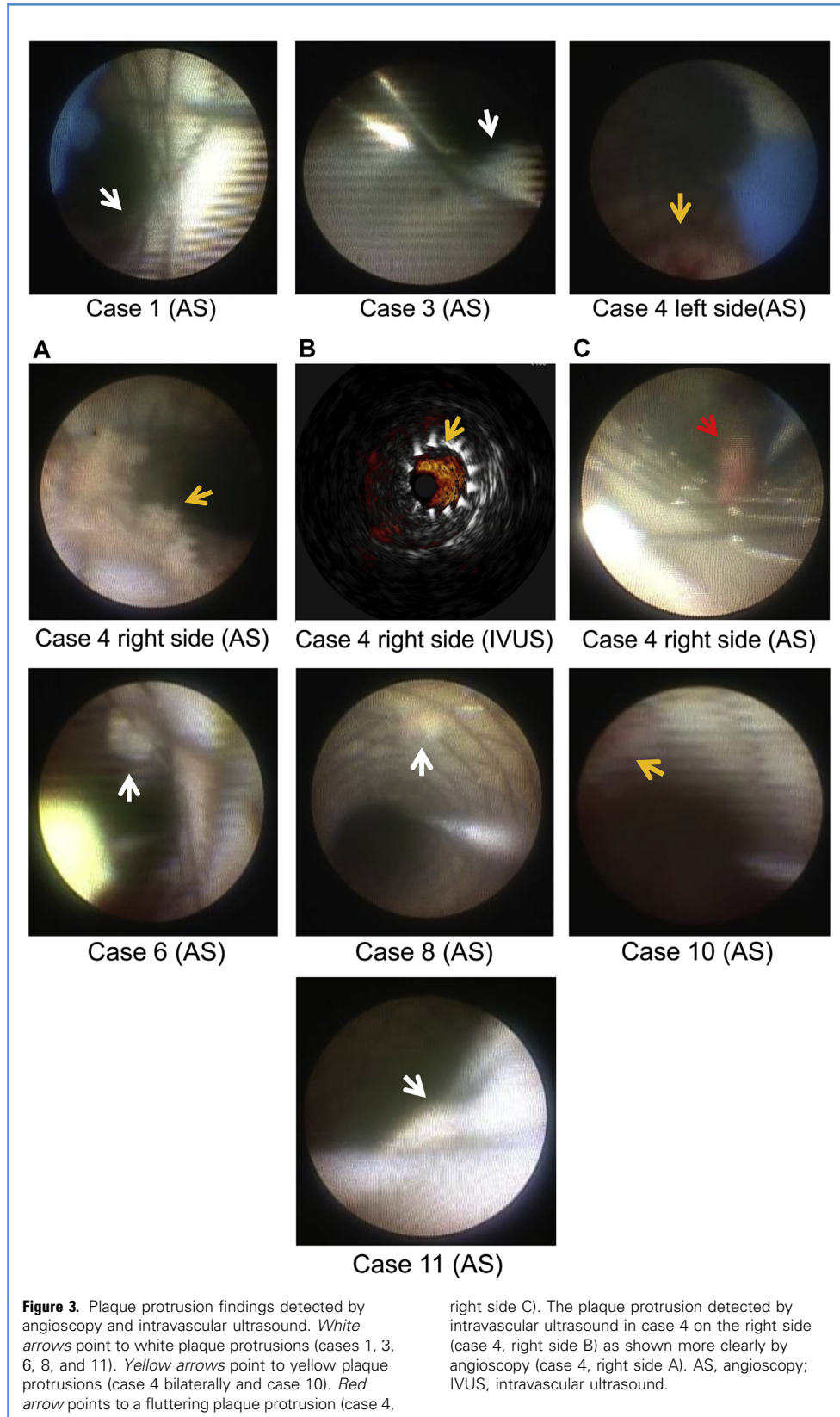


Table 2. Findings Observed After Evaluation of Lumens of Stent by Intravascular Ultrasound and Angioscopy

Case	Plaque Protrusion on IVUS	Plaque Protrusion on Angioscopy	DWI High Spots	Neurologic Change
1	No	White plaque	No	No
2	No	No	No	No
3	No	White plaque	No	No
4 (right)	Yes	Yellow plaque and flutter plaque	Yes	No
4 (left)	No	Yellow plaque	No	No
5	No	No	No	No
6	No	White plaque	No	No
7	No	No	No	No
8	No	White plaque	No	No
9	No	No	No	No
10 (left)	No	Yellow plaque	Yes	No
10 (right)	No	No	No	No
11	No	Yellow plaque	Yes	No

IVUS, intravascular ultrasound; DWI, diffusion-weighted imaging.

observed.²⁴ Therefore, the preprocedural assessment of plaque morphology is considered to be important. In reports of the preprocedural evaluation of plaque morphology by carotid ultrasound and MRI, the presence or absence of vulnerable plaques, which are a risk factor for periprocedural cerebral ischemic complication, has been proposed as an index.²⁴⁻²⁷ In addition, it has been reported that there was a relationship between plaque volume measured with three-dimensional T1-weighted gradient echo sequence on MRI and the rate of DWI-positive at postprocedural MRI.²⁸ In the present study, 3 of 5 lesions that had been identified as having potentially vulnerable plaque before CAS showed DWI high-intensity spots in the ipsilateral hemisphere on postprocedural MRI.

Although in this report there was no significant relationship between the vulnerable plaque in preprocedural MRI and postprocedural DWI-positive lesions, as indicated in some past reports, the preprocedural evaluation of plaque is thought to be important to help avoid ischemic complication after CAS.²⁴⁻²⁷

The intraprocedural evaluation of plaque protrusion and thrombus is also considered to be important in CAS. If findings associated with a high risk for ischemic complications, such as plaque protrusion and vulnerable plaque, can be detected during the procedure, additional treatment can be provided to avoid these complications. Although there have been various reports of the intraprocedural observation and evaluation during CAS procedures of plaque protrusions in the stent lumen by IVUS¹⁻³ and OCT,⁴⁻⁶ there have been only a few reports about the use of angioscopy in CAS.^{14,15} Conversely, there have been several reports since the 1980s of use of angioscopy in coronary artery diseases.⁷⁻¹² Uchida¹⁰ reviewed the angioscopic features of plaque, especially vulnerable plaque, and evaluated the neointimal coverage of stents in the coronary artery.

IVUS, OCT, and angioscopy allow real-time evaluation of plaque properties before stent placement and the detection of plaque protrusions after stent placement. The most significant difference between IVUS or OCT and angioscopy is that angioscopy can directly visualize the lumen of the vessel and stent. However, a search of the literature found no previous study that compared the evaluation of plaque protrusions by angioscopy with that by IVUS or OCT in CAS. Using IVUS, the frequency of detecting plaque protrusions after CAS has been reported as 2.6%–7.8%.¹⁻³ The rate of plaque prolapse detected by OCT after CAS has been reported as 17.6%–40.2%.^{5,6} In comparison, Tanemura et al.¹⁵ reported the frequency of plaque protrusion identified by angioscopy after CAS to be 25%. Thus, the rate of detection of plaque protrusion after CAS was higher with angioscopy than with IVUS. This was consistent with the findings of the present study, with angioscopy detecting 8 plaque protrusions and IVUS detecting only 1. Of the 3 patients with DWI-positive lesions on MRI after CAS, plaque protrusion was detected by IVUS in only 1, whereas it was observed in all 3 patients on angioscopy. The relationship between plaque protrusions detected by both IVUS and angiography, DWI-positive lesions, and ischemic complications has been reported.³ However, in the present study, 2 of 3 lesions with DWI-positive lesions were not observed as plaque protrusion with IVUS. There was no statistically significant relationship between plaque protrusion detected by IVUS,

Table 3. Comparison of Postprocedural Diffusion-Weighted Imaging Between Factors

	High-Intensity Spot on DWI (n = 3)	No High-Intensity Spot on DWI (n = 10)	χ^2 Test with Fisher Exact Test P Value	Multivariable Logistic Regression Analysis P Value
Symptomatic	2	6	1	—
Vulnerable plaque by MRI	2	3	0.511	—
Plaque protrusion by IVUS	1	0	0.23	0.41
Plaque protrusion by AS	3	5	0.231	1
Yellow plaque by AS	3	1	0.014	0.033

DWI, diffusion-weighted imaging; MRI, magnetic resonance imaging; IVUS, intravascular ultrasound; AS, angiography.

angiography, and DWI-positive lesions. However, all of the DWI-positive lesions were observed to be yellow plaque protrusions on angiography. In this study, only the yellow plaque protrusions showed a statistically significant relationship with the DWI-positive lesions. In coronary disease, there is an association between a yellow plaque and the thickness of the fibrous cap of the plaque; hence, yellow plaque detected by angiography has been considered to be vulnerable.¹¹ In coronary disease, an association between yellow plaque and distal embolization of plaque debris has been shown.¹² It therefore appears that IVUS alone is insufficient for evaluating plaque protrusion in CAS as well as in coronary stenting. Thus, it may be better to evaluate the plaque protrusion with angiography rather than IVUS alone when a lesion is considered to be vulnerable plaque on preprocedural MRI.

The first problem of angiography is to obtain a clear view. Tanemura et al.¹⁵ reported that a clear view was not obtained in one third (6) of the lesions investigated, with insufficient washout of blood experienced in 4 of those 6 lesions. It is necessary to use a physiologic saline flush to expel the blood almost completely from the vessel lumen. In that report, embolic protection was provided by distal balloon protection alone or PAES without distal protection from a filter device in the ICA. Therefore, in the present study, the CAS procedure and angiography were performed under proximal and distal protection, modified PAES, and distal protection with a filter device. The common carotid artery and ECA were occluded by balloon, on the proximal side to the superior thyroid artery where possible, allowing the blood flow to be reduced enough to expel the blood with a saline flush. This allowed a clear view to be obtained for all the lesions.

The second problem associated with angiography is the increase in DWI-positive lesions from flushing saline to expel the blood in the stent lumen. Tanemura et al.¹⁵ reported a relatively high DWI-positive rate of 47%. Flushing saline to expel blood is thought to involve the risk of transporting vulnerable plaques and debris protruding into the stent lumen to the distal side, resulting in ischemic complications during the periprocedural period. In the present study, in addition to the modified PAES, a filter device in the ICA was used for distal protection. The DWI-positive rate was

lower than in the previous report (23% vs. 47%). Sakamoto et al.²¹ reported that proximal and distal protection can reduce the DWI-positive rate. Using a similar method may therefore reduce the DWI-positive rate even when angiography is used.

The next problem for angiography is the visual field. Tanemura et al.¹⁵ reported that they were unable to obtain 360° observation of the wall of the vessel. Although nearly the entire vessel wall and stent could be observed in the present study, the narrow angle of the visual field may restrict the absorbable area in the lumen, especially in tortuous lesions.

The final problem related to angiography is decision making with regard to the need for additional treatment. In the present study, 3 lesions were associated with DWI-positive findings on post-procedural MRI, and 8 lesions were observed to have plaque protrusion on angiography, with 4 observed to have yellow plaque. Only 1 lesion required an additional stent, and there were no new neurologic deficits in any patient in the periprocedural period. It is unclear which findings by angiography after stenting require additional treatment to avoid periprocedural complications; this needs further consideration. From the results of this study, for the lesion considered as a vulnerable plaque in preoperative evaluation, when the property of plaque protrusion after CAS using angiography confirms as a vulnerable plaque, such as a yellow plaque protrusion or a fluttering plaque, additional treatment may be necessary.

A limitation of this study is that the results cannot be generalized because of the limited number of lesions. To establish the utility and safety of angiography, it is necessary to repeat this investigation with a larger number of cases.

CONCLUSIONS

Angiography allowed direct evaluation of the stent lumens, providing clearer visualization of the lumens of vessel and stent than with IVUS. As a consequence, angiography detected more plaque protrusion and yellow, potentially vulnerable, plaque than was possible with IVUS. Thus, angiography may be more useful than IVUS for examination of plaque protrusion and plaque evaluation after CAS, especially when plaque has been predicted to be vulnerable by MRI before CAS.

REFERENCES

- Shinozaki N, Ogata N, Ikari Y. Plaque protrusion detected by intravascular ultrasound during carotid artery stenting. *J Stroke Cerebrovasc Dis.* 2014; 23:2622-2625.
- Hitchner E, Zayed MA, Lee G, Morrison D, Lane B, Zhou W. Intravascular ultrasound as a clinical adjunct for carotid plaque characterization. *J Vasc Surg.* 2014;59:774-780.
- Kotsugi M, Takayama K, Myouchin K, et al. Carotid artery stenting: investigation of plaque protrusion incidence and prognosis. *JACC Cardiovasc Interv.* 2017;10:824-831.
- Yoshimura S, Kawasaki M, Yamada K, et al. OCT of human carotid arterial plaques. *JACC Cardiovasc Imaging.* 2011;4:432-436.
- Yoshimura S, Kawasaki M, Yamada K, et al. Optical coherence tomography (OCT): a new imaging tool during carotid artery stenting. In: Kawasaki M, ed. *Optical Coherence Tomography*. InTechOpen; 2013. Available at: <https://www.intechopen.com/books/optical-coherence-tomography/optical-coherence-tomography-oct-a-new-imaging-tool-during-carotid-artery-stenting>.
- De Donato G, Setaccci F, Galzerano P, Galzerano G, Cappelli A, Setacci C. Optical coherence tomography after carotid stenting: rate of stent malapposition, plaque prolapse and fibrous cap rupture according to stent design. *Eur J Vasc Surg.* 2013;45:579-587.
- Spears JR, Marais HJ, Serur J, et al. In vivo coronary angiography. *J Am Coll Cardiol.* 1983;1:1311-1314.
- Mizuno K, Arai T, Satomura K, et al. New percutaneous transluminal coronary angiography. *J Am Coll Cardiol.* 1989;13:363-368.
- Uchida Y, Tomaru T, Nakamura F, Furuse A, Fujimori Y, Hasegawa K. Percutaneous coronary angiography in patients with ischemic heart disease. *Am Heart J.* 1987;114:1216-1222.
- Uchida Y. Recent advances in coronary angiography. *J Cardiol.* 2011;57:18-30.
- Kubo T, Imanishi T, Takarada S, et al. Implication of plaque color classification for assessing plaque vulnerability: a coronary angiography and optical tomography investigation. *JACC Cardiovasc Interv.* 2008;1:74-80.
- Matsuo K, Ueda Y, Tsujimoto M, et al. Ruptured plaque and large plaque burden are risks of distal embolisation during percutaneous coronary intervention: evaluation by angiography and virtual histology intravascular ultrasound imaging. *Euro-Intervention.* 2013;9:235-242.

13. Siegel RJ, Ariani M, Fishbein MC, et al. Histopathologic validation of angiography and intravascular ultrasound. *Circulation*. 1991;84:109-117.
14. Kondo H, Kiura Y, Sakamoto S, et al. A case in which angiography was useful for the evaluation of plaque protrusion during carotid artery stenting. *Journal of Neuroendovascular Therapy*. 2017;11:547-552.
15. Tanemura H, Hatazaki S, Asakura F, et al. Angioscopic observation during carotid angioplasty with stent placement. *AJNR Am J Neuroradiol*. 2005;26:1943-1948.
16. Yadav JS, Wholey MH, Kuntz RE, et al. Protected carotid-artery stenting versus endarterectomy in high-risk patients. *N Engl J Med*. 2004;351:1493-1501.
17. Brott TG, Hobson RW, Howard G, et al. Stenting and endarterectomy for treatment of carotid-artery stenosis. *N Engl J Med*. 2010;363:11-23.
18. Satouh K, Hanaoka M, Tamura T, Kinouchi T, Shinno K, Miyake H. Transition of carotid artery stenting treatment in the multiple device era (effectiveness of distal balloon protection CAS treatment using an autologous aspirated blood transfusion). *Surg Cereb Stroke (Jpn)*. 2015;43:347-351.
19. Schnaudigel S, Groschel K, Pilgram SM, Kastrup A. New brain lesion after carotid stenting versus carotid endarterectomy: a systematic review of the literature. *Stroke*. 2008;39:1911-1919.
20. Pinero P, Gonzalez A, Mayol A. Silent ischemia after neuroprotected percutaneous carotid stenting: a diffusion-weighted MRI study. *AJNR Am J Neuroradiol*. 2006;27:1338-1345.
21. Sakamoto S, Kiura Y, Okazaki T, et al. Usefulness of dual protection combined with blood aspiration for distal embolic protection during carotid artery stenting. *Acta Neurochir*. 2015;157:371-377.
22. McDonnell CO, Fearn SJ, Baker SR, Goodman MA, Price D, Lawrence-Brown MMD. Value of diffusion-weighted MRI during carotid angioplasty and stenting. *Eur J Vasc Endovasc Surg*. 2006;32:46-50.
23. Kastrup A, Nagele T, Groschel K, et al. Incidence of new brain lesions after carotid stenting with and without cerebral protection. *Stroke*. 2006;37:2312-2316.
24. Yamada K, Yoshimura S, Kawasaki M, et al. Embolic complications after carotid artery stenting or carotid endarterectomy are associated with tissue characteristics of carotid plaques evaluated by magnetic resonance imaging. *Atherosclerosis*. 2011;215:399-404.
25. Kobayashi E, Ono J, Hirai S, Yamakami I, Saeki N, Yamaura A. Detection of unstable plaques in patients with carotid stenosis using B-mode ultrasonography. *Interv Neuroradiol*. 2000;30:165-170.
26. Koyanagi M, Yoshida K, Kishida N, et al. Carotid artery stenting based on plaque characteristics using magnetic resonance plaque imaging. *Journal of Neuroendovascular Therapy*. 2012;6:240-244.
27. Yoshimura S, Yamada K, Kawasaki M, et al. High-intensity signal on time-of-flight magnetic resonance angiography indicates carotid plaque at high risk for cerebral embolism during stenting. *Stroke*. 2011;42:3132-3137.
28. Tanemura H, Masayuki M, Naoki I, et al. High-risk plaque for carotid artery stenting evaluated with 3-dimensional T1-weighted gradient echo sequence. *Stroke*. 2013;44:105-110.

Conflict of interest statement: The authors declare that the article content was composed in the absence of any commercial or financial relationships that could be construed as a potential conflict of interest.

Received 26 September 2018; accepted 19 January 2019

Citation: World Neurosurg. (2019).

<https://doi.org/10.1016/j.wneu.2019.01.102>

Journal homepage: www.journals.elsevier.com/world-neurosurgery

Available online: www.sciencedirect.com

1878-8750/\$ - see front matter © 2019 Elsevier Inc. All rights reserved.