

**Clinical significance of JNET classification and a proposal of
countermeasure for issue of this classification**
(JNET 分類の臨床的意義と課題解決策の提唱)

Kyoku Sumimoto



Clinical impact and characteristics of the narrow-band imaging magnifying endoscopic classification of colorectal tumors proposed by the Japan NBI Expert Team

Kyoku Sumimoto, MD,¹ Shinji Tanaka, MD, PhD,² Kenjiro Shigita, MD,¹ Daiki Hirano, MD,¹ Yuzuru Tamaru, MD,¹ Yuki Ninomiya, MD,¹ Naoki Asayama, MD,¹ Nana Hayashi, MD, PhD,² Shiro Oka, MD, PhD,² Koji Arihiro, MD, PhD,³ Masaharu Yoshihara, MD, PhD,⁴ Kazuaki Chayama, MD, PhD¹

Hiroshima, Japan

Background and Aims: The Japan NBI Expert Team (JNET) was established in 2011 and has proposed a universal narrow-band imaging (NBI) magnifying endoscopic classification of colorectal tumors. The aim of this study was to evaluate the clinical usefulness of the JNET classification for colorectal lesions.

Methods: We analyzed 2933 colorectal lesions, which were diagnosed by NBI magnifying observation before endoscopic treatment or surgery. The colorectal lesions consisted of 136 hyperplastic polyps/sessile serrated polyps (HPs/SSPs), 1926 low-grade dysplasia (LGD), 571 high-grade dysplasia (HGD), 87 superficial submucosal invasive (SM-s) carcinomas, and 213 deep submucosal invasive (SM-d) carcinomas. We evaluated the relationship between the JNET classification and the histologic findings of these lesions.

Results: The sensitivity, specificity, positive and negative predictive values, and accuracy of Type 1 lesions for the diagnosis of HP/SSP were, respectively, 87.5%, 99.9%, 97.5%, 99.4%, and 99.3%; of Type 2A lesions for the diagnosis of LGD were 74.3%, 92.7%, 98.3%, 38.7%, and 77.1%; of Type 2B lesions for the diagnosis of HGD/SM-s carcinoma were 61.9%, 82.8%, 50.9%, 88.2%, and 78.1%; for Type 3 lesions for the diagnosis of SM-d carcinoma were 55.4%, 99.8%, 95.2%, 96.6%, and 96.6%, respectively.

Conclusions: Types 1, 2A, and 3 of the JNET classification were very reliable indicators for HP/SSP, LGD, and SM-d carcinoma, respectively. However, the specificity and positive predictive value of Type 2B were relatively lower than those of others. Therefore, an additional examination such as pit pattern diagnosis using chromo-agents is necessary for accurate diagnosis of Type 2B lesions. (*Gastrointest Endosc* 2017;85:816-21.)

Since the development of narrow-band imaging (NBI) in 1999, it has been a reliable tool that has contributed to improved diagnostic precision, such as detection of colorectal polyps,¹⁻⁴ ulcerative colitis screening,⁵⁻⁷ differentiation of neoplastic lesions from non-neoplastic lesions, and characterization of colorectal neoplasia.⁸⁻¹⁴ Today, several colorectal NBI magnifying classifications, such as

Hiroshima classification, Sano classification, Showa classification, and Jikei classification, are widely used and play a significant role clinically as well as pit pattern diagnosis.^{15,16} On the other hand, in Western countries, magnifying endoscopy is not commonly used in daily practice.

The Colon Tumor NBI Interest Group proposed a new NBI classification called the NBI International Colorectal

Abbreviations: ESD, endoscopic submucosal dissection; HGD, high-grade dysplasia; HP, hyperplastic polyp; JNET, the Japan NBI Expert Team; LGD, low-grade dysplasia; NICE classification, the NBI International Colorectal Endoscopic classification; NBI, narrow-band imaging; NPV, negative predictive value; PPV, positive predictive value; SM-d, deep submucosal invasive; SM-s, superficial submucosal invasive; SSP, sessile serrated polyp.

DISCLOSURE: All authors disclosed no financial relationships relevant to this publication. Research support for this study was provided to Shinji Tanaka by a Grant-in-Aid from the Japan Agency for Medical Research and Development (no. 15ck0106102b0102).

Copyright © 2017 by the American Society for Gastrointestinal Endoscopy 0016-5107/\$36.00

<http://dx.doi.org/10.1016/j.gie.2016.07.035>

Received February 1, 2016. Accepted July 3, 2016.

Current affiliations: Department of Gastroenterology and Metabolism (1), Department of Endoscopy (2), Department of Anatomical Pathology (3), Health Service Center (4), Hiroshima University Hospital, Hiroshima, Japan.

Reprint requests: Shinji Tanaka, Department of Endoscopy, Hiroshima University Hospital, 1-2-3 Kasumi, Minami-ku, Hiroshima 734-8551, Japan.

Endoscopic (NICE) classification in 2009,¹⁷ and validation studies were conducted in 2012.^{18,19} It is the first NBI classification that can be used both with and without magnifying endoscopy and has therefore spread all over the world.^{17,20} It is composed of 3 types that are divided according to color, vessels, and surface pattern. Type 1 is an indicator for hyperplastic polyp (HP), Type 3 is an indicator for deep submucosal invasive (SM-d) carcinoma, and Type 2 is an indicator for the other lesions of various histologic types, including low-grade dysplasia (LGD) to superficial submucosal invasive (SM-s) carcinoma (Table 1).¹⁹

The NICE classification is significantly useful because of its high diagnostic accuracy in detecting both non-neoplasia that does not need to be removed and SM-d carcinoma that needs to be resected by surgery.^{21,22} However, it is difficult to differentiate high-grade dysplasia (HGD) or SM-s carcinoma from LGD.^{17,23} This fact creates a clinical problem. We cannot determine the mode of endoscopic treatment, such as piecemeal endoscopic mucosal resection (EMR) or en bloc EMR/endoscopic submucosal dissection (ESD), for NICE Type 2 lesions because whether piecemeal EMR can be selected as a therapeutic method is based on the histologic characteristics of the lesions. If piecemeal EMR is not allowed for malignant lesions, to obtain a precise histologic diagnosis of a resected specimen we need to select ESD or surgery.^{15,23}

To solve this issue, the Japanese NBI Expert Team (JNET) composed of Japanese magnifying colonoscopists was organized in 2011. Going through repeated detailed discussion and a web-based prospective trial, the JNET achieved consensus regarding NBI classification, and a new NBI colorectal magnifying classification (the JNET classification) was proposed in 2014.²⁴ In this study we evaluated the clinical usefulness and problems of the JNET classification.

METHODS

In this study, NBI magnifying observation was performed at the Department of Endoscopy at Hiroshima University Hospital between January 2011 and March 2015. At this time 2933 consecutive cases of colorectal lesions, which had been endoscopically or surgically resected, were retrospectively analyzed. On the basis of histologic characteristics, 2933 lesions were identified as the following: HP/sessile serrated polyp (SSP) (136 lesions), LGD such as tubular adenoma/tubulovillous adenoma (1926 lesions), HGD (571 lesions), SM-s carcinoma less than 1000 μm (87 lesions), and SM-d carcinoma deeper than 1000 μm (213 lesions).

For these lesions, 3 colonoscopists with enough experience applied the JNET classification; the colorectal NBI magnifying classification consists of 4 types that are classified based on vessel pattern and surface pattern. The characteristics of Type 1 are invisible vessel pattern and having

dark and white spots as surface pattern. The characteristics of Type 2A are regular vessel pattern, such as regular caliber or distribution, and regular surface pattern. The characteristics of Type 2B are irregular vessel pattern, such as variable caliber, irregular distribution, and irregular or obscure surface pattern. The characteristics of Type 3 are loose vessel areas or interruption of thick vessels and amorphous surface pattern (Fig. 1). These 3 colonoscopists were not involved in the endoscopic diagnosis of the lesions, and evaluation was performed objectively. In this process, the colonoscopists were blinded to all information concerning the endoscopic images and histopathologic findings.

The instrument used in this study was a magnifying videoendoscope system (CF-H260AZI; Olympus, Tokyo, Japan). The resected lesions were pathologically diagnosed in accordance with the criteria of the World Health Organization.²⁵ One pathologist diagnosed all cases without any clinical information. Using these cases, we examined the relationship between each type of the JNET classification and histopathologic findings. The study protocol was approved by the Ethics Committee of Hiroshima University.

Statistical analysis

We calculated sensitivity, specificity, positive and negative predictive value (PPV and NPV), and accuracy for each category of the classification. The criterion standard for validation of predictions was the histology of colorectal lesions.

To calculate the interobserver agreement, we selected recent consecutive 1000 lesions. All 3 colonoscopists, who were blinded to all clinical information of lesions concerning endoscopic images and histopathologic findings, diagnosed NBI magnifying images simultaneously and recorded each JNET classification diagnosis. The interobserver agreement results based on the value of kappa statistics were defined as follows: poor, .2; fair, .21 to .4; moderate, .41 to .6; substantial, .61 to .8; and excellent, .81 to 1.

RESULTS

The relationship between NBI magnification findings and the histologic features of the colorectal lesions is shown in Table 2. Histologically, 98% (119/122) and 2% (3/122) of Type 1 lesions were identified as HP/SSP and LGD, respectively. In addition, 1% (17/1888), 86% (1626/1888), and 13% (245/1888) of Type 2A lesions were identified as HP/SSP, LGD, and HGD–SM-s carcinoma, respectively. Thirty-seven percent (297/799), 51% (407/799), and 12% (95/799) of Type 2B lesions were identified as LGD, HGD–SM-s carcinoma, and SM-d carcinoma, respectively. Five percent (5/124) and 95% (118/124) of Type 3 lesions were identified as HGD–SM-s carcinoma and SM-d carcinoma, respectively. The difference in the

TABLE 1. NBI International Colorectal Endoscopic (NICE) classification*

	Type 1	Type 2	Type 3
Color	Same or lighter than background	Browner relative to background (verify color arises from vessels)	Brown to dark brown relative to background; sometimes patchy whiter areas
Vessels	None, or isolated lacy vessels may be present coursing across the lesion	Brown vessels surrounding white structures†	Has area(s) with disrupted or missing vessels
Surface pattern	Dark or white spots of uniform size, or homogenous absence of pattern	Oval, tubular, or branched white structures† surrounded by brown vessels	Amorphous or absence of pattern
Most likely pathology	Hyperplastic & sessile serrated polyp (SSP)‡	Adenoma§	Deep submucosal invasive cancer

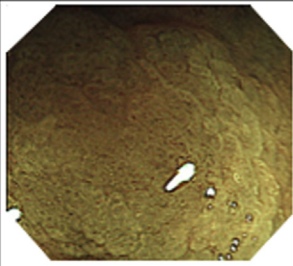
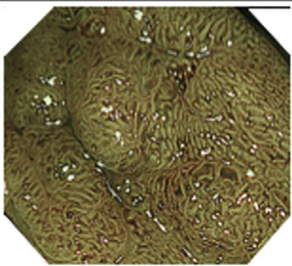
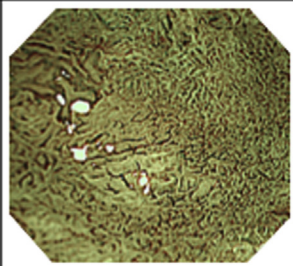

*Can be applied using colonoscopes both with or without optical (zoom) magnification.

†These structures (regular or irregular) may represent the pits and the epithelium of the crypt opening.

‡In the World Health Organization classification,²⁵ sessile serrated polyp and sessile serrated adenoma are synonymous.

§Type 2 consists of Vienna classification types 3, 4, and superficial 5 (all adenomas with either low and high grade dysplasia, or with superficial submucosal carcinoma). The presence of high grade dysplasia or superficial submucosal carcinoma may be suggested by an irregular vessel or surface pattern and is often associated with atypical morphology (eg, depressed area).

Japanese NBI Expert Team (JNET) classification

NBI	Type 1	Type 2A	Type 2B	Type 3
Vessel pattern	• Invisible ^{⊗1}	• Regular caliber • Regular distribution ^{⊗2} (meshed/spiral pattern)	• Variable caliber • Irregular distribution	• Loose vessel areas • Interruption of thick vessels
Surface pattern	• Regular dark or white spots • Similar to surrounding normal mucosa	• Regular (tubular/branched/papillary)	• Irregular or obscure	• Amorphous areas
Most likely histology	Hyperplastic polyp/ Sessile serrated polyp	Low-grade intramucosal neoplasia ^{⊗4}	High-grade intramucosal neoplasia/ Superficial ^{⊗5} submucosal invasive cancer	Deep submucosal invasive cancer
Examples				

*1. If visible, the caliber in the lesion is similar to surrounding normal mucosa.

*2. Microvessels are often distributed in a punctate pattern and well-ordered reticular or spiral vessels may not be observed in depressed lesions.

*3. Deep submucosal invasive cancer may be included.

*4. Low-grade intramucosal neoplasia: low-grade dysplasia.

*5. High-grade intramucosal neoplasia: high-grade dysplasia.

Figure 1. Japanese NBI Expert Team classification system.

percentage of HP/SSP versus LGD among Type 1 lesions was significant. The difference in the percentage of LGD versus HGD–SM-s carcinoma among Type 2A lesions was also significant, as was the difference in the percentage of SM-d carcinoma versus HGD–SM-s carcinoma among

Type 3 lesions. However, the percentages of HGD–SM-s carcinoma and LGD among Type 2B were similar; both were nearly 40%.

The diagnostic characteristics of each category are shown in Table 3. The sensitivity, specificity, PPV, NPV,

TABLE 2. Relationship between the JNET classification and histologic findings in colorectal lesions

JNET classification	N (%)	Histologic findings				
		HP/SSP	LGD	HGD	Carcinoma	
					SM-s	SM-d
Type 1	122 (100)	119 (98)	3 (2)			
Type 2A	1888 (100)	17 (1)	1626 (86)	230 (12)	15 (1)	
Type 2B	799 (100)		297 (37)	340 (43)	67 (8)	95 (12)
Type 3	124 (100)			1 (1)	5 (4)	118 (95)
Total	2933	136	1926	571	87	213

Values are total number of cases with percents in parentheses.

TABLE 3. Performance characteristics of each type of the JNET classification*

JNET classification	Sensitivity	Specificity	PPV	NPV	Accuracy
Type 1	87.5 (81.9-93.1)	99.9 (99.8-100.0)	97.5 (94.8-100.3)	99.4 (99.1-99.7)	99.3 (99.0-99.6)
Type 2A	74.3 (72.6-76.0)	92.7 (90.2-95.1)	98.3 (97.7-98.9)	38.7 (35.7-41.6)	77.1 (75.5-78.6)
Type 2B	61.9 (58.1-65.6)	82.8 (81.2-84.3)	50.9 (47.5-54.4)	88.2 (86.9-89.6)	78.1 (76.6-79.6)
Type 3	55.4 (48.7-62.1)	99.8 (99.6-100.0)	95.2 (91.4-98.9)	96.6 (95.9-97.3)	96.6 (95.9-97.2)

*Values are percents with 95% confidence interval in parentheses.

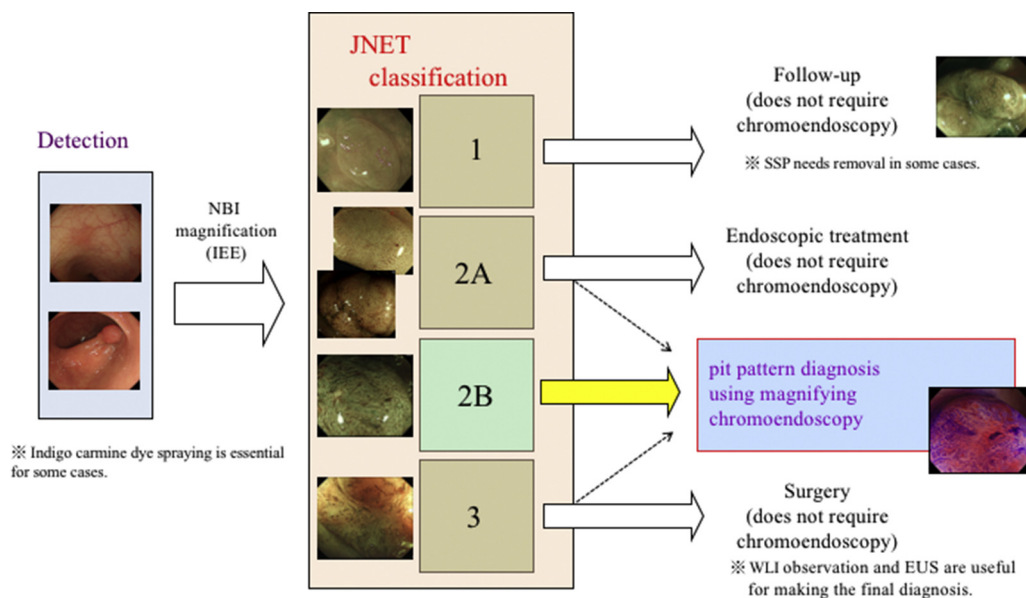


Figure 2. Strategy for endoscopic treatment of colorectal lesions. *NBI*, narrow-band imaging; *IEE*, image-enhanced endoscopy; *WLI*, white light imaging; *EUS*, endoscopic ultrasonography.

and accuracy of Type 1 lesions for the diagnosis of HP/SSP were 87.5%, 99.9%, 97.5%, 99.4%, and 99.3%, respectively. The sensitivity, specificity, PPV, NPV, and accuracy of Type 2A lesions for the diagnosis of LGD were 74.3%, 92.7%, 98.3%, 38.7%, and 77.1%, respectively, and those of Type 2B lesions for the diagnosis of HGD–SM-s carcinoma were 61.9%, 82.8%, 50.9%, 88.2%, and 78.1%, respectively. Last, the sensitivity, specificity, PPV, NPV, and accuracy of Type 3 lesions for the diagnosis of SM-d carcinoma were

55.4%, 99.8%, 95.2%, 96.6%, and 96.6%, respectively. The overall interobserver agreement was good ($\kappa = .749$).

DISCUSSION

Removal of all adenomatous polyps has been standardized in Western countries because it can reduce colorectal cancer incidence and mortality.^{26,27} It is therefore routine

practice to retrieve polyps and collect them for pathologic evaluation. The interval of time to next surveillance colonoscopy can be only decided according to the final histologic diagnosis.²⁸ The “Resect and Discard” policy has been advocated²⁹⁻³² and states that an HP should be left in order to reduce the adverse events of polypectomy and cost of medical care.^{28,33-35} On the other hand, SM-d carcinoma is generally an indication for surgery because of its high risk of lymph node metastasis. The NICE classification is simple and very useful in identifying the lesions that do not need treatment and those that warrant surgery.^{17,19,36}

As reported previously, lesions showing NICE Type 2 include various lesions from LGD to SM-s carcinoma. Generally, piecemeal EMR can be allowed for benign adenoma. However, HGD–SM-s carcinoma should be completely resected by en bloc EMR or ESD to obtain a precise histologic diagnosis for judgment of curability, including the risk stratification of lymph node metastasis. Therefore, the diagnosis of NICE Type 2 is insufficient for the correct selection of a therapeutic method, such as piecemeal EMR or ESD.¹⁷

To distinguish LGD from HGD–SM-s carcinoma, magnifying detailed observation is needed.^{14,32,37-40} To solve this problem and unify the various NBI classifications in Japan, the JNET was established in 2011, and a new NBI classification with magnification (the JNET classification) was proposed in 2015.²⁴ The principles and characteristics of the JNET classification are as follows: (1) the use of magnification is essential and the base is the NICE classification; (2) in the JNET classification, NICE Type 2 is divided into 2 subtypes (2A and 2B) using magnifying findings; (3) because magnification does not need estimation of color, the JNET classification does not include the finding of color; and (4) basic findings are composed of both vessel pattern and surface pattern.

Our results in this study showed the sensitivity, specificity, PPV, NPV, and accuracy of each type for the most likely kind of histology found in the JNET classification. Types 1, 2A, and 3 have a specificity over 90% and a high PPV over 95%. This means that Types 1, 2A, and 3 of the JNET classification are definite indicators of their respective most likely histology, with significant diagnostic accuracy. On the other hand, the specificity of Type 2B was 82.8% and PPV of Type 2B was 50.9%, significantly lower than those of the others. Thus, the ability of Type 2B to identify HGD–SM-s carcinoma is not significant. This may be because of the variety of Type 2B lesions; Types 1, 2A, and 3 lesions correspond to their respective most likely histology, which occupies more than 95% of each type (HP/SSP for Type 1, LGD for Type 2A, and SM-d carcinoma for Type 3). The lesions with irregular vessel and irregular surface patterns are classified as Type 2B, and show various histologic findings, ranging from LGD to SM-d carcinoma.

According to these results, in daily practice the JNET classification is useful for characterization of colorectal

lesions of Types 1, 2A, and 3. Being different from detection of tumor in screening colonoscopy in which sensitivity is important, in the diagnosis before treatment the specificity of the classification is more reliable and important for determining the adequate treatment method for each lesion. On the other hand, lesions of Type 2B need an additional pit pattern diagnosis using magnification with chromoagents such as indigo carmine or crystal violet.^{21,37,41,42} Of course, even for the diagnosis of Types 1, 2A, and 3, if the confidence level is low, an additional pit pattern diagnosis using chromoagents should be applied (Fig. 2).^{23,45} At present, the optical zoom magnifying endoscope is not widely used in clinical practice in Western countries; however, recently the use of magnification has been increasing step by step all over the world. The Exela III and Lucera Elite systems (Olympus), recently developed videoendoscope systems and also used in Western countries, have a function of dual focus with electronic zoom, providing almost the same image of optical zoom magnifying images. Thus, magnification has gradually become common, and it is expected to become standard in the near future. Also, dye spray chromoendoscopy is expected to become common in relation to the spread of magnification.

Finally, the NICE classification has been used practically worldwide without requiring the technique of magnifying endoscopy because of its simplicity, convenience, high accuracy, and practical usefulness for diagnoses and decisions regarding treatment methods.^{12,17,18} The recently proposed JNET classification is a unified, detailed Japanese magnifying NBI classification based on this NICE classification. In this study, we preliminarily examined the characteristics and pitfalls of the JNET classification. A detailed validation study of the JNET classification, including the diagnostic ability of the relationship with each NBI magnifying finding, is now ongoing by the JNET.

REFERENCES

1. Rex DK, Helbig CC. High yields of small and flat adenomas: with high-definition colonoscopes using either white light or narrow band imaging. *Gastroenterology* 2007;133:42-7.
2. Kaltenbach TR, Friedland S, Soetikno R. A randomized tandem colonoscopy trial of narrow band imaging versus white light examination to compare neoplasia miss rates. *Gut* 2008;57:1406-12.
3. Uraoka T, Saito Y, Matsuda T, et al. Detectability of colorectal neoplastic lesions using a narrow-band imaging system: a pilot study. *J Gastroenterol Hepatol* 2008;23:1810-5.
4. Horimatsu T, Sano Y, Tanaka S, et al. Next-generation narrow band imaging system for colonic polyp detection: a prospective multicenter randomized trial. *Int J Colorectal Dis* 2015;30:947-54.
5. Ignjatovic A, East JE, Subramanian V, et al. Narrow band imaging for detection of dysplasia in colitis: a randomized controlled trial. *Am J Gastroenterol* 2012;107:885-90.
6. Rodrigues S, Pereira P, Magro F, et al. Dysplasia surveillance in an ulcerative colitis patient: successful detection with narrow band imaging and magnification. *J Crohns Colitis* 2012;5:54-6.

7. Leifeld L, Rogler G, Stallmach A, et al. White-light or narrow-band imaging colonoscopy in surveillance of ulcerative colitis: a prospective multicenter study. *Clin Gastroenterol Hepatol* 2015;13:1776-81.
8. Hirata M, Tanaka S, Oka S, et al. Magnifying endoscopy with narrow band imaging for diagnosis of colorectal tumors. *Gastrointest Endosc* 2007;65:988-95.
9. Hirata M, Tanaka S, Oka S, et al. Evaluation of microvessels in colorectal tumors by narrow band imaging magnification. *Gastrointest Endosc* 2007;66:945-52.
10. Rogart JN, Jain D, Siddiqui UD, et al. Narrow-band imaging without high magnification to differentiate polyps during real-time colonoscopy: improvement with experience. *Gastrointest Endosc* 2008;68:1136-45.
11. Kanao H, Tanaka S, Oka S, et al. Narrow-band imaging magnification predicts the histology and invasion depth of colorectal tumors. *Gastrointest Endosc* 2009;69:631-6.
12. McGill SK, Evangelou E, Loannidis JPA, et al. Narrow band imaging to differentiate neoplastic and non-neoplastic colorectal polyps in real time: a meta-analysis of diagnostic operating characteristics. *Gut* 2013;62:1704-13.
13. Takata S, Tanaka S, Hayashi N, et al. Characteristic magnifying narrow-band imaging features of colorectal tumors in each growth type. *Int J Colorectal Dis* 2013;28:459-68.
14. Ikematsu H, Matsuda T, Osera S, et al. Usefulness of narrow-band imaging with dual-focus magnification for differential diagnosis of small colorectal polyps. *Surf Endosc* 2015;29:844-50.
15. Oka S, Tanaka S, Takata S, et al. Clinical usefulness of narrow band imaging magnifying classification for colorectal tumors based on both surface pattern and microvessel features. *Dig Endosc* 2011;23:101-5.
16. Hirata I, Nakagawa Y, Ohkubo M, et al. Usefulness of magnifying narrow-band imaging endoscopy for the diagnosis of gastric and colorectal lesions. *Digestion* 2012;85:74-9.
17. Tanaka S, Sano Y. Aim to unify the narrow band imaging (NBI) magnifying classification for colorectal tumors: current status in Japan from a summary of the consensus symposium in the 79th annual meeting of the Japan Gastroenterological Endoscopy Society. *Dig Endosc* 2011;23: 131-9.
18. Hewett DG, Kaltenbach TR, Sano Y, et al. Validation of a simple classification system for endoscopic diagnosis of small colorectal polyps using narrow-band imaging. *Gastroenterology* 2012;143:599-607.
19. Hayashi N, Tanaka S, Hewett DG, et al. Endoscopic prediction of deep submucosal invasive carcinoma: validation of the narrow-band imaging international colorectal endoscopic (NICE) classification. *Gastrointest Endosc* 2013;78:625-32.
20. Hattori S, Iwatate M, Sano W, et al. Narrow-band imaging observation of colorectal lesions using NICE classification to avoid discarding significant lesions. *World J Gastrointest Endosc* 2014;6:600-5.
21. Oba S, Tanaka S, Oka S, et al. Characterization of colorectal tumors using narrow-band imaging magnification: combined diagnosis with both pit pattern and microvessel features. *Scand J Gastroenterol* 2010;45:1084-92.
22. Wani S, Rastogi A. Narrow-band imaging in the prediction for submucosal invasive colon cancer: how "NICE" is it? *Gastrointest Endosc* 2013;78:633-41.
23. Tanaka S, Hayashi N, Oka S, et al. Endoscopic assessment of colorectal cancer with superficial or deep submucosal invasion using magnifying colonoscopy. *Clin Endosc* 2013;46:128-46.
24. Sano Y, Tanaka S, Kudo SE, et al. NBI magnifying endoscopic classification of colorectal tumors proposed by the Japan NBI Expert Team (JNET). *Dig Endosc* 2016;28:526-33.
25. Boman FT, Carneiro F, Hruban RH, et al. WHO classification of tumours of the digestive system, 4th ed Lyon, France: IARC; 2010.
26. Pohl H, Robertson DJ. Confidence with narrow band imaging: Will it change our practice of polyp resection? *Gastroenterology* 2009;136: 1149-51.
27. Rex DK, Kahi CJ, O'Brien M, et al. The American Society for Gastrointestinal Endoscopy PIVI (Preservation and Incorporation of Valuable Endoscopic Innovations) on real-time endoscopic assessment of the histology of diminutive colorectal polyps. *Gastrointest Endosc* 2011;73:419-22.
28. Lieberman DA, Rex DK, Winawer AJ, et al. Guidelines for colonoscopy surveillance after screening and Polypectomy: A Consensus update by the US Multi-Society Task Force on Colorectal Cancer. *Gastroenterology* 2012;143:844-57.
29. Ignjatovic A, East JE, Suzuki N, et al. Optical diagnosis of small colorectal polyps at routine colonoscopy (Detect Inspect Characterize Resect and Discard; DISCARD trial): a prospective cohort study. *Lancet Oncol* 2009;10:1171-8.
30. Hassan C, Pickhardt PJ, Rex DK, et al. A resect and discard strategy would improve cost-effectiveness of colorectal cancer screening. *Clin Gastroenterol Hepatol* 2010;8:865-86.
31. Rex DK. Real-time endoscopic pathology assessment of colorectal polyps. *Curr Gastroenterol Rep* 2013;15:354.
32. Takeuchi Y, Hanafusa M, Kanzaki H, et al. An alternative option for "resect and discard" strategy, using magnifying narrow-band imaging: a prospective "proof-of-principle" study. *J Gastroenterol* 2015;50: 1017-26.
33. Rex DK, et al. Narrow-band imaging without optical magnification for histologic analysis of colorectal polyps. *Gastroenterology* 2008;136: 1174-81.
34. Hewett DG, Huffman ME, Rex DK, et al. Leaving distal colorectal hyperplastic polyps in place can be achieved with high accuracy by using narrow-band imaging: an observational study. *Gastrointest Endosc* 2012;76:374-80.
35. Rex DK, Clodfelter R, Rahmani F, et al. Narrow-band imaging versus white light for detection of proximal colon serrated lesions: a randomized, controlled trial. *Gastrointest Endosc* 2016;83:166-71.
36. Raghavendra M, Hewett DG, Rex DK, et al. Differentiating adenomas from hyperplastic colorectal polyps: narrow-band imaging can be learned in 20 minutes. *Gastrointest Endosc* 2010;72:572-6.
37. Tanaka S, Kaltenbach T, Chayama K, et al. High-magnification colonoscopy. *Gastrointest Endosc* 2006;64:604-13.
38. Iwatate M, Sano Y, Hattori S, et al. The addition of high magnifying endoscopy improves rates of high confidence optical diagnosis of colorectal polyps. *Endosc Int Open* 2015;3:140-5.
39. Singh R, Nordeen N, Mei Y, et al. West meets east: preliminary results of narrow band imaging with optical magnification in the diagnosis of colorectal lesions: a multicenter Australian study using the modified Sano's classification. *Dig Endosc* 2011;23:126-30.
40. Kaltenbach TR, Restogi A, Rouse RV, et al. Real-time optical diagnosis for diminutive colorectal polyps using narrow-band imaging: the VALID randomized clinical trial. *Gut* 2015;64:1569-77.
41. Hayashi N, Tanaka S, Kanao H, et al. Relationship between narrow-band imaging magnifying observation and pit pattern diagnosis in colorectal tumors. *Digestion* 2013;87:53-8.
42. East JE, Suzuki N, Saunders BP, et al. Comparison of magnified pit pattern interpretation with narrow band imaging versus chromoendoscopy for diminutive colonic polyps: a pilot study. *Gastrointest Endosc* 2007;66:310-6.
43. Sakamoto T, Saito Y, Nakajima T, et al. Comparison of magnifying chromoendoscopy and narrow-band imaging in estimation of early colorectal cancer invasion depth: a pilot study. *Dig Endosc* 2011;23: 118-23.



Diagnostic performance of Japan NBI Expert Team classification for differentiation among noninvasive, superficially invasive, and deeply invasive colorectal neoplasia

Kyoku Sumimoto, MD,¹ Shinji Tanaka, MD, PhD,² Kenjiro Shigita, MD,¹ Nana Hayashi, MD, PhD,² Daiki Hirano, MD,¹ Yuzuru Tamaru, MD,¹ Yuki Ninomiya, MD,¹ Shiro Oka, MD, PhD,² Koji Arihiro, MD, PhD,³ Fumio Shimamoto, MD, PhD,⁴ Masaharu Yoshihara, MD, PhD,⁵ Kazuaki Chayama, MD, PhD¹

Hiroshima, Japan

Backgrounds and Aims: The Japan NBI Expert Team (JNET) classification is the first universal narrow-band imaging magnifying endoscopic classification of colorectal tumors. Considering each type in this classification, the diagnostic ability of Type 2B is the weakest. Generally, clinical behavior is believed to be different in each gross type of colorectal tumor. We evaluated the differences in the diagnostic performance of JNET classification for each gross type (polypoid and superficial) and examined whether the diagnostic performance of Type 2B could be improved by subtyping.

Methods: We analyzed 2933 consecutive cases of colorectal lesions, including 136 hyperplastic polyps/sessile serrated polyps, 1926 low-grade dysplasias (LGDs), 571 high-grade dysplasias (HGDs), and 300 submucosal (SM) carcinomas. We classified lesions as polypoid and superficial type and compared the diagnostic performance of the classification system in each type. Additionally, we subtyped Type 2B into 2B-low and 2B-high based on the level of irregularity in surface and vessel patterns, and we evaluated the relationship between the subtypes and histology, as analyzed separately for polypoid and superficial types. We also estimated interobserver and intraobserver variability.

Results: The diagnostic performance of JNET classification did not differ significantly between polypoid and superficial lesions. Ninety-nine percent of Type 2B-low lesions were LGDs, HGDs, or superficial submucosal invasive (SM-s) carcinomas. In contrast, 60% of Type 2B-high lesions were deep submucosal invasive (SM-d) carcinomas. The results were not different between each gross type. Interobserver and intraobserver agreements for Type 2B subtyping were good, with kappa values of .743 and .786, respectively.

Conclusions: Type 2B subtyping may be useful for identifying lesions that are appropriate for endoscopic resection. JNET classification and Type 2B sub classification are useful criteria, regardless of gross type. (Gastrointest Endosc 2017;86:700-9.)

Abbreviations: HGD, high-grade dysplasia; HP, hyperplastic polyp; JNET, Japan NBI Expert Team; LGD, low-grade dysplasia; NBI, narrow-band imaging; NICE classification, NBI International Colorectal Endoscopic classification; SM-d carcinoma, deep submucosal invasive carcinoma; SM-s carcinoma, superficial submucosal invasive carcinoma; SSP, sessile serrated polyp.

DISCLOSURE: All authors disclosed no financial relationships relevant to this publication. Research support for this study was provided to Shinji Tanaka by a Grant-in-Aid from the Japan Agency for Medical Research and Development, AMED (15ck0106102b0102).

Copyright © 2017 by the American Society for Gastrointestinal Endoscopy 0016-5107/\$36.00

<http://dx.doi.org/10.1016/j.gie.2017.02.018>

Received August 20, 2016. Accepted February 16, 2017.

Current affiliations: Department of Gastroenterology and Metabolism (1), Department of Endoscopy (2), Department of Anatomical Pathology (3), Hiroshima University Hospital, Hiroshima, Japan; Department of Human Sciences, Faculty of Humanities and Human Sciences, Hiroshima Shudo University, Hiroshima, Japan (4), Health Service Center, Hiroshima University, Hiroshima, Japan (5).

Reprint requests: Shinji Tanaka, MD, PhD, Department of Endoscopy, Hiroshima University Hospital, 1-2-3 Kasumi, Minami-ku, Hiroshima 734-8551, Japan.



Use your mobile device to scan this QR code and watch the author interview. Download a free QR code scanner by searching "QR Scanner" in your mobile device's app store.

The narrow-band imaging (NBI) system has been used widely to diagnose GI neoplasia since it was first developed in 1999 in Japan.^{1,2} Many reports have confirmed that NBI observation is useful for detecting colorectal tumors,³⁻⁵ differentiating between neoplastic and non-neoplastic colorectal lesions,^{6,7} and diagnosing the invasive depth of colorectal carcinomas.^{2,8-10} As such, NBI classifications have become an important and necessary modality for daily colonoscopic examinations. In 2009, the Colon Tumor NBI Interest Group (CTNIG) proposed an NBI classification for colorectal tumors, the NBI International Colorectal Endoscopic (NICE) classification.¹¹⁻¹³ NICE classification was the first classification for colon tumors that could be applied with or without magnifying observation.¹⁴ Because of its simplicity and usefulness, NICE classification spread rapidly in Western countries, where NBI magnification had not yet become common.^{9,15}

In Japan, many NBI magnifying classifications for colon tumors were used, such as Hiroshima classification,¹⁶⁻¹⁹ Sano classification,^{20,21} Showa classification,²² and Jikei classification,²³ each used at different facilities. To unify the classifications, a committee of 38 magnifying colonoscopy specialists in Japan, the Japan NBI Expert Team (JNET), was organized in 2011. In 2014 JNET proposed the first unified colorectal NBI magnifying classification, the JNET classification.²⁴ The JNET classification is composed of 4 types, types 1, 2A, 2B, and 3, and 2 NBI magnifying findings, surface pattern and vessel pattern. Types 1, 2A, 2B, and 3 are intended to indicate the most likely histology. Type 1 refers to hyperplastic polyps (HPs) and sessile serrated polyps (SSPs). Type 2A refers to low-grade dysplasias (LGDs), such as tubular adenomas or tubulovillous adenomas. Type 2B refers to high-grade dysplasias (HGDs) and superficial submucosal invasive (SM-s) carcinomas. Type 3 refers to deep submucosal invasive (SM-d) carcinomas. As we have previously reported, Types 1, 2A, and 3 are highly reliable indicators for their respective most likely histology, with significant qualitative and quantitative accuracy.²⁵ On the other hand, the ability of Type 2B to indicate HGD and SM-s carcinoma is weaker than the abilities of the other 3 types, because Type 2B contains lesions with a variety of histology, ranging from LGD to SM-d carcinoma. Although a variety of gross types of colorectal tumors exhibit different clinical behaviors in terms of growth or invasion,^{26,27} differences in the diagnostic performance of the JNET classification have not been reported according to gross type. This study aimed to evaluate the diagnostic performance of the JNET classification for each gross type of lesion and to determine whether further subtyping of Type 2B could improve diagnostic performance.

METHODS

This study included 2933 consecutive cases of colorectal lesions that had been endoscopically or surgically

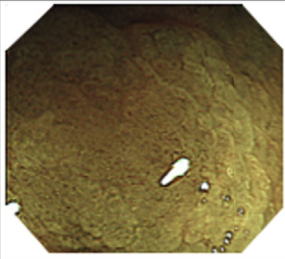
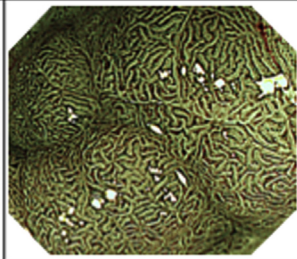


resected. A total of 1901 patients were enrolled; 1351 patients (71.1%) had 1 lesion, 314 patients (16.5%) had 2 lesions, 132 patients (6.9%) had 3 lesions, and 104 patients (5.5%) had 4 or more lesions. All lesions were assumed to be independent observations for the purpose of statistical analysis. Each case was examined by NBI magnifying observation at the Department of Endoscopy of Hiroshima University Hospital between January 2011 and March 2015. Based on their histologic characteristics, 2933 lesions were identified as follows: 136 HP/SSP lesions, 1926 LGD lesions, 571 HGD lesions, 87 SM-s carcinoma lesions, and 213 SM-d carcinoma lesions. The mean diameters (standard deviations) of the HP/SSP, LGD, HGD, SM-s carcinoma, and SM-d carcinoma lesions were 8.9 (7.6) mm, 11.4 (10.7) mm, 25.7 (17.3) mm, 25.1 (13.9) mm, and 26.0 (14.3) mm, respectively.

The NBI criteria for each type from the JNET classification are described in Figure 1. Type 1 lesions are characterized by an invisible vessel pattern with dark and white spots as the surface pattern. Type 2A lesions are characterized by a regular vessel pattern, such as a regular caliber or distribution, and a regular surface pattern. Type 2B lesions are characterized by an irregular vessel pattern, such as a variable caliber or irregular distribution, with an irregular or obscure surface pattern. Type 3 lesions are characterized by loose vessel areas or interruption of thick vessels and an amorphous surface pattern.

First, we evaluated the diagnostic performance of each JNET type in terms of its ability to predict the most likely histology. To compare differences in diagnostic accuracy between each gross type, we classified the lesions as polypoid or superficial according to the Paris classification and then evaluated the diagnostic performance for each group.²⁸ To evaluate the diagnostic ability as an indicator of the most likely histology, we calculated sensitivity, specificity, positive and negative predictive values, and accuracy for each type of JNET classification. Histologic findings of the colorectal lesions were used as the standard against which the optical predictions were validated.

Second, we subclassified 799 consecutive Type 2B lesions into 2B-low and 2B-high subtypes. We used blinded NBI magnifying endoscopic images and arrived at a diagnosis retrospectively, based on the levels of irregularity in the vessel and surface patterns. Type 2B-low lesions exhibited uniform thickness and a uniform distribution of irregular vessels, an irregularity in the network of the pit-like pattern, and a smooth margin of the pit-like structure without ravage. Type 2B-high lesions exhibited heterogeneous diameters and/or distributions of irregular vessels, an irregular and destroyed pit-like pattern, and an irregular, fluffing, unclear margin of the pit-like structure (Fig. 2). We evaluated the relationships between each of the Type 2B subtypes and histology

Japanese NBI Expert Team (JNET) classification

NBI	Type 1	Type 2A	Type 2B	Type 3
Vessel pattern	• Invisible ^{#1}	• Regular caliber • Regular distribution ^{#2} (meshed/spiral pattern)	• Variable caliber • Irregular distribution	• Loose vessel areas • Interruption of thick vessels
Surface pattern	• Regular dark or white spots • Similar to surrounding normal mucosa	• Regular (tubular/branched/papillary)	• Irregular or obscure	• Amorphous areas
Most likely histology	Hyperplastic polyp/ Sessile serrated polyp	Low-grade intramucosal neoplasia ^{#4}	High-grade intramucosal neoplasia/ Superficial ^{#3} submucosal invasive cancer ^{#5}	Deep submucosal invasive cancer
Examples				

- * 1. If visible, the caliber in the lesion is similar to surrounding normal mucosa.
- * 2. Microvessels are often distributed in a punctate pattern and well-ordered reticular or spiral vessels may not be observed in depressed lesions.
- * 3. Deep submucosal invasive cancer may be included.
- * 4. Low-grade intramucosal neoplasia: low-grade dysplasia.
- * 5. High-grade intramucosal neoplasia: high-grade dysplasia.

Figure 1. The Japan NBI Expert Team classification (narrow-band imaging [NBI] magnifying classification for colorectal neoplasia).

results. Interobserver and intraobserver variabilities were estimated. The relationships between the Type 2B subtypes and histology results were also examined for each gross type.

To evaluate the NBI magnifying images, the lesions were diagnosed according to the JNET classification by 3 proficient endoscopists, each of whom had at least 5 years of experience using NBI. The endoscopists were blinded to all clinical information on the lesions that was related to the standard endoscopic images and histology results. They arrived at the diagnoses based on the NBI magnifying images alone. Interobserver variability for the Type 2B subtyping was analyzed for the 3 endoscopists and the kappa value calculated. Of the 799 cases that were diagnosed as Type 2B, the analysis of interobserver and intraobserver variability used the 216 consecutive cases that were detected by colonoscopy between January 2014 and November 2014. We used the NBI magnifying still images with 1 image per lesion. Two weeks after making the first diagnosis, and without undergoing any specific training for NBI diagnosis during that time, 1 of 3 participating endoscopists was presented with the NBI magnifying images from the same 216 cases in a different order. To analyze intraobserver variability, she then subclassified them

again, while remaining blinded to the results from the first trial.

The colonoscope used in this study was a magnifying videoendoscope (CF-H260AZI and CF-HQ290ZI; Olympus Optical, Tokyo, Japan). The maximum magnification level in this study was approximately 70-fold for each scope. Histologic diagnosis was performed in accordance with the World Health Organization criteria by a pathologist (F. S.) who was blinded to the clinical information.²⁹ The depth of SM invasion was defined according to the 2014 Japanese Society for Cancer of the Colon and Rectum guidelines for the treatment of colorectal cancer.³⁰ This study was conducted with full approval from the Ethics Committee of Hiroshima University Hospital.

Statistical analysis

The kappa values for interobserver and intraobserver agreement were interpreted as follows: poor, .00 to .20; fair, .21 to .40; moderate, .41 to .60; substantial, .61 to .80; and excellent, .81 to 1.00.³¹ Kappa values provide a measure of the agreement that is present, above and beyond that which would be expected from chance alone. A kappa value of 1.00 indicates perfect agreement, a value of .00 indicates no more agreement than would

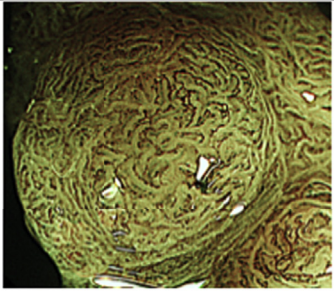
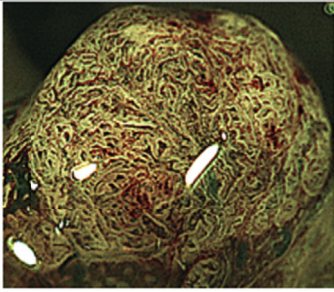
NBI	Type 2B	
	2B-low	2B-high
Vessel pattern	<ul style="list-style-type: none"> The thickness and distribution of irregular vessels are uniform. 	<ul style="list-style-type: none"> The diameter and/or distribution of irregular vessels are heterogeneous.
Surface pattern	<ul style="list-style-type: none"> Irregularity in the pit-like pattern network Smooth pit-like structure margin without ravaging 	<ul style="list-style-type: none"> Irregular and destroyed pit-like pattern Irregular, fluffing, and unclear pit-like structure margin
Examples		

Figure 2. Subtyping of Japan NBI Expert Team Type 2B. *NBI*, Narrow-band imaging.

be expected by chance alone, and a negative value indicates less agreement than would be expected from chance alone. Differences in nominal variables were analyzed using the Fisher exact test. $P < .05$ was considered statistically significant. JMP version 10.0 (SAS Institute, Cary, NC) was used for all statistical analysis. Although there was multiple testing of outcome data arising from individual lesions, no corrections to the P values were made because the purpose of the research was to highlight any potential differences.

RESULTS

Relationships between the JNET classification and histologic findings for each gross type

The results of NBI magnifying endoscopic diagnoses for all 2933 lesions using the JNET classification are shown in [Table 1](#). According to the Paris classification, 2114 of the 2933 lesions were categorized as polypoid lesions (0-Is and 0-Ip) and the remaining 819 as superficial lesions (0-IIa, 0-IIb, and 0-IIc).

The 2114 polypoid-type lesions consisted of 57 HP/SSP lesions, 1435 LGD lesions, 431 HGD lesions, 50 SM-s carcinoma lesions, and 141 SM-d carcinoma lesions ([Table 2](#)). Histologically, 98% (46/47) and 2% (1/47) of Type 1 lesions were identified as HP/SSP and LGD, respectively. One percent (11/1,460), 86% (1,253/1,460), and 14% (196/1,460) of Type 2A lesions were identified as HP/SSP, LGD, and HGD/SM-s carcinoma, respectively. Thirty-four percent (181/531), 54% (283/531), and 13% (67/531) of Type 2B lesions were identified as LGD,

HGD/SM-s carcinoma, and SM-d carcinoma, respectively. Three percent (2/76) and 97% (74/76) of Type 3 lesions were identified as SM-s carcinoma and SM-d carcinoma, respectively.

The 819 superficial-type lesions consisted of 79 HP/SSP lesions, 491 LGD lesions, 140 HGD lesions, 37 SM-s carcinoma lesions, and 72 SM-d carcinoma lesions ([Table 3](#)). Histologically, 97% (73/75) and 3% (2/75) of Type 1 lesions were identified as HP/SSP and LGD, respectively. One percent (6/428), 87% (373/428), and 12% (49/428) of Type 2A lesions were identified as HP/SSP, LGD, and HGD/SM-s carcinoma, respectively. Forty-three percent (116/268), 47% (124/268), and 10% (28/268) of Type 2B lesions were identified as LGD, HGD/SM-s carcinoma, and SM-d carcinoma, respectively. Eight percent (4/48) and 92% (44/48) of Type 3 lesions were identified as HGD/SM-s carcinoma and SM-d carcinoma, respectively. The relationships of the JNET classifications and their respective most likely histologic findings for both polypoid lesions and superficial lesions are shown in [Table 4](#). No significant difference was observed for any types in the JNET classification ($P > .5$).

Performance characteristics of the JNET classification for each gross type

The sensitivity, specificity, positive predictive value, negative predictive value, and accuracy of the Type 1 classification as a means of diagnosing HP/SSP were 80.7%, 100.0%, 97.9%, 99.5%, and 99.4% for polypoid lesions and 92.4%, 99.7%, 97.3%, 99.2%, and 99.0% for superficial lesions, respectively. The corresponding values for the

TABLE 1. The relationship between the JNET classification and histologic findings in colorectal lesion

JNET classification	n, (%)	Histologic findings				
		HP/SSP	LGD	HGD	Carcinoma	
					SM-s	SM-d
Type 1	122 (100)	119 (98)	3 (2)			
Type 2A	1888 (100)	17 (1)	1626 (86)	230 (12)	15 (1)	
Type 2B	799 (100)		297 (37)	340 (43)	67 (8)	95 (12)
Type 3	124 (100)			1 (1)	5 (4)	118 (95)
Total	2933	136	1926	571	87	213

JNET, Japan NBI Expert Team; HP, hyperplastic lesion; SSP, sessile serrated polyp; LGD, low-grade dysplasia; HGD, high-grade dysplasia; SM-s, superficial submucosal invasive carcinoma (<1000 μm); SM-d, deep submucosal invasive carcinoma (≥1000 μm).

TABLE 2. Relationship between the JNET classification and histologic findings for polypoid colorectal lesion

JNET classification	n, (%)	Histologic findings				
		HP/SSP	LGD	HGD	Carcinoma	
					SM-s	SM-d
Type 1	47 (100)	46 (98)	1 (2)			
Type 2A	1460 (100)	11 (1)	1253 (86)	184 (13)	12 (1)	
Type 2B	531 (100)		181 (34)	247 (47)	36 (7)	67 (13)
Type 3	76 (100)				2 (3)	74 (97)
Total	2114	57	1435	431	50	141

JNET, Japan NBI Expert Team; HP, hyperplastic lesion; SSP, sessile serrated polyp; LGD, low-grade dysplasia; HGD, high-grade dysplasia; SM-s, superficial submucosal invasive carcinoma (<1000 μm); SM-d, deep submucosal invasive carcinoma (≥1000 μm).

TABLE 3. Relationship between the JNET classification and histologic findings for superficial colorectal lesion

JNET classification	n, (%)	Histologic findings				
		HP/SSP	LGD	HGD	Carcinoma	
					SM-s	SM-d
Type 1	75 (100)	73 (97)	2 (3)			
Type 2A	428 (100)	6 (1)	373 (87)	46 (11)	3 (1)	
Type 2B	268 (100)		116 (43)	93 (35)	31 (12)	28 (10)
Type 3	48 (100)			1 (2)	3 (6)	44 (92)
Total	819	79	491	140	37	72

JNET, Japan NBI Expert Team; HP, hyperplastic lesion; SSP, sessile serrated polyp; LGD, low-grade dysplasia; HGD, high-grade dysplasia; SM-s, superficial submucosal invasive carcinoma (<1000 μm); SM-d, deep submucosal invasive carcinoma (≥1000 μm).

Type 2A classification as a means of diagnosing LGD were 77.0%, 90.7%, 98.4%, 34.4%, and 77.1% for polypoid lesions and 66.4%, 95.2%, 97.9%, 45.9%, and 73.0% for superficial lesions, respectively. Further, the corresponding values for the Type 2B classification as a means of diagnosing HGD or SM-s carcinoma were 58.8%, 84.8%, 53.3%, 87.5%, and 78.9% for polypoid lesions and 70.1%, 77.6%, 46.3%, 90.4%, and 76.0% for superficial lesions, respectively. Finally, the sensitivity, specificity, positive predictive value, negative predictive value, and accuracy of the Type 3 categorization as a means of diagnosing SM-d carcinoma were 52.5%, 99.7%, 92.5%, 96.7%, and 96.5% for polypoid lesions and 61.1%, 99.5%, 91.7%,

96.4%, and 96.1% for superficial lesions, respectively (Table 5).

Relationships between the JNET classification with Type 2B subtyping and histologic findings for all colorectal lesions

The 799 Type 2B lesions were subclassified into 656 Type 2B-low lesions and 143 Type 2B-high lesions (Table 6). Histologically, the 656 Type 2B-low lesions consisted of 297 LGDs (45%), 351 HGDs/SM-s carcinomas (54%), and 8 SM-d carcinomas (1%), whereas the 143 Type 2B-high lesions consisted of 56 HGDs/SM-s carcinomas (39%) and 87 SM-d carcinomas (61%).

TABLE 4. Relationship between the JNET classification and histologic findings in polypoid type and superficial type

JNET classification	Gross type	Histologic findings(%)		P value*
		HP/SSP	Non-HP/SSP	
Type 1	Polypoid	46 (98)	1 (2)	1.000
	Superficial	73 (97)	2 (3)	
Type 2A	Polypoid	1253 (86)	207 (14)	.485
	Superficial	373 (87)	55 (13)	
Type 2B	Polypoid	263 (54)	248 (46)	.061
	Superficial	124 (47)	144 (53)	
Type 3	Polypoid	74 (97)	2 (3)	.312
	Superficial	44 (92)	4 (8)	

JNET, Japan NBI Expert Team; HP, hyperplastic lesion; SSP, sessile serrated polyp; LGD, low-grade dysplasia; HGD, high-grade dysplasia; SM-s, superficial submucosal invasive carcinoma (<1000 μm); SM-d, deep submucosal invasive carcinoma (≥1000 μm).

* χ^2 test.

TABLE 5. Performance characteristics of JNET classification in each gross type

JNET classification	Gross type	Sensitivity	Specificity	Positive predictive value	Negative predictive value	Accuracy
Type 1	All	87.5 (81.9-93.1)	99.9 (99.8-100.0)	97.5 (94.8-100.3)	99.4 (99.1-99.7)	99.3 (99.0-99.6)
	Polypoid	80.7 (70.5-90.9)	100.0 (99.9-100.0)	97.9 (93.7-102.0)	99.5 (99.2-99.8)	99.4 (99.1-99.8)
	Superficial	92.4 (86.6-98.2)	99.7 (99.4-100.1)	97.3 (93.7-101.0)	99.2 (98.6-99.8)	99.0 (98.4-99.7)
Type 2A	All	74.3 (72.6-76.0)	92.7 (90.2-95.1)	98.3 (97.7-98.9)	38.7 (35.7-41.6)	77.1 (75.5-78.6)
	Polypoid	77.0 (75.1-78.9)	90.7 (87.1-94.3)	98.4 (97.8-99.1)	34.4 (30.8-38.0)	77.1 (75.5-78.6)
	Superficial	66.4 (62.7-70.1)	95.2 (92.2-98.3)	97.9 (96.5-99.3)	45.9 (41.0-50.9)	73.0 (70.0-76.1)
Type 2B	All	61.9 (58.1-65.6)	82.8 (81.2-84.3)	50.9 (47.5-54.4)	88.2 (86.9-89.6)	78.1 (76.6-79.6)
	Polypoid	58.8 (54.4-63.2)	84.8 (83.1-86.6)	53.3 (49.1-57.5)	87.5 (85.9-89.1)	78.9 (77.2-80.6)
	Superficial	70.1 (63.3-76.8)	77.6 (74.4-80.8)	46.3 (40.3-52.2)	90.4 (87.9-92.9)	76.0 (73.1-78.9)
Type 3	All	55.4 (48.7-62.1)	99.8 (99.6-100.0)	95.2 (91.4-98.9)	96.6 (95.9-97.3)	96.6 (95.9-97.2)
	Polypoid	52.5 (44.2-60.7)	99.7 (99.5-99.9)	92.5 (86.7-98.3)	96.7 (95.9-97.5)	96.5 (95.8-97.3)
	Superficial	61.1 (49.9-72.4)	99.5 (98.9-100.0)	91.7 (83.8-99.5)	96.4 (95.1-97.7)	96.1 (94.8-97.4)

Values are percents with 95% confidence intervals in parentheses.

JNET, Japan NBI Expert Team; NBI, narrow-band imaging.

The overall interobserver agreement for Type 2B subtyping among the 3 endoscopists was good, with a kappa value of .743 (95% confidence interval, .671-.823). The intraobserver agreement was also good for the endoscopist who was evaluated, with a kappa value of .786 (95% confidence interval, .691-.884).

Relationships between the JNET classification with Type 2B subtyping and histologic findings for colorectal lesions of each gross type

Of the 799 Type 2B lesions, 531 were polypoid type and 268 were superficial type. The 531 polypoid lesions of Type 2B were subclassified into 437 Type 2B-low lesions and 94 Type 2B-high lesions (Table 7). Histologically, the

437 Type 2B-low lesions consisted of 181 LGDs (41%), 248 HGDs/SM-s carcinomas (57%), and 8 SM-d carcinomas (2%), whereas the 94 Type 2B-high lesions consisted of 35 HGDs/SM-s carcinomas (37%) and 59 SM-d carcinomas (63%). The 268 superficial lesions of Type 2B were subclassified into 219 Type 2B-low lesions and 49 Type 2B-high lesions (Table 8). Histologically, the 219 Type 2B-low lesions consisted of 116 LGDs (53%) and 103 HGDs/SM-s carcinomas (47%), whereas the 49 Type 2B-high lesions consisted of 21 HGDs/SM-s carcinomas (43%) and 28 SM-d carcinomas (57%). There was no significant difference in the relationship of Type 2B subtyping and histologic findings between polypoid lesions and superficial lesions, although a nearly significant difference

TABLE 6. Relationship between the JNET classification with subtyping of Type 2B and histologic findings in colorectal lesion

JNET classification	n, (%)	Histologic findings				
		HP/SSP	LGD	HGD	Carcinoma	
					SM-s	SM-d
Type 2B-low	656 (100)		297 (45)	321 (49)	30 (5)	8 (1)
Type 2B-high	143 (100)			19 (13)	37 (26)	87 (61)
Total	799	0	297	430	67	95

JNET, Japan NBI Expert Team; HP, hyperplastic lesion; SSP, sessile serrated polyp; LGD, low-grade dysplasia; HGD, high-grade dysplasia; SM-s, superficial submucosal invasive carcinoma (<1000 µm); SM-d, deep submucosal invasive carcinoma (≥1000 µm).

TABLE 7. Relationship between the JNET classification with subtyping of Type 2B and histologic findings in polypoid colorectal lesion

JNET classification	n, (%)	Histologic findings				
		HP/SSP	LGD	HGD	Carcinoma	
					SM-s	SM-d
Type 2B-low	437 (100)		181 (41)	232 (53)	16 (4)	8 (2)
Type 2B-high	94 (100)			15 (16)	20 (21)	59 (63)
Total	531	0	181	247	36	67

JNET, Japan NBI Expert Team; HP, hyperplastic lesion; SSP, sessile serrated polyp; LGD, low-grade dysplasia; HGD, high-grade dysplasia; SM-s, superficial submucosal invasive carcinoma (<1000 µm); SM-d, deep submucosal invasive carcinoma (≥1000 µm).

was observed for Type 2B-low lesions ($P = .0571$ for type 2B-low and $P = .589$ for type 2B-high; Table 9).

DISCUSSION

In general, there is a consensus in Japan that LGD, HGD, and SM-s carcinoma are considered to be appropriate for endoscopic resection.^{32,33} Additionally, SM-d carcinoma should be surgically resected because of the possibility of lymph node metastasis. As a principle, en bloc resection is essential for carcinoma to obtain a precise histologic diagnosis.^{33,34} Detailed histologic information can only be acquired from a complete specimen, and having this information enables us to make decisions regarding the curability and the necessity of additional surgical treatment in each case.^{35,36} Because HGD (which is generally regarded as an intramucosal carcinoma in Japan) can potentially invade the submucosal layer, both HGD and SM-s carcinoma require an en bloc resection technique, such as endoscopic mucosal resection (EMR) or endoscopic submucosal dissection (ESD).^{32,37,38} Unlike carcinoma, LGD can be treated not only using en bloc EMR or ESD but instead using piecemeal EMR to achieve a complete cure.³² For carcinoma within an adenomatous component, the cancerous area—if it can be detected in advance—should be carefully resected en bloc to obtain a precise histologic diagnosis, and fragmentation is allowed for the noncancerous area (this is so-called planned piecemeal EMR).³⁹⁻⁴² Thus, the treatment

methods that are adequate for each lesion differ based on their histologic features.³³ In this way, a precise optical diagnosis before treatment is very important for selecting an adequate treatment procedure, such as piecemeal EMR, en bloc endoscopic resection (en bloc EMR/ESD), or surgery.^{43,44}

Regarding the JNET Type 2B subtyping, about 80% of Type 2B lesions were classified as Type 2B-low. Further, the large majority of the Type 2B-low lesions were LGD, HGD, or SM-s carcinoma. Because almost all Type 2B-low lesions were LGD, HGD, or SM-s carcinoma, Type 2B-low can be regarded as a reliable indicator for endoscopic resection when examining the various histologic types of Type 2B cases. On the other hand, about 60% of Type 2B-high lesions were SM-d carcinoma, which requires surgery, whereas the remaining lesions were HGD or SM-s carcinoma. This finding suggests that Type 2B-high is not a reliable indicator for surgery. Thus, for Type 2B-low lesions, which comprise about 80% of Type 2B lesions, endoscopic treatment can be a first choice in the therapeutic strategy process. For Type 2B-high lesions, because they alone cannot be identified with SM-d carcinoma, further examination is necessary to differentiate HGD and SM-s carcinoma from SM-d carcinoma, thereby avoiding unnecessary surgery. To determine the appropriate treatment method (endoscopic resection or surgery) for Type 2B-high lesions, pit pattern diagnosis using chromoagents^{45,46} or endoscopic ultrasonography^{47,48} is necessary to diagnose the correct invasion depth. However, no additional examination is necessary for Type 2B-low lesions

TABLE 8. Relationship between the JNET classification with subtyping of type 2B and histologic findings in superficial colorectal lesion

JNET classification	n, (%)	Histologic findings				
		HP/SSP	LGD	HGD	Carcinoma	
					SM-s	SM-d
Type 2B-low	219 (100)		116 (53)	89 (41)	14 (6)	
Type 2B-high	49 (100)			4 (8)	17 (35)	28 (57)
Total	268	0	116	93	31	28

JNET, Japan NBI Expert Team; HP, hyperplastic lesion; SSP, sessile serrated polyp; LGD, low-grade dysplasia; HGD, high-grade dysplasia; SM-s, superficial submucosal invasive carcinoma (<1000 μ m); SM-d, deep submucosal invasive carcinoma (\geq 1000 μ m).

TABLE 9. Relationship between the JNET classification with subtyping of Type 2B and histologic findings in polypoid type and superficial type

JNET classification	Gross type	n (100)	Histologic findings		P value
			LGD SM-s (%)	SM-d (%)	
Type 2B-low	Polypoid	437 (100)	429 (98)	8 (2)	.0571
	Superficial	219 (100)	219 (100)	0 (0)	
Type 2B-high	Polypoid	94 (100)	35 (37)	59 (63)	.5890
	Superficial	49 (100)	21 (43)	28 (57)	
Total		799	704	95	

JNET, Japan NBI Expert Team; LGD, low-grade dysplasia; SM-s, superficial submucosal invasive carcinoma (<1000 μ m); SM-d, deep submucosal invasive carcinoma (\geq 1000 μ m).

because most of these are appropriate for endoscopic resection (Fig. 3). The fact that nearly 80% of Type 2B lesions (subtyped in Type 2B-low) can be selected for the appropriate treatment method by NBI magnifying endoscopy alone provides simplicity, efficiency, and cost benefits for the management of Type 2B lesions in daily colonoscopic practice.

Regarding the variability of Type 2B subtyping, both interobserver and intraobserver agreements were good. Type 2B subtyping may be performed as easily as the JNET classification in clinical practice. Of course, if there is low confidence in the diagnosis for any lesion or if the lesion is difficult to subclassify into either Type 2B-low or 2B-high, then another examination should be performed in addition to NBI magnification to arrive at a diagnosis with high confidence.

The JNET classification is an NBI magnifying endoscopic classification of colorectal tumors, the essence of which was based on the NICE classification. JNET Type 1 and 3 correspond to NICE Type 1 and 3, respectively. Additionally, JNET Type 2A and 2B correspond to the NICE Type 2 subclassification.²⁴ The findings of color that are used in the NICE classification are unnecessary for the JNET classification because magnification does not estimate color. Using fine NBI magnification, we have found it to be possible to differentiate LGD (JNET Type 2A) from HGD/SM-s carcinoma (JNET Type 2B), both of which had been classified as NICE Type 2 lesions. As we reported previously, JNET Type 1, 2A, and 3 are highly reliable indicators of

HP/SSP, LGD, and SM-d carcinoma, respectively. On the other hand, the ability of JNET Type 2B as a means of diagnosing HGD and SM-s carcinoma is lower than the abilities of the other 3 types because of a variety of histologies.²⁵ This is the reason we believed it was necessary to subtype Type 2B lesions, as a means of providing a more detailed optical diagnosis for these lesions.

In this study we also focused on the gross type of the lesions. Generally, colorectal tumors generally exhibit various gross types and growth patterns. The histologic characteristics and molecular biologic features are different for each gross type.^{26,27,49} Previously, we reported that the NBI magnifying findings differ according to growth pattern.⁵⁰ In this study we estimated the diagnostic performance of the JNET classification for polypoid lesions and superficial lesions separately. As shown in Results, there was no significant difference in overall diagnostic accuracy between the gross types. The sensitivities of each type seem to be different between polypoid lesions and superficial lesions. Note that overall diagnostic accuracy is a weighted average of sensitivity and specificity, with weights determined by the relative proportions of true positives and true negatives. As shown in Table 4, the specificity is high and there are mostly true negatives. Accordingly, the level of sensitivity may play a small role in determining the value of overall diagnostic accuracy. We expected no significant difference in the characteristics of the Type 2B subtype between the gross types as well as the

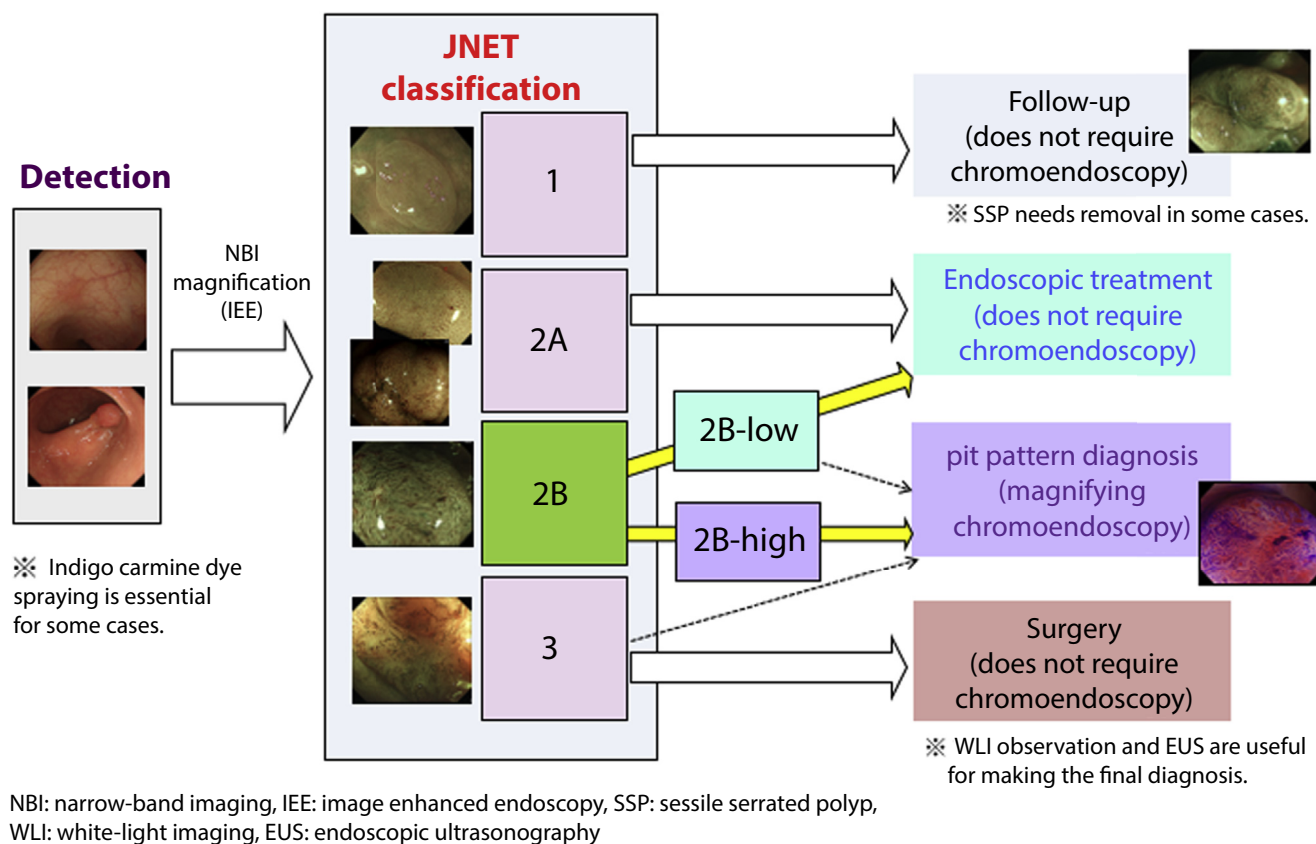


Figure 3. Strategy for treatment of colorectal lesions using Japan NBI Expert Team (JNET) type 2B subtype. With JNET classification, type 1 lesions, which are suspected as hyperplastic polyp/ sessile serrated polyp (SSP), could be followed up. (Some SSPs over 10-mm diameter need to be removed.) Type 2A lesions, which are suspected as low-grade dysplasia, should be removed by endoscopic treatment, and type 3 lesions, which are suspected as deep sub-mucosal invasive carcinoma, need surgical treatment. For type 2B lesions, we subclassify them into 2B-low and 2B-high. Almost type 2B-low lesions are indicative for endoscopic treatment, whereas type 2B-high lesions needs further examinations, such as magnifying chromoendoscopy or EUS, to make a precise invasion depth diagnose for selection of appropriate treatment method.

JNET classification. As shown in Table 9, the proportions of histologic findings for Type 2B-low lesions were almost significantly different between polypoid and superficial lesions, with a $P = .0571$. The reason for this near-statistically significant difference might be that no superficial SM-d carcinoma appeared to be JNET Type 2B-low. Generally, SM-d carcinomas correspond to JNET Type 3. Some advanced lesions of the polypoid type could have a slightly less irregular NBI appearance than Type 3 because the surface microvillous structure remains, which seldom happens to superficial advanced lesions. Thus, it can be suggested that the JNET classification, and also Type 2B subtyping, can be applied to high diagnostic accuracy for characterizing colorectal tumors (ie, as non-neoplasia vs dysplasia vs SM invasive carcinoma) for both polypoid lesion and superficial lesion.

In conclusion, regardless of the gross type, the JNET classification provides useful criteria for optical histologic diagnoses of colorectal lesions. Our proposal of Type 2B subtyping may improve the diagnostic performance of the JNET classification and contribute to daily colonoscopic practice.

REFERENCES

- Wallace MB, Crook JE, Coe S, et al. Accuracy of in vivo colorectal polyp discrimination by using dual-focus high-definition narrow-band imaging colonoscopy. *Gastrointest Endosc* 2014;80:1072-87.
- Kaltenbach T, Rex DK, Wilson A, et al. Implementation of optical diagnosis for colorectal polyps: standardization of studies is needed. *Clin Gastroenterol Hepatol* 2015;13:6-10.
- Horimatsu T, Sano Y, Tanaka S, et al. Next-generation narrow band imaging system for colonic polyp detection: a prospective multicenter randomized trial. *Int J Colorectal Dis* 2015;30:947-54.
- Utsumi T, Iwatate M, Sano W, et al. Polyp detection, characterization, and management using narrow-band imaging with/without magnification. *Clin Endosc* 2015;48:491-7.
- Rex DK, Clodfelter R, Rahmani F, et al. Narrow-band imaging versus white light for the detection of proximal colon serrated lesions: a randomized, controlled trial. *Gastrointest Endosc* 2016;83:166-71.
- Sakamoto T, Matsuda T, Aoki T, et al. Time saving with narrow-band imaging for distinguishing between neoplastic and non-neoplastic small colorectal lesions. *J Gastroenterol Hepatol* 2012;27:351-5.
- Leifeld L, Rogler G, Stallmach A, et al. White-light or narrow-band imaging colonoscopy in surveillance of ulcerative colitis: a prospective multicenter study. *Clin Gastroenterol Hepatol* 2015;13:1776-81.
- Kobayashi Y, Hayashino Y, Jackson JL, et al. Diagnostic performance of chromoendoscopy and narrow band imaging for colonic neoplasms: a meta-analysis. *Colorectal Dis* 2012;14:18-28.

9. Iwatate M, Sano Y, Hattori S, et al. The addition of high magnifying endoscopy improves rates of high confidence optical diagnosis of colorectal polyps. *Endosc Int Open* 2015;3:140-5.
10. Saligram S, Rastogi A. Methods to become a high performer in characterization of colorectal polyp histology. *Best Pract Res Clin Gastroenterol* 2015;29:651-62.
11. Tanaka S, Sano Y. Aim to unify the narrow band imaging (NBI) magnifying classification for colorectal tumors: current status in Japan from a summary of the consensus symposium in the 79th annual meeting of the Japan Gastroenterological Endoscopy Society. *Dig Endosc* 2011;23:131-9.
12. Hewett DG, Kaltenbach TR, Sano Y, et al. Validation of a simple classification system for endoscopic diagnosis of small colorectal polyps using narrow-band imaging. *Gastroenterology* 2012;143:599-607.
13. Hayashi N, Tanaka S, Hewett DG, et al. Endoscopic prediction of deep submucosal invasive carcinoma: validation of the narrow-band imaging international colorectal endoscopic (NICE) classification. *Gastrointest Endosc* 2013;78:625-32.
14. Wani S, Rastogi A. Narrow-band imaging in the prediction of submucosal invasive colon cancer: how "NICE" is it? *Gastrointest Endosc* 2013;78:633-6.
15. Wallace MB. Not so NICE to be serrated. *Gastrointest Endosc* 2013;78:910-1.
16. Hirata M, Tanaka S, Oka S, et al. Evaluation of microvessels in colorectal tumors by narrow band imaging magnification. *Gastrointest Endosc* 2007;66:945-52.
17. Kanao H, Tanaka S, Oka S, et al. Narrow band imaging magnification predicts the histology and invasion depth of colorectal tumors. *Gastrointest Endosc* 2009;69:631-6.
18. Oba S, Tanaka S, Oka S, et al. Characterization of colorectal tumors using narrow-band imaging magnification: combined diagnosis with both pit pattern and microvessel features. *Scand J Gastroenterol* 2010;45:1084-92.
19. Oka S, Tanaka S, Takata S, Kanao H, et al. Clinical usefulness of narrow band imaging magnifying classification for colorectal tumors based on both surface pattern and microvessel features. *Dig Endosc* 2011;23:101-5.
20. Sano Y, Ikematsu H, Fu KI, et al. Meshed capillary vessels by use of narrow-band imaging for differential diagnosis of small colorectal polyps. *Gastrointest Endosc* 2009;69:278-83.
21. Ikematsu H, Matsuda T, Emura F, et al. Efficacy of capillary pattern type IIIA/IIIB by magnifying narrow band imaging for estimating depth of invasion of early colorectal neoplasms. *BMC Gastroenterol* 2010;10:33.
22. Wada Y, Kudo S, Kashida H, et al. Diagnosis of colorectal lesions with the magnifying narrow-band imaging system. *Gastrointest Endosc* 2009;70:522-31.
23. Nikami T, Saito S, Tajiri H, et al. The evaluation of histological atypia and depth of invasion of colorectal lesions using magnified endoscopy with narrow-band imaging. *Gastroenterol Endosc* 2009;51:10-9.
24. Sano Y, Tanaka S, Kudo SE, et al. NBI magnifying endoscopic classification of colorectal tumors proposed by the Japan NBI Expert Team (JNET). *Dig Endosc* 2016;28:526-33.
25. Sumimoto K, Tanaka S, Shigita K, et al. Clinical impact and characteristics of the NBI magnifying endoscopic classification of colorectal tumors proposed by the Japan NBI Expert Team (JNET). *Gastrointest Endosc* 2016;85:816-21.
26. Kaneko K, Fujii T, Kato S, et al. Growth patterns and genetic changes of colorectal carcinoma. *Jpn J Clin Oncol* 1998;28:196-201.
27. George SM, Mäkinen MJ, Jernvall P, et al. Classification of advanced colorectal carcinomas by tumor edge morphology: evidence for different pathogenesis and significance of polypoid and nonpolypoid tumors. *Cancer* 2000;89:1901-9.
28. The Paris endoscopic classification of superficial neoplastic lesions: esophagus, stomach, and colon: November 30 to December 1, 2002. *Gastrointest Endosc* 2003;58:53-43.
29. Boman FT, Carneiro F, Hruban RH, et al. WHO classification of tumours of the digestive system, 4th ed. Lyon, France: IARC; 2010.
30. Watanabe T, Itabashi M, Shimada Y, et al. Japanese Society for Cancer of the Colon and Rectum (JSCCR) guidelines 2014 for treatment of colorectal cancer. *Int J Clin Oncol* 2015;20:207-39.
31. Landis JR, Koch GG. The measurement of observer agreement for categorical data. *Biometrics* 1977;33:159-74.
32. Tanaka S, Kashida H, Saito Y, et al. JGES guidelines for colorectal endoscopic submucosal dissection/endoscopic mucosal resection. *Dig Endosc* 2015;27:417-34.
33. Tanaka S, Terasaki M, Hayashi N, et al. Warning for unprincipled colorectal endoscopic submucosal dissection: accurate diagnosis and reasonable treatment strategy. *Dig Endosc* 2013;25:107-16.
34. Tanaka S, Tamegai Y, Tsuda S, et al. Multicenter questionnaire survey on the current situation of colorectal endoscopic submucosal dissection in Japan. *Dig Endosc* 2010;22:S2-8.
35. Takeuchi Y, Ohta T, Matsui F, et al. Indication, strategy and outcomes of endoscopic submucosal dissection for colorectal neoplasm. *Dig Endosc* 2012;24:100-4.
36. Tanaka S, Terasaki M, Kanao H, et al. Current status and future perspectives of endoscopic submucosal dissection for colorectal tumors. *Dig Endosc* 2012;24:73-9.
37. Toll AD, Fabius D, Hyslop T, et al. Prognostic significance of high-grade dysplasia in colorectal adenomas. *Colorectal Dis* 2011;13:370-3.
38. Cha JM, Lee JI, Joo KR, et al. Clinicopathological risk factors of early carcinoma in colorectal neoplasias according to Japanese and Western criteria. *Hepatogastroenterology* 2015;62:25-9.
39. Kume K, Murata I, Yoshikawa I, et al. Endoscopic piecemeal mucosal resection of large colorectal tumors. *Hepatogastroenterology* 2005;52:429-32.
40. Uraoka T, Saito Y, Matsuda T, et al. Endoscopic indications for endoscopic mucosal resection of laterally spreading tumours in the colorectum. *Gut* 2006;55:1592-7.
41. Oka S, Tanaka S, Kanao H, et al. Therapeutic strategy for colorectal laterally spreading tumor. *Dig Endosc* 2009;21:S43-6.
42. Terasaki M, Tanaka S, Oka S, et al. Clinical outcomes of endoscopic submucosal dissection and endoscopic mucosal resection for laterally spreading tumors larger than 20 mm. *J Gastroenterol Hepatol* 2012;27:734-40.
43. Tanaka S, Oka S, Chayama K, et al. Colorectal endoscopic submucosal dissection: present status and future perspective, including its differentiation from endoscopic mucosal resection. *J Gastroenterol* 2008;43:641-51.
44. Saito Y, Sakamoto T, Nakajima T, et al. Colorectal ESD: current indications and latest technical advances. *Gastrointest Endosc Clin North Am* 2014;24:245-55.
45. Sakamoto T, Saito Y, Nakajima T, et al. Comparison of magnifying chromoendoscopy and narrow-band imaging in estimation of early colorectal cancer invasion depth: a pilot study. *Dig Endosc* 2011;23:118-23.
46. Hayashi N, Tanaka S, Kanao H, et al. Relationship between narrow-band imaging magnifying observation and pit pattern diagnosis in colorectal tumors. *Digestion* 2013;87:53-8.
47. Ozawa S, Tanaka S, Hayashi N, et al. Risk factors for vertical incomplete resection in endoscopic submucosal dissection as total excisional biopsy for submucosal invasive colorectal carcinoma. *Int J Colorectal Dis* 2013;28:1247-56.
48. Mukae M, Kobayashi K, Sada M, et al. Diagnostic performance of EUS for evaluating the invasion depth of early colorectal cancers. *Gastrointest Endosc* 2015;81:682-90.
49. Sakashita M, Aoyama N, Maekawa S, et al. Flat-elevated and depressed, subtypes of flat early colorectal cancers, should be distinguished by their pathological features. *Int J Colorectal Dis* 2000;15:275-81.
50. Takata S, Tanaka S, Hayashi N, et al. Characteristic magnifying narrow-band imaging features of colorectal tumors in each growth type. *Int J Colorectal Dis* 2013;28:459-68.