

Management of Neonatal Ovarian Cyst

Sho AKAMINE^{1,*}, Kazuhiro OHTSU¹, Naomi KAMEI¹,
Rie FUKUHARA², and Taijiro SUEDA³

1) Department of Pediatric Surgery, Hiroshima Prefectural Hospital, Hiroshima, Japan

2) Department of Neonatology, Hiroshima Prefectural Hospital, Hiroshima, Japan

3) Department of Surgery, Hiroshima University, Graduate School of Medicine, Hiroshima, Japan

ABSTRACT

Objective: There is no guideline for the treatment of neonatal ovarian cysts. The present study analyzed our clinical management of such cysts, as well as the results of treatment.

Methods: The present study involved 16 patients with neonatal ovarian cysts who had been diagnosed and treated between January 2002 and December 2016. We classified the cysts into two groups based on ultrasonographic images: (1) simple cysts (SCs)—thin-walled, round, or anechoic; (2) complex cysts (CCs), containing fluid-debris level, solid masses, or intracystic septa. We analyzed the clinical characteristics and results in the two groups.

Results: Ten of the patients had SCs and six had CCs. Fourteen were diagnosed during the prenatal stages. Of the 10 patients with SCs, eight were managed using observation only, and the cysts spontaneously resolved in all such cases. Six patients had CCs, including one with an SC that had developed into a CC. Eight of the patients underwent surgical treatment, and the surgical methods did not differ in terms of operation time or complication rate. None of the oophorectomy specimens contained any normal ovarian tissue.

Conclusion: We operated on all CCs and on SCs more than 40 mm in diameter, while patients with SCs less than 40 mm in diameter were managed using observation only, as were those in whom differential diagnosis was not possible. We must emphasize that percutaneous aspirations are safe, and we recommend trans-umbilical incisions, because they preserve both esthetics and ovarian function.

Key words: ovarian cyst, neonate, fetus, ultrasonography

INTRODUCTION

Recent developments in abdominal ultrasound imaging of fetuses and neonates have allowed clinicians to discover intra-abdominal cysts more often during the perinatal period. In particular, ovarian cysts are one of the most common varieties in girls.

Most ovarian cysts detected during the perinatal period regress spontaneously during the observation period. However, some cause ovarian torsion and consequent necrosis. Furthermore, it is not yet clear how ovarian cysts should be managed (image findings and cyst size by ultrasonography, puncture or surgery, etc.).

In the present study, we retrospectively analyzed all cases of neonatal ovarian cysts that occurred at our own institution, focusing on treatments, criteria, policies, and prognosis.

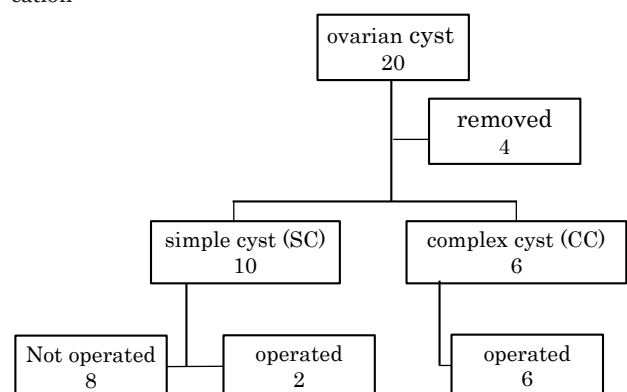
MATERIALS AND METHODS

We examined 20 patients with ovarian cysts who were referred to our department between January 2002 and December 2016. Four were removed from this study, two of whom were referred to other hospitals because their

parents had moved to other locations and two of whom had no available diagnostic records. We retrospectively analyzed the remaining 16 cases (Table 1) using their medical records, which covered gestational age, body weight at birth, age (weeks) at which the ovarian cysts were detected, cyst size, and cyst condition.

The 16 patients were classified into two groups: those who were scheduled for primary surgery and those whose initial management was to be observation only. In

Table 1 Flow chart detailing patient exclusion and classification



* Corresponding author: Sho Akamine

Department of Pediatric Surgery, Hiroshima Prefectural Hospital, 1-5-54 Ujina-Kanda, Minami-ku, Hiroshima 734-8530, Japan
Tel: +81-82-254-1818, Fax: +81-82-253-8274, E-mail: sho.akamine.01@gmail.com

Table 2 Background of Neonatal Ovarian Cyst Patients

	Total (n = 16)	Simple Cyst (n = 10)	Complex Cyst (n = 6)	p value (SC vs CC)
Gestational Age (weeks)	38.3 ± 1.1	38.5 ± 1.1	38.2 ± 1.0	0.732
Birth Weight (g)	2,302.9 ± 418.4	3,251.8 ± 464.7	3,121.5 ± 310.4	0.279
Gestational Age at Diagnosis (weeks)	33.2 ± 2.8	33.0 ± 3.0	33.8 ± 2.2	0.920
Diameter of cyst (mm)	34.7 ± 14.0	33.5 ± 17.0	36.7 ± 6.0	0.686

Table 3 Clinical Characteristics of Simple Cyst Patients

Case No.	Side	Gestational age (weeks)	Birth Weight (g)	Gestational Age at Diagnosis (weeks)	Diameter of Cyst (mm)	Treatment	Duration of Follow up (days)	Times of Visits
1	Left	39	4,248	31	44	Operation	unknown	unknown
2	Right	41	3,248	36	67	Operation	unknown	unknown
3	Right	38	3,406	36	36	Follow up	106	2
4	Left	37	3,018	after birth	13	Follow up	111	3
5	Right	37	3,790	35	48	Follow up	177	8
6	Right	39	2,960	32	32	Follow up	337	9
7	Left	38	3,370	29	10	Follow up	14	2
8	Left	39	2,906	38	35	Follow up	86	5
9	Right	38	2,908	30	12	Follow up	90	4
10	Left	39	2,628	30	38	Follow up	45	4

the surgery group, we compared age (days after birth), duration of operation, and duration of hospitalization.

The ovarian cysts themselves were also classified into two groups: (1) simple cysts (SCs), which have a homogenous interior, as indicated by ultrasound examination and (2) complex cysts (CCs), which contain fluid-debris level, present echography resembling a solid mass, or consist of multiple cysts.

We decided to manage patients with SCs less than 40 mm in diameter using observation only, and to operate on those with CCs and on those with SCs more than 40 mm in diameter, as indicated by ultrasound examination. Those who could not be differentially diagnosed were also managed using observation only.

RESULTS

Backgrounds of patients

Out of the 16 patients we studied, 10 had SCs and six had CCs. We conducted surgery on eight patients (two from the SC group and six from the CC group). We managed the other eight patients, who all had SCs, using observation only.

The mean gestational age of the patients was 38.3 ± 1.1 weeks. Their mean body weight at birth was 2,302.9 ± 418.4 g, and the mean age (weeks) at which their cysts were detected was 33.2 ± 2.8 weeks. Fourteen of the patients had been diagnosed as having ovarian cysts during prenatal ultrasonography. The mean diameter of the cysts was 34.7 ± 14.0 mm. The diameter of the cysts when they were first detected did not differ significantly between the SC and CC groups (Table 2).

SC patient group

Ten of the patients in the SC group were diagnosed by ultrasonography, nine of whom had been diagnosed prenatally (Table 3). All of the cysts were located unilaterally—five in the left ovary and five in the right ovary.

The mean diameter of the cysts was 33.5 ± 17.0 mm. Three patients had cysts measuring 40 mm or more, two of whom underwent surgery. The third of these patients did not undergo surgery because her family asked us not to operate on her, although we did observe her carefully to ensure no operation was needed. In her case, the cyst regressed spontaneously after 177 days of observation.

In all patients with SCs less than 40 mm in diameter, the cysts had regressed spontaneously after a mean follow-up period of 120.7 ± 93.2 days. The mean number of hospital visits was 4.6 ± 2.5.

CC patient group

Six patients were diagnosed with CCs using ultrasonography. All except one in whom the medical records were unavailable were diagnosed prenatally (Table 4). All of the cysts were located unilaterally: three in the left ovary and 3 in the right. Their mean diameter was 36.7 ± 6.0 mm. Ultrasonographic examination revealed that cysts in two patients were filled with a solid-mass, while one patient had multiple cysts and three had cysts containing fluid-debris. All of these patients underwent surgery because ovarian torsion was suspected.

Patient No. 15 had been observed at other institute and was presented at our own hospital when she was 8 months old. Ultrasonography revealed a cyst with fluid-debris. We operated on the patient on the same day because we suspected ovarian torsion. During the operation, we found that the ovarian torsion had caused the cyst to autoamputate. Patient No.16, who was initially diagnosed with an SC, showed no signs of natural regression. When she was 3 months old, fluid-debris level was observed using MRI, and an operation was performed.

Operation

We operated on a total of eight patients. Of these, two

Table 4 Clinical Characteristics of Complex Cyst Patients

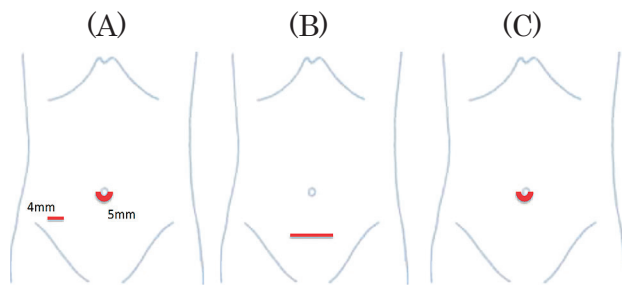
Case No.	Side	Gestational age (weeks)	Birth Weight (g)	Gestational Age at Diagnosis (weeks)	Diameter of Cyst (mm)	Ultrasonographic Findings
11	Left	39	2,640	38	30	solid mass
12	Right	37	3,098	34	38	solid mass
13	Left	38	3,128	33	48	multiple cyst
14	Right	37	3,234	32	37	fluid level
15	Left	40	3,674	32	37	fluid level
16	Right	38	2,955	unknown	30	fluid level

Table 5 Clinical Characteristics and Outcomes of Treatments in Operated Cases

Case	Cyst	Operated Age (days)	Torsion	Procedure	Method	Operation Time (minutes)	Hospital Stay (days)
1	Simple	10	No	Cystectomy	Pfannenstiell incision	40	8
2	Simple	5	No	Cystectomy	Transumbilical incision	101	10
11	Complex	12	Yes	Salpingo-Oophorectomy	Laparoscopic operation	47	6
12	Complex	9	Yes	Salpingo-Oophorectomy	Pfannenstiell incision	73	12
13	Complex	7	Yes	Salpingo-Oophorectomy	Transumbilical incision	68	11
14	Complex	8	Yes	Cystectomy	Transumbilical incision	97	9
15	Complex	270	Yes	Salpingo-Oophorectomy	Laparoscopic operation	61	7
16	Complex	90	Yes	Salpingo-Oophorectomy	Laparoscopic operation	50	8

Table 6 Outcome of patients received Laparoscopic operation and those received Transumbilical incision

	Laparoscopic operation (n = 3)	Transumbilical incision (n = 3)	<i>p</i> value
Operation time (minutes)	52.6 ± 6.0	88.7 ± 14.7	0.133
Postoperative Hospital Stay (days)	7 ± 0.8	10 ± 0.8	0.095

**Figure 1** Incision of each approach. (A) Laparoscopic operation, (B) Pfannenstiell incision, (C) Transumbilical incision.

were had SCs over 40 mm and six had CCs (Table 5). The mean diameter of the cysts at initial diagnosis was 41.3 ± 11.3 mm.

Except for patients Nos. 15 and 16, we operated on all patients during early infancy, at a mean age of 8.5 ± 2.2 days. The operations were performed using three different approaches: the Pfannenstiell incision, the laparoscopic incision, and the transumbilical incision (Figure 1). The Pfannenstiell incision was performed in two cases, the laparoscopic incision in three cases, and the transumbilical incision in three cases. In the past, we used the Pfannenstiell incision to preserve esthetics, and it was useful even when the surgeons did not know which ovary contained the cyst. After that, we used the laparoscopic incision, through which cysts can be removed from the abdominal cavity and laparoscopy can be used to check which side the ovarian cyst was on. The latest three operations were all performed using the transum-

bilical incision. We found that there was no statistical difference between the transumbilical incision and laparoscopic incision in terms of the necessary operation time ($p = 0.133$) and the duration of the post-operation hospital stay ($p = 0.095$; Table 6)

Our procedures involved relocating cysts after puncture, as well as aspirating inside the cysts—either laparoscopically or under direct vision. We also tried to remove the cysts themselves while preserving ovaries as far as possible. Even when we decided that it was impossible to preserve the ovary in its entirety, we resected parts of the wall of the cyst and remaining ovarian tissue.

When the ovary was necrotized due to torsion of the Fallopian tube (Figure 2A), or when the cyst had autoamputated into the intraperitoneal cavity (Figure 2B), a salpingo-oophorectomy was performed.

Of the eight patients who underwent surgery, we removed cysts from three and performed a salpingo-oophorectomy in five. No patients suffered any complications after these operations, and pathological examination of the samples of salpingo-oophorectomy found that no healthy ovary tissue was present.

DISCUSSION

The prevalence of ovarian cysts among newborn girls is approximately 1 in 2,500 births¹⁾, and the condition may be caused by “prolonged stimulation of ovaries by fetal gonadotropins during the antenatal period¹⁾.” Alternatively, placental insufficiency may result in incomplete maturation of the gonadostat, leading to ovarian hyper-

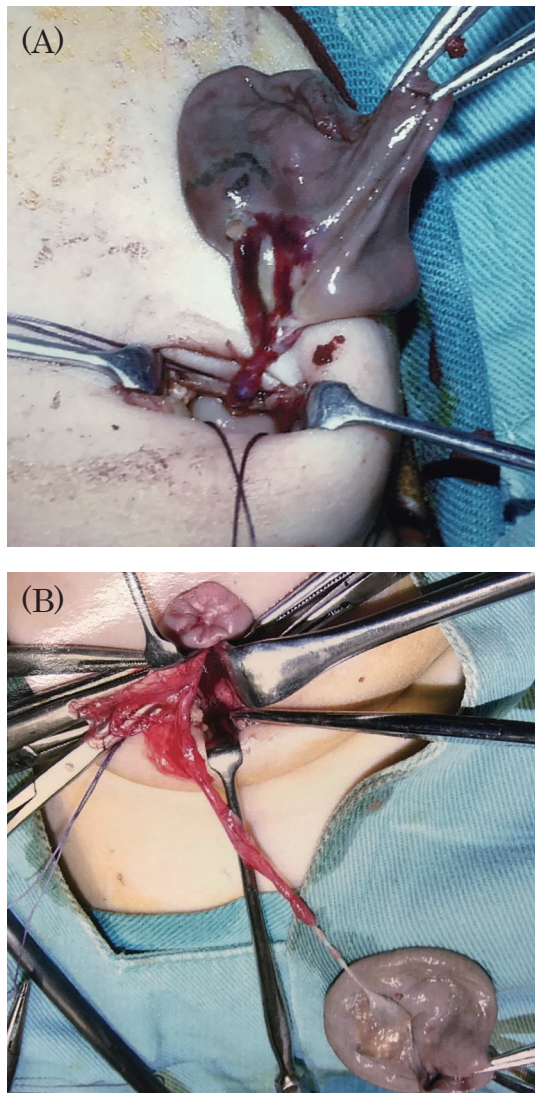


Figure 2 Operation findings. Photograph (A) shows torsion and necrosis at the level of the fallopian tube (Case 11), while photograph (B) shows an autoamputated ovary caused by chronic torsion (Case 15).

stimulation and therefore cysts in full-term infants¹². Finally, maternal diabetes, rhesus incompatibility, and maternal toxemia are risk factors¹².

Ovarian cysts are most often diagnosed by ultrasonography and can usually be detected at about 6 months' gestation. However, some ovarian cysts are detected as late as 28 weeks' gestation, while others are diagnosed at 19 weeks^{6,9}. Thanks to advances in ultrasonography of fetuses and neonates, the frequency of ovarian cyst detection has been increasing.

Differential diagnosis has shown that cystic abdominal masses may constitute intestinal duplication cysts, omental cysts, congenital hydronephrosis, meconium pseudocyst peritonitis, hydrometrocolpos, lymphangioma, anterior meningocele, mesenteric cysts, or urachal cysts. Ovarian cysts usually manifest as single-chamber bodies with thin walls and can be classified into two groups based on their ultrasonographic features: (1) SCs have a uniform, low-echo interior structure and are associated with smaller daughter cysts on the inside or

outside walls; (2) CCs contain either fluid-debris level or septa⁷. In general, ultrasound images of CCs indicate ovarian torsion or hemorrhaging, and calcification is often observed in cysts that have undergone autoamputation following ovarian torsion¹³. In cases of CCs, the ovaries may lose their function.

Since most ovarian cysts are clinically unimportant and regress spontaneously, small cysts should be managed using observation only, without initial surgical intervention. Sometimes, hemosiderophages occur in CCs, suggesting a history of ovarian torsion and/or intracystic hemorrhage. In fact, even small ovarian cysts may trigger ovarian torsion or ovarian dysfunction¹⁰, and observation only is therefore recommended in most cases until the cysts regress spontaneously.

Ovarian cysts should be treated by surgical intervention when they confer a risk of ovarian necrosis due to torsion, or when they may rupture or cause intestinal obstruction. It is difficult to evaluate the state of blood flow to the ovary using ultrasound imaging⁹. More specifically, surgery should be performed on patients with CCs, or on those with SCs larger than 40 mm, because the risk of ovarian torsion is significantly higher in cysts of this size. When surgical intervention is planned, the preservation of ovarian function is important. However, there is no established guideline on what type of surgical intervention is appropriate—ultrasound-guided aspiration at the intrauterine stage, percutaneous aspiration during the neonatal period, cystectomy, cyst fenestration, and salpingo-oophorectomy can all be used to treat ovarian cysts, and the specific surgical intervention used differs among institutions.

Ovarian cyst aspiration performed on a fetus has many disadvantages. For example, the rate of recurrence is high (37.9%)², and the method carries various risks, including rupture of the cyst, peritonitis, premature labor, chorioamnionitis, and fetal damage⁹. Therefore, ovarian cyst aspiration should only be performed on a fetus in a limited number of cases.

Percutaneous ovarian cyst aspiration performed on neonates is safer. With regards to this procedure, Cho, et al. reported that surgically removed CCs contained normal tissues, and that ovarian cyst aspiration is therefore preferable to cystectomy because the fertility of the newborn must be preserved⁹. Other researchers have claimed that this method confers a risk of peritonitis because it can disseminate necrotized tissues or coagulated blood, which could in turn induce a hemorrhage or adhesion. They also warn that malignant cells could be disseminated as a result of such a puncture and aspiration if the cyst is malignant⁴. Aspiration of putative ovarian cysts has been performed in patients with other diseases due to misdiagnosis¹¹, and because it is an unreliable procedure, we posit that it is dangerous in such cases. For this reason, conducted ovarian cystectomy on patients in the present study. Indeed, mere aspiration of cyst contents without cystectomy can result in cyst recurrence or even multiplication. We also believe that percutaneous aspiration is insufficient to treat CCs. Indeed, we found no normal ovarian tissue in any of the

CC cystectomy specimens in the present study, so we believe that aspirated CCs are unlikely to contain healthy ovarian tissue.

Pfannenstiel incisions have been used to carry out ovarian cystectomy for many years. However, there have been reports in recent years about the appropriateness of a cystectomy accompanied by a transumbilical ring incision under which have aspirated ovarian cysts laparoscopically or under direct vision and removed cysts by relocating cysts out of the abdominal cavity in view of a minimal invasive surgery^{7,8)}.

We used to perform ovarian cystectomy either by Pfannenstiel incision through laparoscopy. However, we have recently begun to conduct transumbilical ovarian cystectomy, because this method leaves smaller, less conspicuous scars. Using this method, we have obtained results comparable to those obtained using the laparoscopic approach in terms of operation time and complication rate.

Thus, transumbilical ovarian cystectomy is recommended because it lowers operation costs and preserves esthetics. It also allows surgeons to check the state of the contralateral ovary. However, the cyst may be too small to aspirate; in such cases, surgeons must be prepared to perform laparoscopic exploration.

CONCLUSION

The present study described an analysis of ovarian cyst management in neonates at our institution. We believe that patients with SCs less than 40 mm in diameter should be managed using observation only, and that ovarian cystectomy should be considered in patients whose SCs show signs that they may grow rather than spontaneously regress, while taking into consideration the results of additional examinations, such as MRI. We have also concluded that it is appropriate to consider conducting an ovarian cystectomy on patients with CCs and on patients with SCs over 40 mm.

Our experience has demonstrated that transumbilical ovarian cystectomy can provide good results comparable to those obtained using other surgical methods. Regardless of the surgical methods used, preservation of ovarian function must be at the forefront of surgeons' concerns when treating ovarian cysts.

ACKNOWLEDGEMENTS

Compliance with Ethical Standards

Conflict of interest

No conflicts of interest

(Received August 20, 2018)

(Accepted January 20, 2019)

REFERENCES

1. Banu, K.A., Nurcin, S., Firdevs, B., Yasin, Y., Belma, H., Tulay, G., et al. 2017. Evaluation and treatment results of ovarian cysts in childhood and adolescence: a multicenter, retrospective study of 100 patients. *J. Pediatr. Adolesc. Gynecol.* 30: 449–455.
2. Bascietto, F., Liberati, M., Marrone, L., Khalil, A., Pagani, G., Gustapane, S., et al. 2017. Outcome of fetal ovarian cysts diagnosed on prenatal ultrasound examination: systematic review and meta-analysis. *Ultrasound Obstet. Gynecol.* 50: 21–30.
3. Cho, M.J., Kim, D.Y. and Kim, S.C. 2015. Ovarian cyst aspiration in the neonate: minimally invasive surgery. *J. Pediatr. Adolesc. Gynecol.* 28: 348–353.
4. Giampiero, S. and Jenny, W. 2009. A giant ovarian cyst in a neonate. *J. Pediatr. Adolesc. Gynecol.* 22: e17–e20.
5. Hannah, N.L., Martha, G.B., Mircia, A.A., Christa, S. and Roman, M. 2017. Laparoscopic management of autoamputated ovary in newborns: A report of 2 cases. *Minim. Invasive. Gynecol.* 24: 859–862.
6. Johnathan, C.P., Deborah, F.B., Frederick, J.R., S. Maria, E.F. and Chales, M.L. 2014. Management of neonatal ovarian cysts and its effect on ovarian preservation. *J. Pediatr. Surg.* 49: 990–994.
7. Lee, H.J., Woo, S.K., Kim, J.S., Suh, S.J. 2000. "Daughter cyst" sign: A sonographic findings of ovarian cyst in neonates, infants, and young children. *Am. J. Roentgenol.* 175: 1013–1015.
8. Lucy, S., Timothy, M.W. and Phillips, J.D. 2008. Evolution of the surgical management of neonatal ovarian cysts: laparoscopic-assisted transumbilical extracorporeal ovarian cystectomy (LATEC). *J. Laparoendosc. Adv. Surg. Tech.* 18: 635–640.
9. Mustafa, A.A., Leyla, A., Sibel, O., Gulay, T., Sultan, K., Serder, S., et al. 2010. Fetal-neonatal ovarian cysts-their monitoring and management: retrospective evaluation of 20 cases and review of the literature. *J. Clin. Res. Ped. Endo.* 2: 28–33.
10. Prasad, S. and Chui, C.H. 2007. Laparoscopic-assisted transumbilical ovarian cystectomy in a neonate. *JSLs.* 11: 138–141.
11. Puligandla, P.S. and Laberge J.M. 2009. Lethal outcome after percutaneous aspiration of a presumed ovarian cyst in a neonate. *Semin. Pediatr. Surg.* 18: 19–121.
12. Raghu, S., Jai, K.M., Sanat, K. and Katragadda, L.R. 2010. Bilateral ovarian cysts in a neonate with salt-wasting congenital adrenal hyperplasia. *J. Pediatr. Surg.* 45: E19–E21.
13. Salvador, R.L., Nebot, C.S., Usmayo, A.P., Aliaga, S.P. and Inigo, E.G. 2017. Neonatal ovarian cysts: Ultrasound assessment and differential diagnosis. *Radiologia.* 59: 31–39.