

広島大学学術情報リポジトリ

Hiroshima University Institutional Repository

Title	Comparison of anterior chamber depth measurements by 3-dimensional optical coherence tomography, partial coherence interferometry biometry, Scheimpflug rotating camera imaging, and ultrasound biomicroscopy
Author(s)	Nakakura, Shunsuke; Mori, Etsuko; Nagatomi, Nozomi; Tabuchi, Hitoshi; Kiuchi, Yoshiaki
Citation	Journal of Cataract & Refractive Surgery , 38 (7) : 1207 - 1213
Issue Date	2012-07
DOI	10.1016/j.jcrs.2012.02.036
Self DOI	
URL	https://ir.lib.hiroshima-u.ac.jp/00045956
Right	Copyright (c) 2012 ASCRS and ESCRS This is not the published version. Please cite only the published version. この論文は出版社版ではありません。引用の際には出版社版をご確認ご利用ください。
Relation	



Comparison of anterior chamber depth measurements by 3-dimensional optical coherence tomography, partial coherence interferometry biometry, Scheimpflug rotating camera imaging, and ultrasound biomicroscopy

Shunsuke Nakakura, MD, PhD, Etsuko Mori, CO, Nozomi Nagatomi, CO,
Hitoshi Tabuchi, MD, PhD, Yoshiaki Kiuchi, MD, PhD

PURPOSE: To evaluate the congruity of anterior chamber depth (ACD) measurements using 4 devices.

SETTING: Saneikai Tsukazaki Hospital, Himeji City, Japan.

DESIGN: Comparative case series.

METHODS: In 1 eye of 42 healthy participants, the ACD was measured by 3-dimensional corneal and anterior segment optical coherence tomography (CAS-OCT), partial coherence interferometry (PCI), Scheimpflug imaging, and ultrasound biomicroscopy (UBM). The differences between the measurements were evaluated by 2-way analysis of variance and post hoc analysis. Agreement between the measurements was evaluated using Bland-Altman analysis. To evaluate the true ACD using PCI, the automatically calculated ACD minus the central corneal thickness measured by CAS-OCT was defined as PCI true. Two ACD measurements were also taken with CAS-OCT.

RESULTS: The mean ACD was $3.72 \text{ mm} \pm 0.23 \text{ (SD)}$ (PCI), $3.18 \pm 0.23 \text{ mm}$ (PCI true), $3.24 \pm 0.25 \text{ mm}$ (Scheimpflug), $3.03 \pm 0.25 \text{ mm}$ (UBM), $3.14 \pm 0.24 \text{ mm}$ (CAS-OCT auto), and $3.12 \pm 0.24 \text{ mm}$ (CAS-OCT manual). A significant difference was observed between PCI biometry, Scheimpflug imaging, and UBM measurements and the other methods. Post hoc analysis showed no significant differences between PCI true and CAS-OCT auto or between the CAS-OCT auto and CAS-OCT manual. Strong correlations were observed between all measurements; however, Bland-Altman analysis showed good agreement only between PCI true and Scheimpflug imaging and between CAS-OCT auto and CAS OCT manual.

CONCLUSION: The ACD measurements obtained from PCI biometry, Scheimpflug imaging, CAS-OCT, and UBM were significantly different and not interchangeable except for PCI true and CAS-OCT auto and CAS-OCT auto and CAS-OCT manual.

Financial Disclosure: No author has a financial or proprietary interest in any material or method mentioned.

J Cataract Refract Surg 2012; ■:■-■ © 2012 ASCRS and ESCRS

The ability to accurately measure anterior chamber depth (ACD) is important for angle-closure glaucoma as well as for corrective surgeries for cataract or refractive pathology. Nonaka et al.¹ found that iris convexity was strongly correlated with ACD in patients who had primary angle closure. That is, a shallower ACD increased forward bowing of the iris, resulting in

pupillary block. In cataract surgery, ACD measurements are vital because they are used in power calculations for intraocular lenses (IOLs).^{2,3} The phakic IOL is currently one of the more popular surgical options for refractive surgery in highly myopic eyes. However, the use of an anterior chamber IOL can lead to long-term complications of the corneal endothelium, and

endothelial cell loss has been reported to be negatively correlated to ACD.⁴

At present, many methods to evaluate anterior chamber biometry are available. These include partial coherence interferometry (PCI),^{5,6} Scheimpflug imaging,⁷⁻⁹ ultrasound biomicroscopy (UBM),¹⁰⁻¹² scanning-slit tomography,^{12,13} and ultrasound A-scan.^{6,8} Recently, swept-source anterior segment optical coherence tomography (AS-OCT) has become available, and some studies^{14,15} have evaluated its effectiveness in ocular biometry. However, at present, there is no standardization between devices and it is unknown whether the measurements are interchangeable. To our knowledge, there are no studies that compared ACD measurements obtained from 3-dimensional (3-D) corneal and AS-OCT (CAS-OCT), PCI biometry, and UBM methods. Furthermore, there are no reported comparisons between the true ACD obtained by PCI biometry and measurements from other devices, nor have there been evaluations between 2 different ACD measurements obtained with CAS-OCT.

In this study, we compared ACD measurements obtained using 4 devices: a PCI biometer, a Scheimpflug imager, UBM, and CAS-OCT. We assessed the inter-device agreement to determine whether measurements obtained from the 4 devices can be used interchangeably.

SUBJECTS AND METHODS

Healthy subjects were recruited from Saneikai Tsukazaki Hospital between April and May in 2011. This study received approval from the hospital's institutional review board and was performed according to the tenets of the Declaration of Helsinki. Subjects with ocular disease or previous ocular surgery were excluded from this study.

All patients had a complete ophthalmic examination, including fundoscopy, before measurements were taken in the right eye. In all cases, the ACD measurements were taken in the same order on the same day under controlled dark conditions (20 lux) by 2 experienced operators (E.M., N.N.) as follows: CAS-OCT, PCI biometry, and Scheimpflug imaging. The UBM measurements were taken last by the same experienced operator (S.N.).

Submitted: November 9, 2011.

Final revision submitted: February 4, 2012.

Accepted: February 12, 2012.

From the Department of Ophthalmology (Nakakura, Mori, Nagatomi, Tabuchi), Saneikai Tsukazaki Hospital, Himeji, and the Department of Ophthalmology and Visual Sciences (Kiuchi), Graduate School of Biomedical Sciences, Hiroshima University, Hiroshima, Japan.

Corresponding author: Shunsuke Nakakura, MD, Department of Ophthalmology, Saneikai Tsukazaki Hospital, 68-1 Aboshi Waku, Himeji 671-1227, Japan. E-mail: shunsukenakakura@yahoo.co.jp.

Corneal and Anterior Segment Optical Coherence Tomography

The CAS-OCT system in this study (SS-1000 Casia, Tomey Corp.) uses swept-source technology based on 3-D Fourier-domain OCT with a light source of 1310 nm wavelength. The system takes 30 000 A-scans per second. The lateral resolution is 30 μ m and the axial resolution, 18 μ m. Tissue scans are 16.0 mm in diameter and 6.0 mm deep. Three images were obtained per case. The system was used to measure the ACD and central corneal thickness (CCT) by 2 methods: (1) automatically calculated ACD and CCT (CAS-OCT auto) along an axial line placed from angle to angle with a perpendicular projection that extends from a median point forward through the cornea (Figure 1), and (2) manually calculated ACD and CCT (CAS-OCT manual) using calipers along the corneal endothelium in line with the corneal vertex to the anterior surface of the lens (Figure 1). The ACD and CCT were defined as the mean of 3 images.

Partial Coherence Interferometry Biometer

The PCI biometer used in the study (IOLMaster Carl Zeiss Meditec AG) can take 5 simultaneous ACD measurements; the mean of these readings was used. The biometer uses the principle of PCI to measure the axial length of the globe; however, the ACD is measured by optical principles using a non-PCI method. The PCI biometer uses a slit-beam photographic technique for ACD measurements. A beam of light is projected through the anterior segment of the eye at 33 degrees to the visual axis. The PCI biometer calculates the ACD automatically using a 33-degree tangent and a constant.⁹ However, the ACD measured by the PCI biometer includes the CCT; thus, the ACD measurements might be longer than the ACD measurements taken using the other devices. To circumvent this, 2 measurements were taken using the PCI biometer as follows: (1) an automatically calculated ACD and (2) a true ACD, which was defined as the ACD minus the CCT (CAS-OCT manual) because it drew a more direct vertical line to the central cornea than to the CCT (CAS-OCT auto) (Figure 1).

Scheimpflug Imaging Device

This Scheimpflug imaging device (Pentacam, Oculus, Inc.) was used in the 25-image mode. The device automatically takes 1 measurement by rotating the camera 360 degrees and capturing 25 Scheimpflug images using a monochromatic slit-light source (blue light-emitting diode at

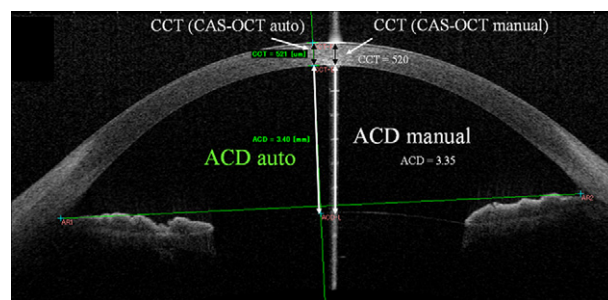


Figure 1. Two measurements using CAS-OCT (ACD = anterior chamber depth; CAS-OCT = corneal and anterior segment optical coherence tomography; CCT = central corneal thickness).

475 nm). The ACD and CCT were defined as the mean of 25 images. The ACD was calculated from the corneal endothelium in line with the corneal vertex to the anterior surface of the lens.

Ultrasound Biomicroscopy

The ultrasound biomicroscope used (HiScan, Optikon 2000) is equipped with a 50 MHz transducer. With the subjects supine, topical anesthesia of oxybuprocaine hydrochloride 0.4% (Benoxyl) was applied. The right eye was imaged 3 times using an eyecup filled with methylcellulose 2% and a physiologic salt solution. The ACD was measured manually with calipers from the corneal endothelium in line with the corneal vertex to the anterior surface of the lens. The mean of the 3 measurements was used for subsequent analysis.

Statistical Analysis

Statistical analyses were performed using JMP software (version 6.0.3, SAS Institute, Inc.). Data were expressed as the mean \pm standard deviation (SD); *P* values less than 0.05 were considered statistically significant. The statistical significance of interdevice differences was evaluated using 2-way analysis of variance (ANOVA) and post hoc analysis (Tukey-Kramer). In the Bland-Altman analysis, the distribution of measurements was expressed as the mean difference between 2 devices with the SD as well as the 95% limits of agreement (LoA). The 95% LoA were defined as the means \pm 1.96 SD. The Pearson correlation coefficient (*r*) between each measurement was also evaluated. Paired *t* tests were used to compare the difference between the CCT measured by PCI and AS-OCT.

RESULTS

Measurements of 42 patients (18 women, 24 men) were included in the study. The mean age of the subjects was 30.8 ± 6.9 years (range 22 to 46 years). The mean spherical equivalent refraction was -3.75 ± 2.40 diopters. The mean CCT measurement was 550 ± 32 μ m using the Scheimpflug device, 535 ± 28 μ m using CAS-OCT manual, and 528 ± 31 μ m using CAS-OCT auto. There was no significant difference in CCT measurements between CAS-OCT auto and CAS-OCT manual (*P*=1.00, paired *t*-test). However, there was a significant difference in CCT measurements between the Scheimpflug device and CAS-OCT (*P*<.001, paired *t* test).

The mean ACD measurements were 3.72 ± 0.23 mm with the PCI biometer, 3.18 ± 0.23 mm with PCI true, 3.24 ± 0.25 mm with the Scheimpflug device, 3.03 ± 0.25 mm with UBM, 3.14 ± 0.24 mm with CAS-OCT auto, and 3.12 ± 0.24 mm with CAS-OCT manual. Post hoc analysis found significant differences in measurements between the PCI biometer and other measurements, the Scheimpflug device and other measurements, and UBM and other measurements (Figure 2).

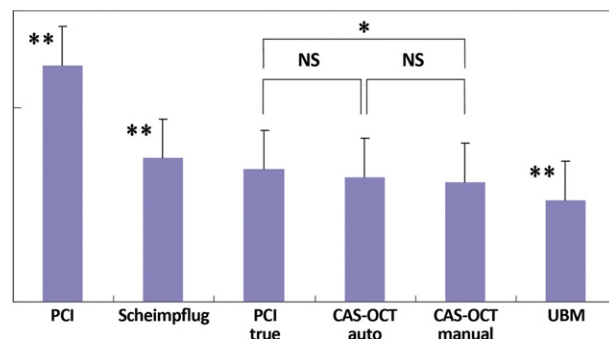


Figure 2. Means of 6 measurements using 4 devices (* = statistical significance observed using the Tukey-Kramer method; ** = statistical significance observed between the other 5 measurements using the Tukey-Kramer method; CAS-OCT = corneal and anterior segment optical coherence tomography; NS = not significant; PCI = partial coherence interferometry).

There were no significant differences between PCI true and CAS-OCT auto (95% confidence interval (CI), -0.002 to 0.081) and or between CAS-OCT auto and CAS-OCT manual (95% CI, -0.016 to 0.067) when analyzed by 2-way ANOVA and post hoc testing. Table 1 shows the Bland-Altman analysis of the differences in the mean ACD measurements and the Pearson correlation coefficients. Good correlation coefficients were observed between all measurements (*r* = 0.848 to 0.995). Using Bland-Altman analysis, the width of 95% LoA was smallest with CAS-OCT auto and CAS-OCT manual and largest with UBM and CAS-OCT auto.

There was good agreement between PCI true and the Scheimpflug device, between PCI true and CAS-OCT auto, between PCI true and CAS-OCT manual, and between CAS-OCT auto and CAS-OCT manual (Figure 3).

Figure 4 shows the Bland-Altman plots of the paired differences against mean values for PCI biometer, Scheimpflug device, UBM, and CAS-OCT auto. The calculated mean differences between 2 measurements were not zero; however, almost all distributions of these differences were within the 95% LoA.

DISCUSSION

We believe this is the first study to evaluate the true ACD using the IOLMaster PCI biometer. This is important because this biometer is the most commonly used tool for IOL power calculations worldwide. In this study, the ACD measurements obtained by the PCI biometer were longer than other measurements. Our data contradict results in a previous study by Meinhardt et al.,¹⁶ who report an ACD measurement of 3.63 mm using the IOLMaster biometer and of 3.915 mm using the Pentacam Scheimpflug device

Table 1. Results of Bland-Altman analysis and correlation coefficients.

Bland-Altman Analysis	Difference Between 2 Measurements			LoA		
	Mean (mm)	SD (mm)	<i>r</i> value	Lower 95%	Upper 95%	Width of 95%
PCI and PCI true	0.535	0.027	0.993	0.482	0.589	0.107
PCI and Scheimpflug	0.475	0.067	0.963	0.345	0.605	0.26
PCI and UBM	0.609	0.128	0.868	0.425	0.928	0.503
PCI and CAS-OCT auto	0.575	0.085	0.933	0.407	0.743	0.336
PCI and CAS-OCT manual	0.600	0.086	0.931	0.432	0.769	0.337
PCI true and Scheimpflug	-0.060	0.065	0.965	-0.187	0.066	0.253
PCI true and UBM	0.154	0.122	0.880	-0.084	0.393	0.477
PCI true and CAS-OCT auto	0.04	0.082	0.939	-0.121	0.200	0.321
PCI true and CAS-OCT manual	0.065	0.084	0.936	-0.099	0.229	0.328
Scheimpflug and UBM	0.215	0.118	0.889	-0.017	0.446	0.463
Scheimpflug and CAS-OCT auto	0.100	0.072	0.957	-0.041	0.241	0.282
Scheimpflug and CAS-OCT manual	0.126	0.075	0.953	-0.021	0.272	0.293
UBM and CAS-OCT auto	-0.114	0.137	0.848	-0.382	0.153	0.535
UBM and CAS-OCT manual	-0.089	0.134	0.853	-0.352	0.174	0.526
CAS-OCT auto and CAS-OCT manual	0.026	0.024	0.995	-0.022	0.073	0.095

CAS-OCT = corneal and anterior segment optical coherence tomography; LoA = limits of agreement; Lower 95% LoA = mean - 1.96 SD. Upper 95% LoA = mean + 1.96 SD; PCI = partial coherence interferometry; *r* = correlation coefficient; UBM = ultrasound biomicroscopy

($P < .05$; $n = 27$). Moreover, Elbaz et al.¹⁷ report a mean ACD of 3.014 mm and 3.113 mm, respectively ($P < .01$; $n = 11$). However, in those studies, the ACD was measured from the corneal surface to the anterior surface of the lens with the PCI biometer. If CCT were subtracted from their ACD measurements, their

results would also indicate that the IOLMaster PCI biometer measures a longer ACD than the Pentacam Scheimpflug device.

Our findings are in agreement those of with Dinc et al.,¹⁸ who measured the ACD from the corneal endothelium to the anterior surface of the lens and found

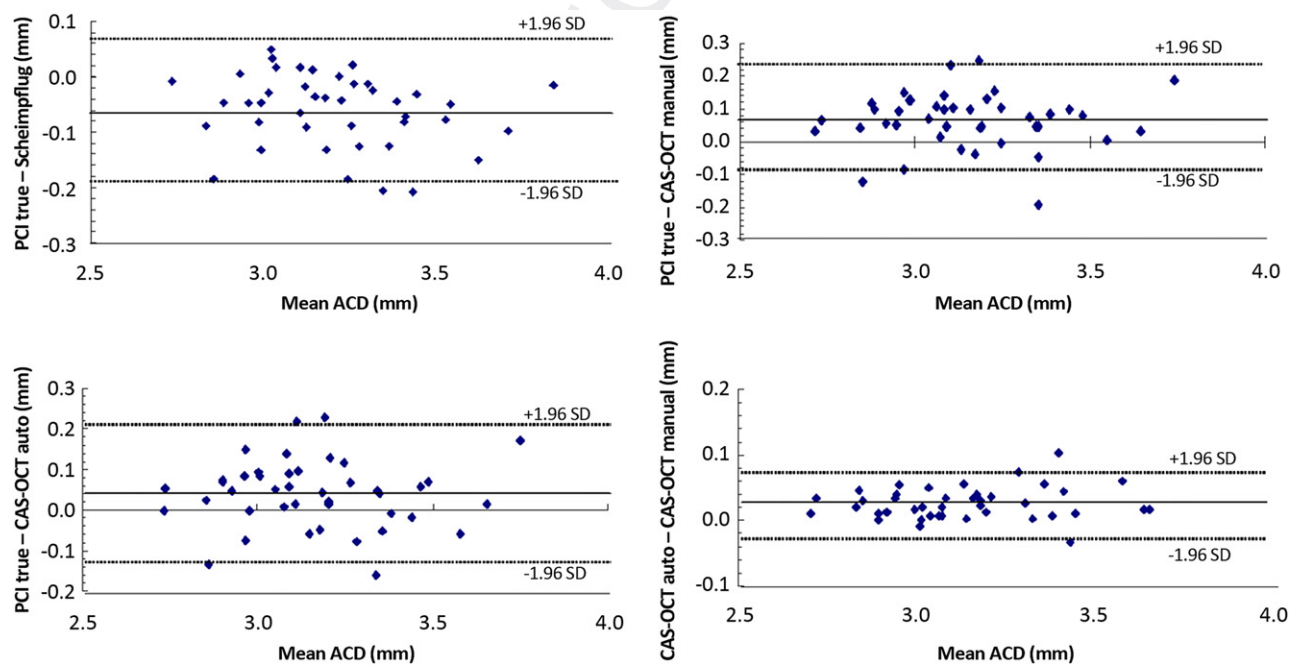


Figure 3. The mean and mean \pm 1.96 SD for PCI true, Scheimpflug, CAS-OCT auto, and CAS-OCT manual ACD measurements (ACD = anterior chamber depth; CAS-OCT = corneal and anterior segment optical coherence tomography; PCI = partial coherence interferometry) (Bland-Altman plots).

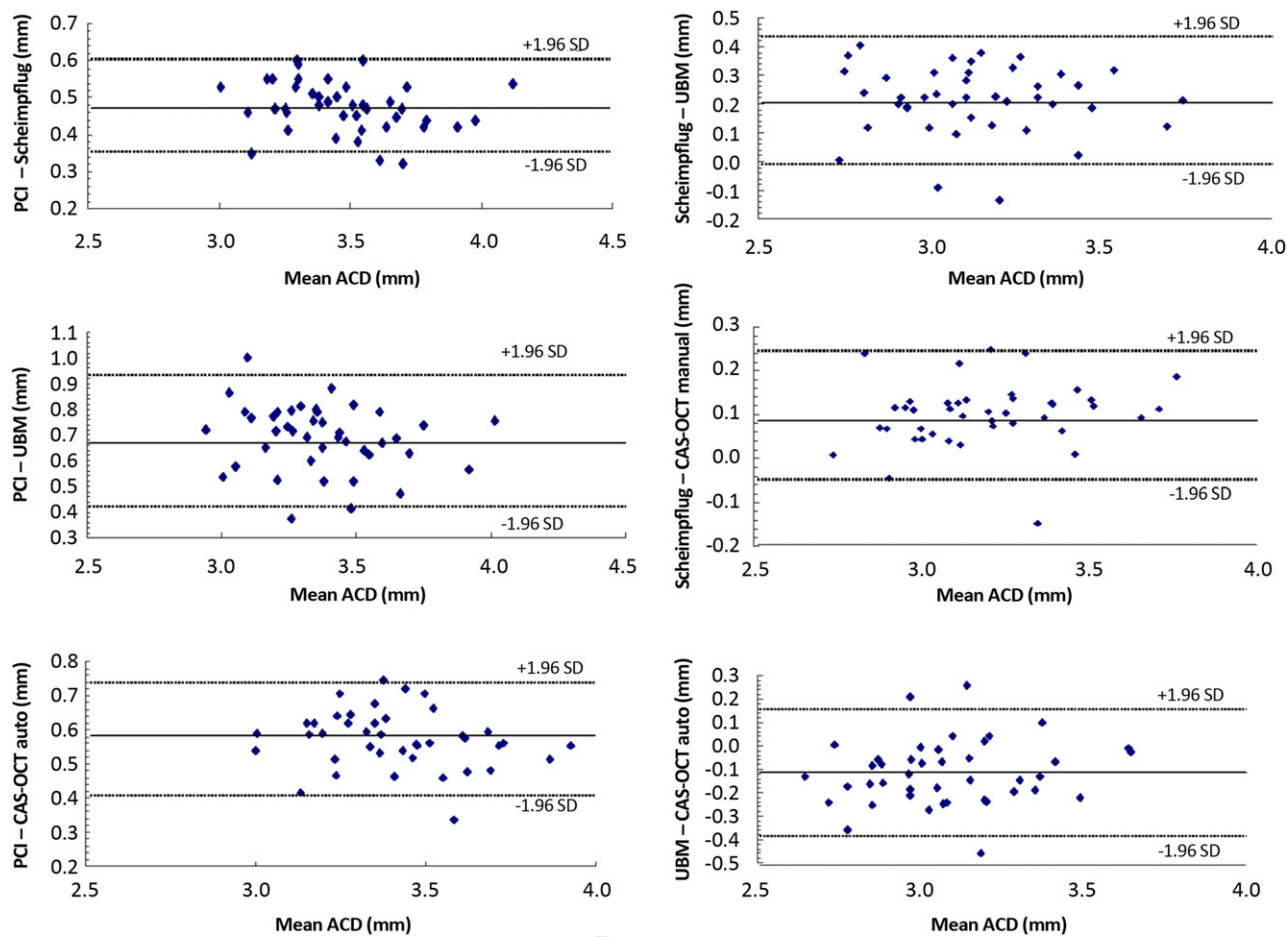


Figure 4. The mean and mean \pm 1.96 SD for PCI, Scheimpflug, UBM, and CAS-OCT auto ACD measurements (ACD = anterior chamber depth; CAS-OCT = corneal and anterior segment optical coherence tomography; PCI = partial coherence interferometry; UBM = ultrasound biomicroscopy) (Bland-Altman plots).

a mean ACD of 3.33 mm using the IOLMaster PCI biometer, 2.93 mm using the Pentacam Scheimpflug camera, and 2.98 mm using the Visante OCT device (Carl Zeiss Meditec) ($n = 40$). In our study, the IOLMaster PCI measurements were longer than the Pentacam Scheimpflug measurements (3.71 mm versus 3.24 mm; 95% CI, 0.433-0.517), whereas the PCI true measurements were shorter than the Scheimpflug device measurements (3.24 mm versus 3.18 mm; 95% CI, 0.018-0.102). Therefore clinicians should take care when interpreting clinical studies that refer to the “true” ACD with the IOLMaster PCI biometer; the corresponding PCI biometer and PCI biometer (true) measurements provided a longer or a shorter ACD.

In our study, the ACD measured by UBM was the shortest of the 6 measurements. This suggests that it is difficult to identify the top of the corneal surface during UBM testing. Moreover, the patient's fixation is not confirmed because there is no internal fixation target. These factors may cause underestimation of the ACD using the UBM method. Previous studies found that

the ACD was slightly overestimated by 0.07 to 0.09 mm using Visante AS-OCT compared with UBM in phakic eyes.^{19,20} Piñero et al.²⁰ concluded that AS-OCT and UBM had good agreement (95% LoA width 0.18 mm) and can be used interchangeably. However in our study, the 95% LoA between CAS-OCT auto and UBM and between CAS-OCT manual and UBM were 0.535 mm and 0.526 mm, respectively. Contradictory to results in previous reports, the agreements in our study were unsatisfactory. We assume this discrepancy was the result of the difference between time-domain OCT and Fourier-domain OCT.

There was no significant difference between PCI biometer true and AS-OCT auto or between CAS-OCT auto and CAS-OCT manual on post hoc analysis. In addition, the Bland-Altman spots showed good agreement. Therefore, we suggest these measurements can be used interchangeably.

On the basis our results we suggest that our data provide an index for comparison of devices that are used to measure ACD as follows: (1) Pentacam – 0.06 mm

551 \approx IOLMaster true; (2) IOLMaster true = CAS-OCT
552 auto; (3) IOLMaster true - 0.065 mm \approx AS-OCT man-
553 ual; (4) CAS-OCT auto = CAS-OCT manual.

554 We are confident that the results in our study will be
555 useful to clinicians when comparing ACD measure-
556 ments taken with these devices. However, the ques-
557 tion remains as to which device provides the most
558 accurate ACD measurements. This is a difficult and
559 important problem because each device has a unique
560 mechanism for measuring ACD and as a result, they
561 produce statistically different ACD measurements.
562 On the basis of our results, we believe that most accu-
563 rate ACD measurements are obtained using the PCI
564 biometer true and CAS-OCT auto measurements be-
565 cause this combination was the only interchangeable
566 pair among the 4 devices. On the other hand, the least
567 accurate ACD was obtained using UBM because of the
568 difficulty in obtaining accurate ACD measurements
569 with this technology.

570 In this study, we used CCT measurements from the
571 CAS-OCT device but not the Scheimpflug device. This
572 is because Fukuda et al.¹⁵ found that that the Scheimp-
573 flug camera yielded significantly higher values than
574 CAS-OCT, scanning-slit topography, and ultrasound
575 pachymetry ($P < .0001$). This discrepancy may be
576 caused by the mechanism of CCT measurement by
577 the Scheimpflug device, which measures CCT be-
578 tween the air-tear film interface and posterior corneal
579 surface.²¹ We predict that CCT measurements using
580 CAS-OCT would be more reliable than Scheimpflug
581 for obtaining real CCT measurements.

582 Our study was limited in that we used subjects with
583 phakic eyes; thus, our data cannot be directly com-
584 pared with results in subjects with pseudophakic
585 eyes. Previously, Zhang et al.²² found greater repro-
586 ducibility of measurements between AS-OCT and
587 UBM in phakic eyes than in pseudophakic eyes and
588 stated that the measurements with the 2 devices
589 should not be used interchangeably in pseudophakic
590 eyes. Another limitation of our study was that we
591 did not evaluate the possibility of a discrepancy be-
592 tween time-domain OCT and Fourier-domain OCT.
593 Further study of this possibility would contribute to
594 the field.

595 In conclusion, we measured the ACD using 4 de-
596 vices and found a significant differences between the
597 IOLMaster PCI, Pentacam Scheimpflug, HiScan
598 UBM, and SS-1000 Casia AS-OCT devices. Although
599 highly correlated, these instruments should not be
600 used interchangeably for the assessment of ACD.
601 The only measurements that can be used interchange-
602 ably are the IOLMaster PCI biometer true and
603 CAS-OCT auto and the CAS-OCT auto and CAS-
604 OCT manual. Therefore, based on our data, clinicians
605 should exercise caution when measuring ACD.

WHAT WAS KNOWN

- Anterior chamber depth has been recognized as an impor-
tant ocular biometry measure in angle-closure glaucoma
as well as for corrective surgeries.

WHAT THIS PAPER ADDS

- We determined that ACD measurements obtained from
IOLMaster, Pentacam, Casia CAS-OCT, and HiScan UBM
devices differ significantly and are not interchangeable.
- On the basis of our results, we provide an index for com-
parison with other devices in the text that is intended to
allow clinicians to compare the ACD measurements given
by these devices.

REFERENCES

1. Nonaka A, Iwawaki T, Kikuchi M, Fujihara M, Nishida A, Kurimoto Y. Quantitative evaluation of iris convexity in primary angle closure. *Am J Ophthalmol* 2007; 143:695–697
2. Saxena R, Boekhoorn SS, Mulder PGH, Noordzij B, van Rij G, Luyten GPM. Long-term follow-up of endothelial cell change after Artisan phakic intraocular lens implantation. *Ophthalmology* 2008; 115:608–613
3. Oslen T. Prediction of intraocular lens position after cataract extraction. *J Cataract Refract Surg* 1986; 12:376–379
4. Holladay JT, Prager TC, Chandler TY, Musgrove KH, Lewis JW, Ruiz RS. A three-part system for refining intraocular lens power calculations. *J Cataract Refract Surg* 1988; 14:17–24
5. Lavanya R, Teo L, Friedman DS, Aung HT, Baskaran M, Gao H, Alfred T, Seah SK, Kashiwagi K, Foster PJ, Aung T. Comparison of anterior chamber depth measurements using the IOLMaster, scanning peripheral anterior chamber depth analyzer, and anterior segment optical coherence tomography. *Br J Ophthalmol* 2007; 91:1023–1026. Available at: <http://www.ncbi.nlm.nih.gov/pmc/articles/PMC1954805/pdf/1023.pdf>. Accessed March 26, 2012
6. Landers J, Goggin M. Comparison of refractive outcomes using immersion ultrasound biometry and IOLMaster biometry. *Clin Exp Ophthalmol* 2009; 37:566–569
7. Buehl W, Stojanac D, Sacu S, Drexler W, Findl O. Comparison of three methods of measuring corneal thickness and anterior chamber depth. *Am J Ophthalmol* 2006; 141:7–12
8. Böker T, Sheqem J, Rauwolf M, Wegener A. Anterior chamber angle biometry: a comparison of Scheimpflug photography and ultrasound biomicroscopy. *Ophthalmic Res* 1995; 27(suppl):104–109
9. Su P-F, Lo AY, Hu C-Y, Chang S-W. Anterior chamber depth measurement in phakic and pseudophakic eyes. *Optom Vis Sci* 2008; 85:1193–1200. Available at: http://journals.lww.com/optvissci/Fulltext/2008/12000/Anterior_Chamber_Depth_Measurement_in_Phakic_and.13.aspx. Accessed March 26, 2012
10. Kawamorita T, Uozato H, Kamiya K, Shimizu K. Relationship between ciliary sulcus diameter and anterior chamber diameter and corneal diameter. *J Cataract Refract Surg* 2010; 36: 617–624
11. Dougherty PJ, Rivera RP, Schneider D, Lane SS, Brown D, Vukich J. Improving accuracy of phakic intraocular lens sizing

- 661 using high-frequency ultrasound biomicroscopy. *J Cataract*
 662 *Refract Surg* 2011; 37:13–18
- 663 12. Lee JY, Kim J-H, Kim H-M, Song J-S. Comparison of anterior
 664 chamber depth measurement between Orbscan IIz and ultra-
 665 sound biomicroscopy. *J Refract Surg* 2007; 23:487–491
- 666 13. Lackner B, Schmidinger G, Skorpik C. Validity and repeatability
 667 of anterior chamber depth measurement with Pentacam
 668 and Orbscan. *Optom Vis Sci* 2005; 82:858–861. Available at:
 669 [http://pdfs.journals.lww.com/optvissci/2005/09000/Validity_and_](http://pdfs.journals.lww.com/optvissci/2005/09000/Validity_and_Repeatability_of_Anterior_Chamber.16.pdf)
 670 [Repeatability_of_Anterior_Chamber.16.pdf](http://pdfs.journals.lww.com/optvissci/2005/09000/Validity_and_Repeatability_of_Anterior_Chamber.16.pdf). Accessed March
 671 26, 2012
- 672 14. Fukuda S, Kawana K, Yasuno Y, Oshika T. Repeatability and
 673 reproducibility of anterior chamber volume measurements using
 674 3-dimensional corneal and anterior segment optical coherence
 675 tomography. *J Cataract Refract Surg* 2011; 37:461–468
- 676 15. Fukuda S, Kawana K, Yasuno Y, Oshika T. Anterior ocular
 677 biometry using 3-dimensional optical coherence tomography.
 678 *Ophthalmology* 2009; 116:882–889
- 679 16. Meinhardt B, Stachs O, Stave J, Beck R, Guthoff R. Evaluation
 680 of biometric methods for measuring the anterior chamber depth
 681 in the non-contact mode. *Graefes Arch Clin Exp Ophthalmol*
 682 2006; 244:559–564
- 683 17. Elbaz U, Barkana Y, Gerber Y, Avni I, Zadok D. Comparison of
 684 different techniques of anterior chamber depth and keratometric
 685 measurements. *Am J Ophthalmol* 2007; 143:48–53
- 686 18. Dinc UA, Gorgun E, Oncel B, Yenerel MN, Alimgil L. Assessment
 687 of anterior chamber depth using Visante optical coherence to-
 688 mography, slitlamp optical coherence tomography, IOL Master,
 689 Pentacam and Orbscan IIz. *Ophthalmologica* 2010; 224:341–
 690 346. Available at: [http://content.karger.com/ProdukteDB/](http://content.karger.com/ProdukteDB/produkte.asp?Aktion=ShowPDF&ArtikelNr=313815&Ausgabe=254144&ProduktNr=224269&filename=313815.pdf)
 691 [produkte.asp?Aktion=ShowPDF&ArtikelNr=313815&Ausgabe=](http://content.karger.com/ProdukteDB/produkte.asp?Aktion=ShowPDF&ArtikelNr=313815&Ausgabe=254144&ProduktNr=224269&filename=313815.pdf)
 692 [254144&ProduktNr=224269&filename=313815.pdf](http://content.karger.com/ProdukteDB/produkte.asp?Aktion=ShowPDF&ArtikelNr=313815&Ausgabe=254144&ProduktNr=224269&filename=313815.pdf). Ac-
 693 cessed March 26, 2012
- 694 19. Dada T, Sihota R, Gadia R, Aggarwal A, Mandal S, Gupta V.
 695 Comparison of anterior segment optical coherence tomography
 696 and ultrasound biomicroscopy for assessment of the anterior
 697 segment. *J Cataract Refract Surg* 2007; 33:837–840
- 698 20. Piñero DP, Plaza AB, Alió JL. Anterior segment biometry with 2
 699 imaging technologies: very-high-frequency ultrasound scanning
 700 versus optical coherence tomography. *J Cataract Refract Surg*
 701 2008; 34:95–102
- 702 21. Amano S, Honda N, Amano Y, Yamagami S, Miyai T,
 703 Samejima T, Ogata M, Miyata K. Comparison of central corneal
 704 thickness measurements by rotating Scheimpflug camera,
 705 ultrasonic pachymetry, and scanning-slit corneal topography.
 706 *Ophthalmology* 2006; 113:937–941
- 707 22. Zhang Q, Jin W, Wang Q. Repeatability, reproducibility, and
 708 agreement of central anterior chamber depth measurements in
 709 pseudophakic and phakic eyes: optical coherence tomography
 710 versus ultrasound biomicroscopy. *J Cataract Refract Surg*
 711 2010; 36:941–946



First author:
 Shunsuke Nakakura, MD, PhD
 Department of Ophthalmology,
 Saneikai Tsukazaki Hospital,
 Himeji, Japan

print & web 4C/FPO