

## Histological Observations on the Quail Oviduct; Histochemical Observations on the Secretions of the Glands and the Mucous Cells

Tatsudo TAMURA and Shunsaku FUJII

*Department of Animal Husbandry, Faculty of Fisheries and Animal Husbandry  
Hiroshima University*

(Tables 1-2; Plates 1-6)

As cited by ROMANOFF and ROMANOFF<sup>1)</sup> (1949), up to that time, some relationships between each component of the egg and the every region of the oviduct of the domestic fowl had been tolerably clearly interpreted. The surface epithelium in the mucous membrane and the glands in the oviduct of the fowl were observed histologically by many previous workers including SURFACE<sup>2)</sup> (1912), GIERSBERG<sup>3)</sup> (1923), BRADLEY<sup>4)</sup> (1928), RICHARDSON<sup>5)</sup> (1935), CHAKRAVARTI and SADHU<sup>6)</sup> (1961), AITKEN and JOHNSTON<sup>7)</sup> (1963), JOHNSTON *et al.*<sup>8)</sup> (1963), FUJII<sup>9)</sup> (1963) and FUJII *et al.*<sup>10)</sup> (1965).

In recent years, the elucidation of functions of various tissues and organs has made a great progress from the point of the histochemical view. However, the histochemical reports on the surface epithelium and the glands in the oviduct of the domestic fowl are not enumerated so much as the former (BRADLEY<sup>4)</sup>, 1928; RICHARDSON<sup>5)</sup>, 1935; CHAKRAVARTI and SADHU<sup>6)</sup>, 1961; JOHNSTON *et al.*<sup>8)</sup>, 1963; FUJII<sup>9)</sup>, 1963; FUJII *et al.*<sup>10)</sup>, 1965).

Consequently, the authors intended to observe the oviduct of the fowl in detail, with reference to the mucous cells in the surface epithelium and the glands from the standpoint of histochemistry, and tried to make clear the function of each region of the oviduct more exactly.

This paper deals with some distinctive marks in histochemical observations on the secretion materials of the mucous cells and the glands in the oviduct of the quail.

### MATERIALS AND METHODS

The tissues of each region of the oviduct, the infundibulum, magnum, isthmus, uterus and vagina were obtained from 36 cases of the Japanese quail belonging to various egg formation stages. The specimens were fixed in the following fixatives: CARNOY'S, BOUIN'S, 10% neutral formol, alcohol-formol, trichloroacetic acid-formol, alcohol, acetone, and ZENKER-formol. Then, they were embedded in paraffin. And the thin sections at 5-7 $\mu$  in thickness were made.

Staining methods and procedures used are as follows:

1. Hematoxylin-eosin

2. HEIDENHAIN's azan
3. Chrome alum hematoxylin (CH) (GOMORI<sup>11</sup>), 1941)
4. Alcian blue (AB) (MOWRY<sup>12</sup>), 1956)
5. Periodic acid-SCHIFF (PAS) (MCMANUS<sup>13</sup>), 1948)
6. Alcian blue-periodic acid SCHIFF (AB-PAS) (MOWRY and WINKLER<sup>14</sup>), 1956)
7. Periodic acid-phenylhydrazine-SCHIFF (PAPS) (SPICER<sup>15</sup>), 1961)
8. Aldehyde fuchsin (AF) (HALMI<sup>16</sup>), 1951)
9. Aldehyde fuchsin-Alcian blue (AF-AB) and Alcian blue-aldehyde fuchsin (AB-AF) (SPICER and MEYER<sup>17</sup>), 1960)
10. Metachromasia with azure A buffered at pH 5.0 to 0.5 (SPICER and DUVENCI<sup>18</sup>), 1964)
11. Mercury-bromphenol blue (HgBPB) (BONHAG<sup>19</sup>), 1955)
12. Ninhydrin-SCHIFF (NS) (YASUMA and ICHIKAWA<sup>20</sup>), 1953)
13. Performic acid-SCHIFF (PFAS) (PEARSE<sup>21</sup>), 1951)
14. Performic acid-Alcian blue (PFAAB) (ADAMS and SLOPER<sup>22</sup>), 1956)
15. Salivary digestion (ARCADI<sup>23</sup>), 1952)

## RESULTS

Throughout the mucous membrane in the oviduct, the surface epithelium was consisted of mucous cells and ciliated cells, which were arranged reciprocally, with the exceptions of the anterior infundibulum and the vagina. In the anterior infundibulum, the epithelium lacked in mucous cells. And in the vagina, the mucous cells were irregularly dispersed in the epithelium being mainly consisted of ciliated cells (Figs. 14, 15). Each of glands of the oviduct was situated in the lamina propria of the folds, except missing gland in the anterior infundibulum and the posterior vagina (Fig. 15). Morphologically, among five regions, viz., infundibulum, magnum, isthmus, uterus and vagina, the mucous cells showed the highest development in the magnum (Figs. 9, 10), especially in the posterior end portion which was identified to the "mucous region" named by RICHARDSON<sup>5</sup> (1935) in the domestic fowl. In the infundibulum (Figs. 6, 8) and the isthmus (Figs. 11, 12), they were presented in the stage of average development. Contrasting to these anterior regions of the oviduct, in the uterus (Fig. 13) and the vagina (Figs. 14, 15), however, they were slender and smaller.

Amongst the glands of the oviduct, secretion granules were found in those of the posterior infundibulum (Fig. 8), magnum (Figs. 9, 10) and the anterior isthmus (Fig. 11). In other glands, namely, in the middle infundibulum (Fig. 7), posterior isthmus (Fig. 12), uterus (Fig. 13) and the vagina (Fig. 14), the secretion granules were not found.

As far as the mucous cells and glands were concerned, those morphological aspects and the manners of distribution were similar to the results in the domestic fowl described by RICHARDSON<sup>5</sup> (1953) and FUJII *et al.*<sup>10</sup> (1965).

The histochemical observations were obtained from the secretion materials

(mucin) of the mucous cells in each region, and form the secretion granules of such glands. These histochemical results are illustrated in Tables 1 and 2.

Table 1. Reactions of Mucins

| Regions & Subdivisions | Infundibulum        | Magnum                |               | Isthmus  |           | Uterus                | Vagina                |
|------------------------|---------------------|-----------------------|---------------|----------|-----------|-----------------------|-----------------------|
|                        | Middle to Posterior | Anterior to Posterior | Mucous Region | Anterior | Posterior | Anterior to Posterior | Anterior to Posterior |
| CH                     | ###                 | ++                    | +             | +~++     | ###       | +                     | -                     |
| PAS                    | ###                 | ###                   | ###           | ###      | ###       | +                     | ++                    |
| AB                     | ###                 | ++~###                | ###           | -        | -         | ++                    | -                     |
| AB-PAS                 | AB                  | AB                    | AB            | PAS      | PAS       | AB                    | PAS                   |
| PAPS                   | ++                  | ++                    | ++            | -        | -         | ±                     | -                     |
| Metachromasia          |                     |                       |               |          |           |                       |                       |
| pH 5.0                 | ###                 | ++                    | ###           | -        | -         | +                     | -                     |
| pH 3.5                 | ###                 | ++                    | ###           | -        | -         | ±                     | -                     |
| pH 2.0                 | ###                 | ±                     | ###           | -        | -         | -                     | -                     |
| pH 1.0                 | ++                  | -                     | +             | -        | -         | -                     | -                     |
| pH 0.5                 | +                   | -                     | -             | -        | -         | -                     | -                     |
| AF                     | ###                 | ++~###                | ###           | -        | -         | +                     | -                     |
| HgBPB                  | ±                   | ±                     | ±             | +        | +         | +                     | ?                     |
| NS                     | ±                   | ±                     | ±             | +        | +         | +                     | ?                     |
| PFAAB                  | ++                  | ++                    | ++            | +        | ++        | +                     | +                     |
| PFAS                   | -                   | -                     | -             | -        | -         | -                     | -                     |

Remarks in Reactions: -; negative, ±; doubtful, +; weakly positive, ++; moderate, ### and ###; strong, ?; undistinguishable mucous cells in the epithelium.

Table 2. Reactions of Secretions in Glands

| Regions and Glands                  | Presence of Secretions | Methods and Reactions |     |      |         |     |       |      |
|-------------------------------------|------------------------|-----------------------|-----|------|---------|-----|-------|------|
|                                     |                        | CH                    | PAS | PAPS | HgBPB   | NS  | PFAAB | PFAS |
| Infundibulum                        |                        |                       |     |      |         |     |       |      |
| Gland in the Middle Infundibulum    | -                      | .....                 |     |      |         |     |       |      |
| Gland in the Posterior Infundibulum | +                      | ++                    | ++  | -    | ###     | ++  | -     | -    |
| Magnum                              |                        |                       |     |      |         |     |       |      |
| Gland in the Whole Magnum           | +                      | ++                    | ++  | -    | ###     | ++  | -     | -    |
| Isthmus                             |                        |                       |     |      |         |     |       |      |
| Gland in the Anterior Isthmus       | +                      | ###                   | ### | -    | ###~### | ### | ###   | +    |
| Gland in the Posterior Isthmus      | -                      | .....                 |     |      |         |     |       |      |
| Uterus                              |                        |                       |     |      |         |     |       |      |
| Gland in the Whole Uterus           | -                      | .....                 |     |      |         |     |       |      |
| Vagina                              |                        |                       |     |      |         |     |       |      |
| Gland in the Anterior Vagina        | -                      | .....                 |     |      |         |     |       |      |

Remarks in Reactions: -; negative, +; weakly positive, ++; moderate, ### and ###; strong

With CH stain used as an ordinary mucin stain, the mucins of the mucous cells in the infundibulum (Fig. 1), magnum (Fig. 2) and the posterior isthmus were strongly stained. The mucins in the infundibulum (Figs. 6, 8) and the magnum (Figs. 9, 10) were strongly stained respectively with PAS method (that is, PAS-positive or PAS-reactive) as well as with AB stain (that is, AB-positive or AB-stainable). These mucins were AB-positive with AB-PAS procedure. In the isthmus (Figs. 11, 12), the mucin was strongly PAS-positive with the PAS method as well as with the AB-PAS procedure, but negative with the AB stain. In the uterus (Fig. 13), the mucin was weakly PAS-positive with the PAS method, however, somewhat strongly AB-positive, with the AB as well as the AB-PAS procedure. On the contrary to the uterus, the mucin in the vaginal mucous cells (Figs. 14, 15) dispersed in the epithelium were PAS-positive with both the PAS and the AB-PAS.

Corresponding with the AB-positivity, metachromasia of the mucous cells were presented clearly in the infundibulum (Figs. 16, 17), magnum (Figs. 18, 19) and weakly in the uterus. It was characteristic that, among these regions, the metachromasia in the infundibulum was observed at pH 0.5 of the most acidic level, and that the mucin in the mucous region induced it at pH 2.0 of lower level than the other portions of the region. With PAPS procedure, the mucous cells in the infundibulum and magnum (Fig. 20) almost perfectly retained the PAS-reactivity. On the contrary, however, in those of the isthmus and the vagina there was no trace. Also, AF stain induced positive reactions to the mucins in the infundibulum, magnum (Figs. 22, 23) and uterus.

The stainabilities with HgBPB method for proteins and with NS method for amino-radical were parallel in each of the mucous cells; that is, in the infundibulum (Fig. 24) and magnum (Figs. 26, 29) the mucins were scarcely negative, however, in the isthmus (Figs. 27, 30) and uterus (Figs. 28, 31) stained similar as the coloration of the cytoplasm with both methods. With PFAAB procedure for cystine and cystine-compounds, the mucins of all kinds of these mucous cells reacted and were stained in blue to bluish-green colors (Figs. 32 to 35).

The secretion granules in the above-mentioned glands were PAS-positive (Figs. 8, 9, 10, 11) and the reactive colors disappeared with the PAPS procedure (Fig. 23). All of them were stained with the methods of CH (Fig. 4), HgBPB (Figs. 25, 26, 27) and NS (Figs. 29, 30), and in these, the granules of the gland in the anterior isthmus were more strongly stained showing sharp profiles of the granular structures. Specifically, the granules of this gland were clearly stained with the PFAAB procedure (Fig. 34). With PFAS procedure for sulphur amino-groups, also, they were stained in somewhat paler color (Fig. 36). Therefore, the gland of the anterior isthmus was characterized on the basis of these specificities.

## DISCUSSION

In the quail oviduct, the mucous cells were found continuously from the middle infundibulum to the vagina. Their morphological characters and the manners of the



distribution in each region were corresponded with the results gained in the domestic fowl by BRADLEY<sup>4)</sup> (1928), RICHARDSON<sup>5)</sup> (1935) and FUJII *et al.*<sup>10)</sup> (1965). On the basis of the development and the number of the mucous cells distributed in each region, quantities of the mucins released from these mucous cells are regarded as maximum in the magnum and followed by, in order, in the isthmus, infundibulum, uterus and minimum in the vagina. In the quail, also, the mucous region (RICHARDSON<sup>5)</sup>, 1935) which showed the highest development of the mucous cells, was found in the posterior end portion of the magnum.

Amongst glands in the oviduct, the secretion granules were found in each gland of the posterior infundibulum, magnum and anterior isthmus, as far as with the methods used this time. RICHARDSON<sup>5)</sup> (1935) described the charaziferous gland containing secretion materials in the middle infundibulum in the domestic fowl. In the quail, however, the gland in the middle infundibulum did not present any secretion materials stained. As well as RICHARDSON<sup>5)</sup> (1935), the gland in the posterior infundibulum in the quail continued, without histological boundary, to the gland in the magnum, so-called albumen-secreting gland. These two glands situated in the different portions were regarded as the same one.

Conclusively speaking, the mucin of the mucous cells in each region was characterized in the reactions for polysaccharides or mucopolysaccharides. In former time, BRADLEY<sup>4)</sup> (1928) and RICHARDSON<sup>5)</sup> (1935) reported respectively that the mucins in the regions of the infundibulum, the magnum and the isthmus were strongly stained, in the vagina somewhat weakly, but in the uterus scarcely unstained with basic dyes. In the quail, in comparison with them, the mucins in the infundibulum, magnum and posterior isthmus are strongly stained, in the uterus somewhat weakly, but in the vagina unstained with the CH stain.

In the present investigation, the techniques of PAS, AB-PAS, PAPS, buffered azure A and AF were used for the examinations of polysaccharides of these mucins. Acid mucopolysaccharides are considered as AB-positive with the AB stain as well as the AB-PAS procedure, on the other hand, neutral mucopolysaccharides are as PAS-positive with the PAS as well as the AB-PAS (MOWRY<sup>12)</sup>, 1956; MOWRY and WINKLER<sup>14)</sup>, 1956; MOWRY and MORAND<sup>24)</sup>, 1957; SPICER<sup>15)</sup>, 1961). Moreover, with the PAPS procedure, the PAS-reactivity of the neutral mucopolysaccharides is blocked by phenylhydrazine, with the disappearance of the PAS-positive red color, but the reactivity of the acid mucopolysaccharides is not blocked (SPICER<sup>15)</sup>, 1961). In conformity with these conceptions, the above-mentioned results admits of the interpretations as the mucins in the mucous cells of the infundibulum, magnum and the uterus contain acid mucopolysaccharides, while those of the isthmus and the vagina neutral mucopolysaccharides. And in consequence, the characters of the mucins both in the uterus and vagina of the quail are in marked contrast with those in the domestic fowl. CHAKRAVARTI and SADHU<sup>6)</sup> (1961) reported, on the domestic fowl, that the mucins in the uterus and the vagina were acid mucopolysaccharides, and JOHNSTON *et al.*<sup>8)</sup> (1963) distinguished two types of the mucous cells in the uterus of the domestic fowl; the cells in the anterior portion containing acid mucopolysac-

charide and others in the posterior neutral mucopolysaccharide. Thus, the results with respect to the mucopolysaccharides in the uterus and the vagina show dispersities by workers.

Metachromasia with the buffered azure A was found strongly in the mucous cells of the infundibulum, magnum and weakly in those of the uterus. It is noticed that the metachromasia in every region is induced at different pH levels, and especially in the infundibulum, it was found at the lowest pH 0.5. FUJII *et al.*<sup>10)</sup> (1965) mentioned on the domestic fowl that the mucin of the mucous region showed metachromasia at the lowest pH in the oviduct. On what factors did the differences of pH level inducing metachromasia depend were not examined excepting the AF method for sulfated mucopolysaccharides.

SPICER and MEYER<sup>17)</sup> (1960) referred to the fact that in the acid mucopolysaccharides, the AF-reactivity was caused by sulphyl radical in the polymer composing acid mucopolysaccharide. In the quail oviduct, all of the acid mucopolysaccharides in the mucous cells of the infundibulum, magnum and uterus were stained with the AF method, and the affinities for it were parallel to the colorations with the AB stain and the metachromasia. Therefore, it is certain that, the acid mucopolysaccharide in each region of the quail oviduct contains sulfated mucopolysaccharide.

In the examinations for proteins with the HgBPB and for amino-radical with the NS method, it was found that the mucosubstances of the infundibulum and the magnum were scanty in the protein content, whereas in the isthmus and the uterus they were somewhat richer in proteins. Therefore, the mucosubstances may be regarded as mucopolysaccharides in the former regions, and mucopolysaccharide-protein complex in the latter.

With the PFAAB procedure, in spite of non-specific protein reactions, the mucous cells throughout oviduct showed specifically positive reactions. They are thought to contain cystine or cystine-compounds in their mucosubstances.

The granules of each gland were in common, according to the characters of their large structures and the stainabilities with the methods of PAS, CH, HgBPB and NS. In addition to these characters, most specifically, only in the gland of the anterior isthmus, the granules were reactive to the procedure of the PFAAB and PFAS. The former method is, in the present time, regarded as the most specific and valuable one for cystine and cystine-compounds (PEARSE<sup>25)</sup>, 1961). The specifically positive reaction with the latter method for sulphur-containing amino-acids may be assumed to support the reactions with the PFAAB method.

From the results of the present investigation on the mucous cells and the glands in the oviduct of the quail, the relationships between each component of the egg and the each region of the oviduct is not be concluded so clearly. Some conceptions, however, may be presented in them.

RICHARDSON<sup>5)</sup> (1935) mentioned that the chalaziferous layer of the egg white was secreted from the chalaziferous gland in the middle infundibulum. In the quail, however, the gland in the middle infundibulum corresponding with RICHARDSON'S<sup>5)</sup> chalaziferous gland did not expose any secretion materials in their glandular cells.

Thus, the present authors can not introduce his conception of the secretion in the gland to the quail oviduct.

The middle dense layer of the egg white has been thought to be secreted from the gland in the magnum, so-called albumen-secreting gland (BRADLEY, 1928; ASMUNDSON and JERVIS<sup>26</sup>, 1933; RICHARDSON<sup>5</sup>, 1935). Histochemically, this conception admits of no doubt, because the secretion granules are considerably richer in protein content, than the mucous cells in the region.

In spite of the investigations by numerous workers including RICHARDSON<sup>5</sup> (1935), ALMQUIST<sup>27</sup> (1936), ASMUNDSON and BURMESTER<sup>28</sup> (1936), SCOTT *et al.*<sup>29</sup> and CONRAD and PHILLIPS<sup>30</sup> (1938), the mechanism<sup>5</sup> of the formation of the inner and outer liquid layers of the egg white have involved some questions. The present authors would firstly point out the conspicuously developed mucous cells of the magnum, especially of the mucous region, as the secreting-portion of the substances. For, the liquid layers are mainly consisted of "ovomucoid" which contain much quantity of mucosubstances, and the mucous cells in the region are scanty in protein content.

It has been thought that two layers of the shell-membrane are made from the secretion materials of gland of the isthmus (GIERSBERG<sup>3</sup>, 1923; BRADLEY<sup>4</sup>, 1928; RICHARDSON<sup>5</sup>, 1935). The term of the ovokeratin composing the shell-membrane was named by ABDERHALDEN and EBSTEIN<sup>31</sup> (1906), and PLIMER and ROSEDALE<sup>32</sup> (1925) illustrated that the material was rich in cystine. Histochemically, keratin substances are identified with proving their cystine or cystine-compounds (PEARSE<sup>25</sup>, 1961). Therefore, it is seemed that the present authors' result support the opinions of the formation of the shell-membrane.

The characters of the organic matrix of the shell and the cuticle were reported by NATHUSIUS<sup>33</sup> (1868), CALVERY<sup>34</sup> (1933), ALMQUIST<sup>35</sup> (1934), STEWART (1935)<sup>36</sup>, MORAN and HALE<sup>37</sup> (1936) and SIMKISS and TYLER<sup>38</sup> (1957). These materials have been thought secreted in the uterus (BRADLEY<sup>4</sup>, 1928; RICHARDSON<sup>5</sup>, 1935). The present authors, as reported in the other paper (1966)<sup>39</sup>, refer to the fact that the mucous cells of the uterus are related with the organic matrix of the shell.

The vaginal mucous cells of the quail were undeveloped and scanty in number, so that they may be in function of lubrication as RICHARDSON<sup>5</sup> (1935).

## SUMMARY

Histochemical observations were made on the secretion materials of the mucous cells in the surface epithelium and the glands of the oviduct of the quail. The results obtained are summarized as follows:

1. The histological features were almost similar to the findings on the domestic fowl described by BRADLEY<sup>4</sup> (1928), RICHARDSON<sup>5</sup> (1935) and FUJII<sup>10</sup> *et al.* (1965). However, the secretion granules were observed in the glands in the posterior infundibulum, magnum and the anterior isthmus. In other glands including so-called chalaziferous gland (RICHARDSON<sup>5</sup>, 1955), secretion granules were

not found.

2. From the view of the reactions for the mucopolysaccharides, it was concluded that the mucous cells in the infundibulum, magnum and the uterus contained sulfated, acid mucopolysaccharides, and on the contrary to these, in the isthmus and the vagina neutral mucopolysaccharides.
3. The protein content in the mucosubstances of the mucous cells were observed scanty in the infundibulum and the magnum, and somewhat rich in the isthmus and the uterus. As a specific amino-group, the positive reaction for cystine or cystine-compounds was showed in the mucosubstances in every region.
4. The secretion granules of the glands in the posterior infundibulum, magnum and the anterior isthmus showed several common characters of polysaccharide-protein complex. Specifically, only the secretion granules of the gland in the anterior isthmus presented positive reactions for cystine or cystine-compounds.

#### REFERENCES

1. ROMANOFF, A., & A. ROMANOFF: *The Avian Egg*. 1st Edit., JOHN WILEY & SONS, New York (1949)
2. SURFACE, F.M.: *Ann. Rep. Main Agric. Exp. Station*, **206**, 395-430 (1912)
3. GIERSBERG, H.: *Z. wiss. Zool.*, **120**, 1-96 (1923)
4. BRADLEY, D.C.: *J. Anat.*, **62**, 339-345 (1928)
5. RICHARDSON, K.C.: *Trans. Roy. Soc. London*, **225** (B), 149-195 (1935)
6. CHAKRAVARTI, K.P., & D.P. SADHU: *Proc. Zool. Soc. (Calcutta)*, **14**, 27-32 (1961)
7. AITKEN, R.N.C. & H.S. JOHNSTON: *J. Anat.*, **97**, 87-99 (1963)
8. JOHNSTON, H.S., R.N.C. AITKEN & G.M. WYBURN: *J. Anat.*, **97**, 334-344 (1963)
9. FUJII, S.: *Arch. Histol. Jap.*, **23**, 447-459 (1963)
10. FUJII, S., T. TAMURA & H. KUNISAKI: *J. Fac. Fish. Anim. Husb. Hiroshima Univ.*, **6**, 25-35 (1965)
11. GOMORI, G.: *Amer. J. Pathol.*, **17**, 397-406 (1941)
12. MOWRY, R.W.: *J. Histochem Cytochem.*, **4**, 407 (1956)
13. MCMANUS: *Stain Technol.*, **23**, 999-108 (1948)
14. MOWRY, R.W., & C.H. WINKLER: *Ann. J. Pathol.*, **36**, 628 (1956)
15. SPICER, S.S.: *Ann N. Y. Acad. Sci.*, **106**, 379-388 (1961)
16. HALMI, N.S.: *Anat. Rec.*, **109**, 300 (1951)
17. SPICER, S.S., & D.B. MEYER: *Amer. J. clin. Pathol.*, **33**, 453-460 (1960)
18. SPICER, S.S., & J. DUVENCI: *Anat. Rec.*, **149**, 333-358 (1964)
19. BONHAG, P.F.: *J. Morphol.*, **96**, 381 (1955)
20. YASUMA, A., & T. ICHIKAWA: *J. lab. clin. Med.*, **41**, 296 (1953)
21. PEARSE, A.G.E.: *Quart. J. micr. Sci.*, **92**, 393-402 (1951)
22. ADAMS, C.W.M., & J.C. SLOPER: *J. Endocrinol.*, **13**, 221 (1956)
23. ARCADI, J.A.: *Anat. Rec.*, **112**, 593-607 (1952)
24. MOWRY, R.W., & J.C. MORAND: *Amer. J. Pathol.*, **33**, 620-621 (1957)
25. PEARSE, A.G.E.: *Histochemistry*, 2nd Edit., CHURCHILL, London (1961)
26. ASMUNDSON V.S., & J.G. JERVIS: *J. Exptl. Zool.*, **65**, 395-420 (1933)
27. ALMQUIST, H.J.: *Poultry Sci.*, **15**, 460-461 (1936)
28. ASMUNDSON, V.S., & B.R. BURMESTER: *J. Exptl. Zool.* **72**, 225-246 (1936)
29. SCOTT, H.M., J.S. HUGHES & D.C. WARREN: *Poultry Sci.*, **16**, 53-61 (1937)
30. CONRAD, R.M., & R.E. PHILLIPS: *Poultry Sci.*, **17**, 143-146 (1938)

31. ABDERHALDEN, E., & E. EBSTEIN: *Z. physiol. Chem.*, **48**, 531-534 (1906)
32. PLIMER, R.H.A., & J.L. ROSEDALE: *Biochem. J.*, **19**, 1004-1021 (1925)
33. NATHUSIUS, W.VON: *Z. wiss. Zoöl.*, **18**, 225-270 (1868)
34. CALVERY, H.O.: *J. Biol. Chem.*, **100**, 183-186 (1933)
35. ALMQUIST, H.J.: *Poultry Sci.*, **13**, 375 (1934)
36. STEWART, G.F.: *Poultry Sci.*, **14**, 24-32 (1935)
37. MORAN, T., & H.P. HALE: *J. Exptl. Biol.*, **13**, 35-40 (1936)
38. SIMKISS, K., & C. TYLER: *Quart. J. micr. Sci.*, **98**, 19-28 (1957)
39. TAMURA, T., & S. FUJII: *J. Fac. Fish. Anim. Husb. Hiroshima Univ.*, **6**, 357-371 (1966)

## うずら卵管の組織学的研究；腺および粘液細胞の 分泌物の組織化学的研究

田村達堂・藤井俊策

鳥類卵管における卵の形成に関しては多くの研究があり、卵管各部と卵の各構成要素との関係はほぼ明らかにされているが、細部については不明な点が残されている。したがって、卵の形成に関係すると考えられる腺と粘液細胞の分泌物について組織化学的観察をおこない、より詳細に卵の形成について明らかにしようと試みた。本報ではそれらの基本的所見を記載した。

うずら卵管における腺および粘液細胞の分布は、にわたりのそれらに類している。腺で分泌顆粒のみとめられるのは、漏斗部後位、膨大部、峽部前位の各部のものであった。粘液細胞の発達と分布から、粘液の放出量は、膨大部、峽部、漏斗部、子宮部、膣部の順と考えられる。

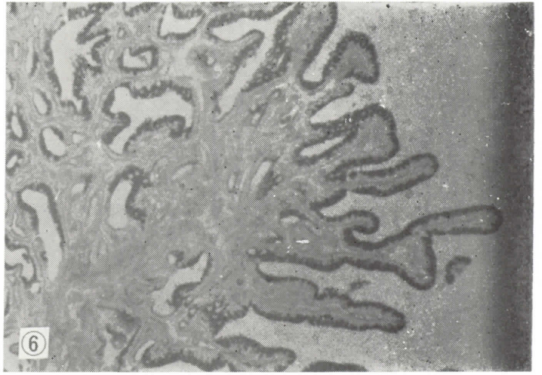
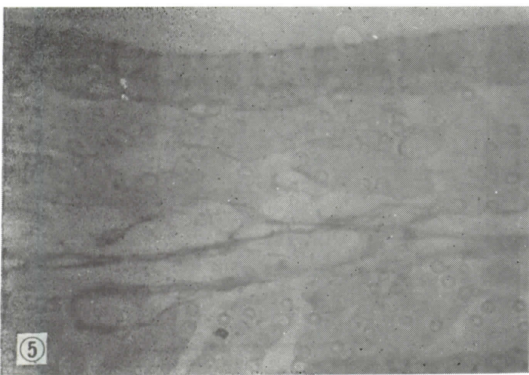
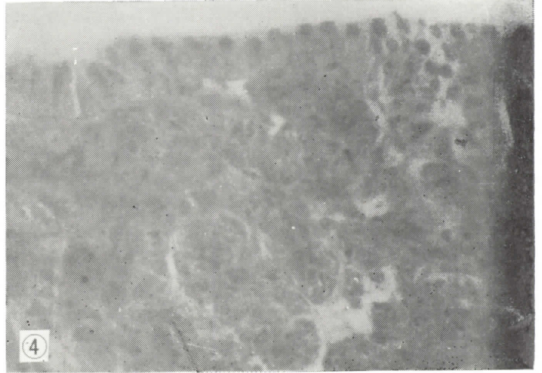
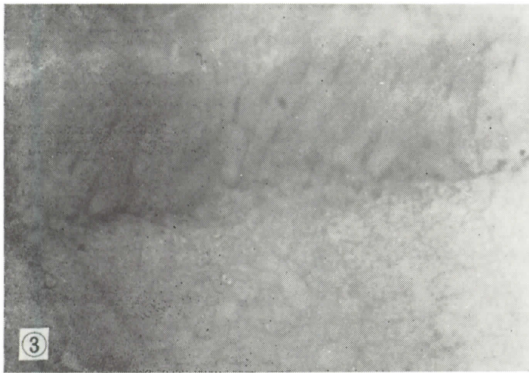
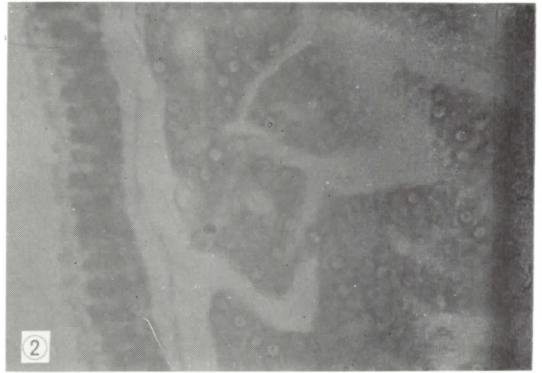
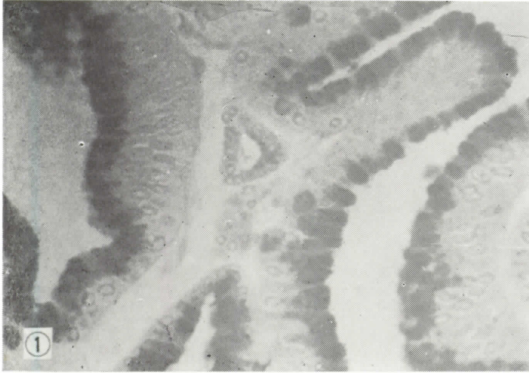
粘液は、漏斗部、膨大部、子宮部では硫酸基を含む酸性粘液多糖類、峽部、膣部では、中性粘液多糖類の性質を示した。これらの粘液物質の蛋白は、漏斗部、膨大部では乏しく、峽部、子宮部ではかなり多いことが示されたが、各部の粘液には、シスチンが含まれていることが示された。

各部の腺の分泌顆粒は、いずれも中性粘液多糖類—蛋白複合体であることを示したが、特異的に、峽部前位の腺では、その顆粒にシスチンがみとめられた。

## EXPLANATION OF FIGURES

### Plate 1

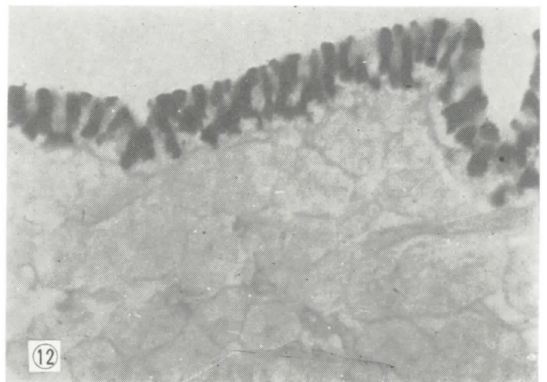
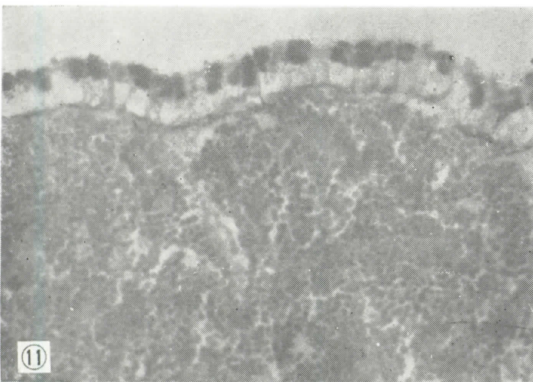
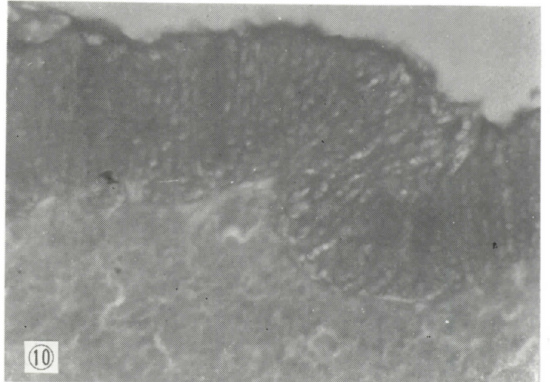
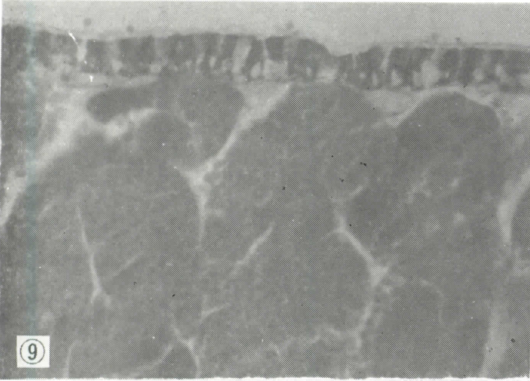
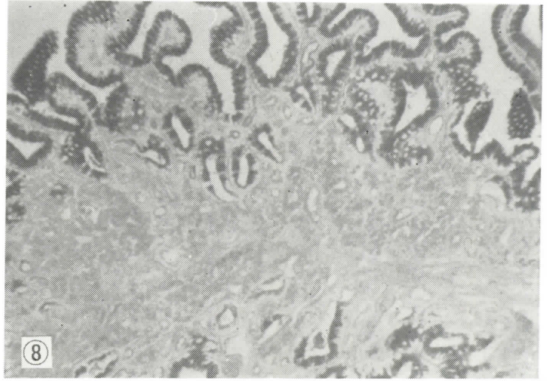
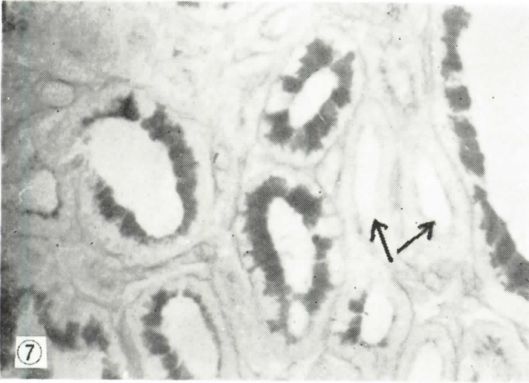
- Fig. 1. Middle portion of the infundibulum. The mucin is strongly stained. CH stain.  $\times 400$ .
- Fig. 2. Middle portion of the magnum. The mucin is strongly stained. CH stain.  $\times 400$ .
- Fig. 3. Mucous region of the magnum. The mucous cells highly developed, but their mucin is lightly stained. CH stain.  $\times 400$ .
- Fig. 4. Anterior portion of the isthmus. The mucous cells are smaller than the magnum, and the mucin is stained in middle tint. The secretion granules of the gland are strongly stained. CH stain.  $\times 400$ .
- Fig. 5. The uterus. The mucous cells are slender and their mucin is stained not so deeply. CH stain.  $\times 400$ .
- Fig. 6. Middle portion of the infundibulum. The mucin is stained with Alcian blue (AB-positive). AB-PAS procedure.  $\times 100$ .



## Plate 2

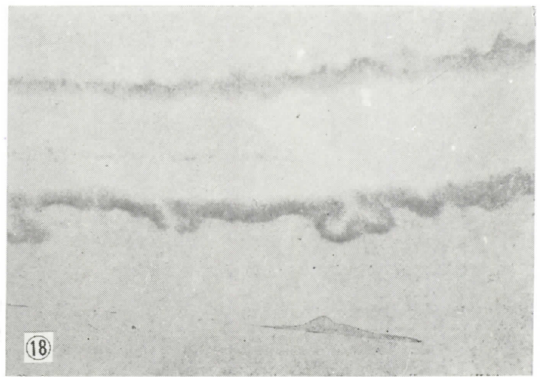
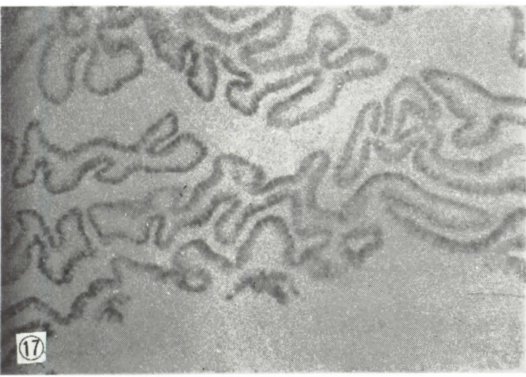
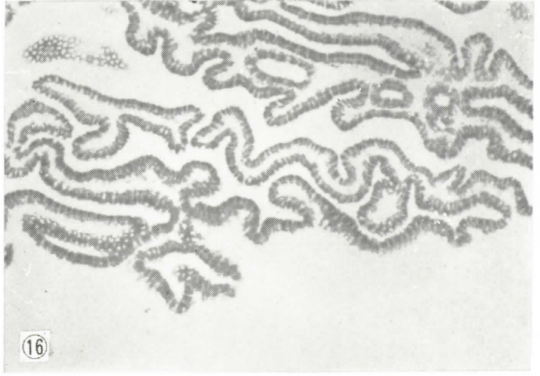
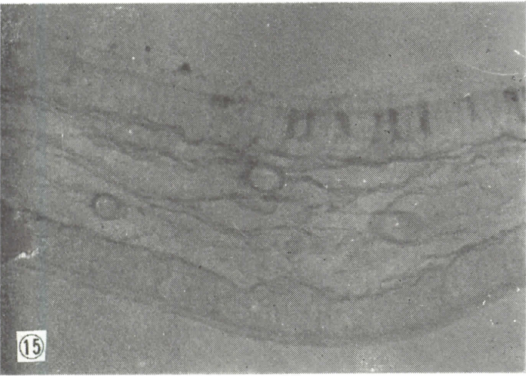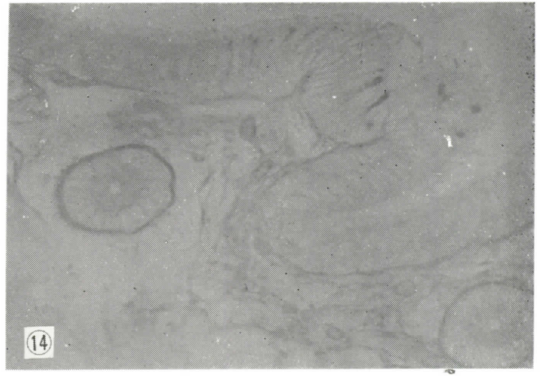
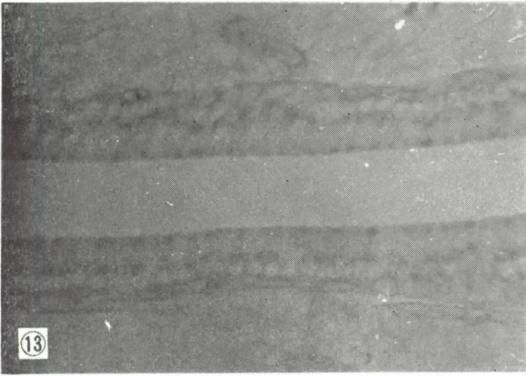
- Fig. 7. Middle portion of the infundibulum. Glandular cells of the dilated tubular gland ( $\uparrow$ ) do not contain secretion material. Gland-like sections surrounded with stained (AB-positive) cells are parts of the mucosal epithelium. AB-PAS procedure.  $\times 400$ .
- Fig. 8. Posterior portion of the infundibulum. In the broad ridge, the glandular structures containing PAS-positive secretion granules are seen. AB-PAS procedure.  $\times 100$ .
- Fig. 9. Middle portion of the magnum. The mucin is AB-positive and PAS-positive secretion granules fill the gland. AB-PAS procedure.  $\times 400$ .
- Fig. 10. Mucous region of the magnum. The mucous cells are enormously developed and the mucin is AB-positive. AB-PAS procedure.  $\times 400$ .
- Fig. 11. Anterior portion of the isthmus. The mucous cells are not so developed as in the magnum. The mucin is PAS-positive and the secretion granules in the gland are PAS-positive with their sharp profiles. AB-PAS procedure.  $\times 400$ .
- Fig. 12. Posterior portion of the isthmus. The mucous cells are highly developed and the mucin is PAS-positive. The gland do not show secretion granules. AB-PAS procedure.  $\times 400$ .





### Plate 3

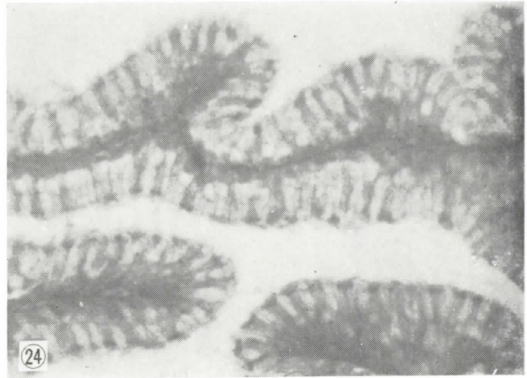
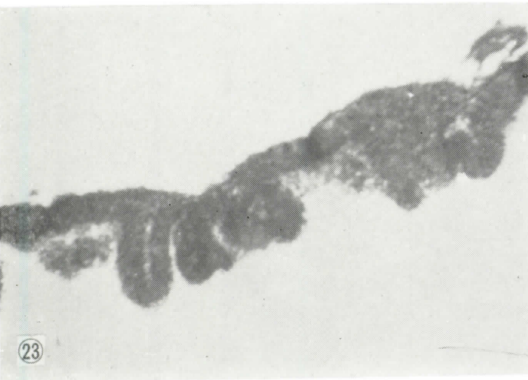
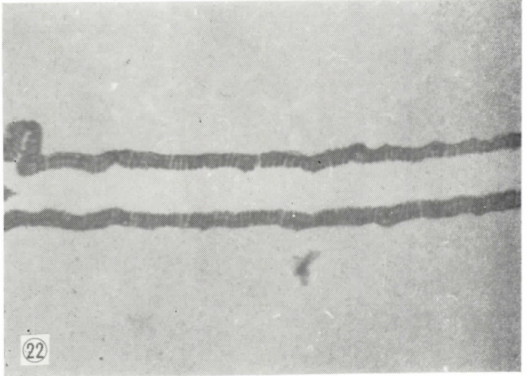
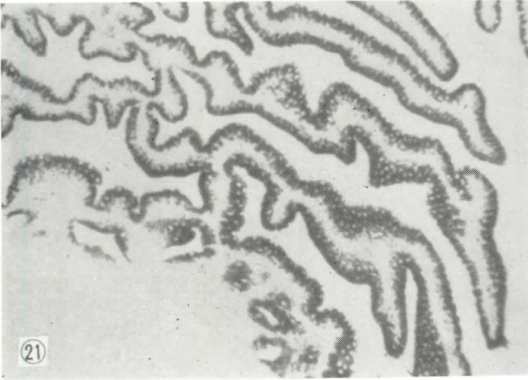
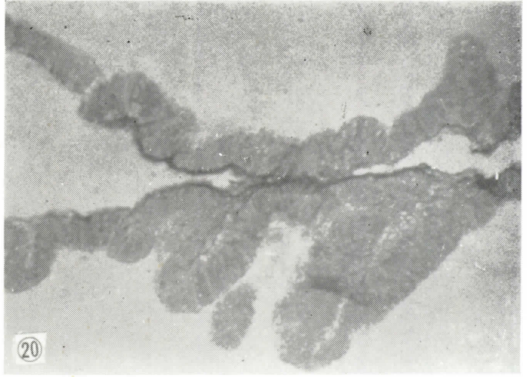
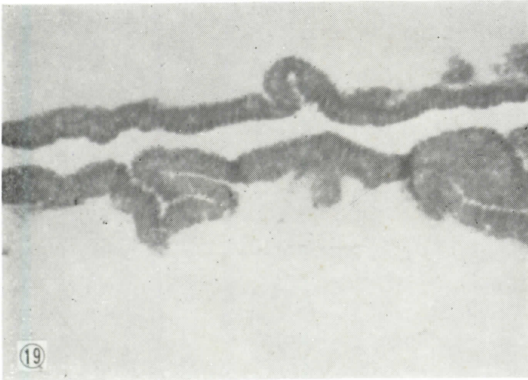- Fig. 13. The uterus. The mucous cells are slender and their mucin is AE-positive. The gland do not contain secretion granules. AE-PAS procedure.  $\times 400$ .
- Fig. 14. Anterior portion of the vagina. Only a small number of mucous cells are dispersed and they are smaller in size. The gland do not contain secretion granules. AB-PAS procedure.  $\times 400$ .
- Fig. 15. Posterior portion of the vagina. Somewhat many mucous cells are found. AB-PAS procedure.  $\times 400$ .
- Fig. 16. Posterior portion of the infundibulum. The mucin presents  $\gamma$ -metachromasia. Azure A at pH 1.0.  $\times 100$ .
- Fig. 17. The same portion in Fig. 16. The mucin in some cells presents  $\gamma$ -metachromasia (deep color in this photograph), but one in other cells is stained orthochromatically. Azure A at pH 0.5.  $\times 100$ .
- Fig. 18. Middle portion of the magnum. Metachromasia of the mucin is weak at lower pH levels. Azure A at pH 2.0.  $\times 100$ .



#### Plate 4

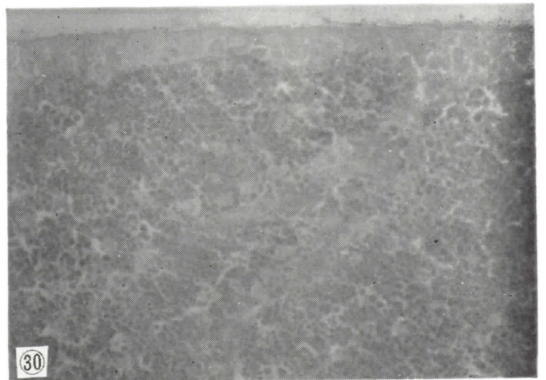
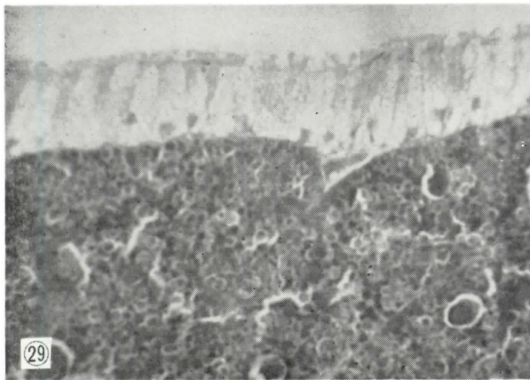
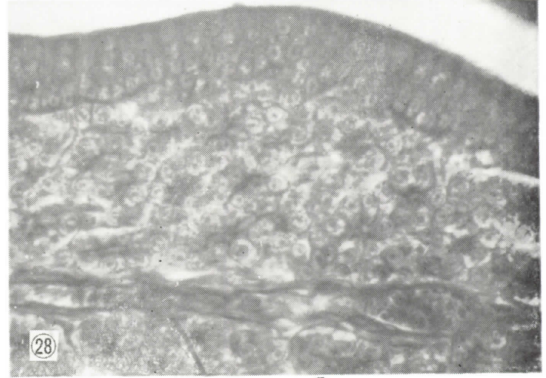
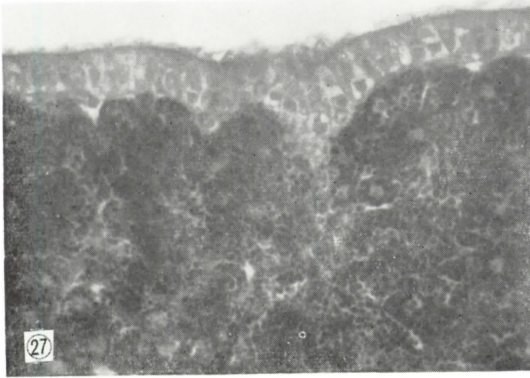
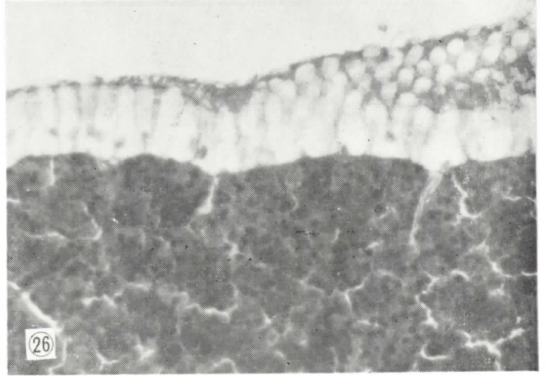
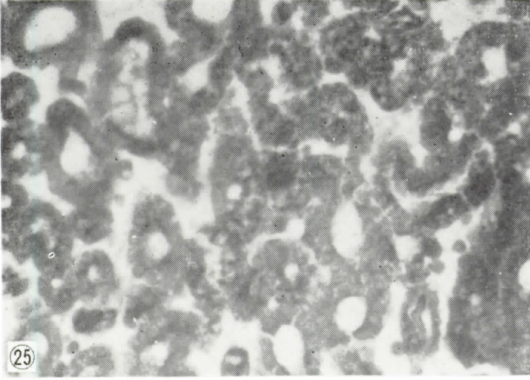
- Fig. 19. Mucous region of the magnum. Strong  $\gamma$ -metachromasia of the mucous cells is seen. Azure A at pH 2.0.  $\times 100$ .
- Fig. 20. Mucous region of the magnum. The PAS-reactivity of the mucin is blocked by phenylhydrazine. PAPS procedure.  $\times 100$ .
- Fig. 21. Middle portion of the infundibulum. The mucin is stained and presents sulfated mucopolysaccharide. AF stain.  $\times 100$ .
- Fig. 22. Middle portion of the magnum. The mucin is stained. AF stain.  $\times 100$ .
- Fig. 23. Mucous region of the magnum. The mucin is stained. AF stain.  $\times 100$ .
- Fig. 24. Epithelium of the infundibulum (middle portion). Slender ciliated cells are stained darkly, but broad mucous cells unstained. HgBPB method for protein.  $\times 400$ .





## Plate 5

- Fig. 25. Lamina propria in the middle to posterior portion of the infundibulum. In this field, two types of glands, one containing secretion granules and other no granules with dilated lumen, are found. HgBPB method.  $\times 400$ .
- Fig. 26. Posterior portion of the magnum. The mucin is not stained. Clearly stained granules fill the gland. HgBPB method.  $\times 400$ .
- Fig. 27. Anterior portion of the isthmus. The mucin is somewhat stained and the secretion granules in the gland are strongly stained. HgBPB method.  $\times 400$ .
- Fig. 28. The uterus. The mucin in the slender mucous cells is clearly stained. HgBPB method.  $\times 400$ .
- Fig. 29. Posterior portion of the magnum. The mucin is not stained, but the secretion granules of the gland are deeply stained. NS method for amino-radical.  $\times 400$ .
- Fig. 30. Anterior portion of the isthmus. The mucin is somewhat stained, and the secretion granules are clearly stained. NS method.  $\times 400$ .



## Plate 6

- Fig. 31. The uterus. The mucin is stained. NS method.  $\times 400$ .
- Fig. 32. Middle to posterior portion of the infundibulum. The mucin of mucous cells is positive, but the secretion granules in the gland negative. PFAAB procedure for cystine or cystine-compounds.  $\times 100$ .
- Fig. 33. Middle portion of the magnum. The mucin is positive, but the secretion granules of the gland are negative. PFAAB procedure.  $\times 100$ .
- Fig. 34. Anterior isthmus. The mucin is positive. Specifically, the secretion granules of the gland in this portion are reactive. PFAAB procedure.  $\times 400$ .
- Fig. 35. The uterus. The mucin is positive. PFAAB procedure.  $\times 400$ .
- Fig. 36. The gland of the anterior isthmus. The secretion granules are reactive. PFAS procedure for sulphur-containing amino-acids.  $\times 1,000$ .



