

## Histochemical Studies on the Mucin of the Chicken Salivary Glands

Shunsaku FUJII and Tatsudo TAMURA

*Department of Animal Husbandry, Faculty of Fisheries and  
Animal Husbandry, Hiroshima University*

(Table 1, Text-Figs. 1-10)

It is a well known fact in the chicken that there are many oral, or salivary, glands which open into the oral cavity. The classification or nomenclature of these glands has been somewhat inconsistent and confused by authors. CALHOUN (1954) listed the following nine sorts of glands which might be considered to constitute the salivary glands: the maxillary, palatine, sphenopterygoid, cricoarytenoid, anterior and posterior lingual, anterior and posterior submandibular, and angulus oris glands. The structure of these glands has been studied macroscopically and microscopically in detail by many workers, including HEIDRICH (1908), ZIETSCHMANN (1911), HOLTING (1912), ANTONY (1920), CHODNIK (1947, 1948), MCCALLION and AITKEN (1953), and BRADLEY and GRAHAME (1960). All the workers have completely agreed that the chicken salivary glands are all mucous ones which secrete mucin. They employed, however, only the conventional methods for the microscopic identification of mucin, and little has been known of the precise histochemical properties of mucin. The present study was performed, therefore, to clarify the nature of mucin contained in the salivary glands of the chicken by using some histochemical methods lately developed for the identification of mucopolysaccharide.

### MATERIALS AND METHODS

The salivary glands were examined in 10 adult White Leghorn hens in this study. The birds were sacrificed by decapitation. Then, the oral cavity was exposed bilaterally by cutting the mandibula at the angularis oris on one side. Small pieces of the glandular tissue, together with the surrounding tissues, were removed carefully, so that samples might be collected from the salivary glands as identified by CALHOUN's classification and terminology. They were fixed in cooled alcohol-formalin (9:1) or 10% neutral formalin. Then they were dehydrated in graded alcohol, embedded in paraffin, and sectioned at 5-7 $\mu$ . The sections from each chicken were mounted on the same slide glass and subjected simultaneously to examination. For conventional histological observation, hematoxylin and eosin, or Heidenhain's azan stain was used. For histochemical test of mucin, the following methods were employed.

(1) The periodic acid-Schiff reaction (PAS) for mucopolysaccharide (McMANUS,

1948).

(2) The metachromasia reaction was allowed to take place at room temperature for 20 minutes, with 0.02% azure A solution which had been adjusted to pH 1.5, 2.5, 3.2, and 4.1 with WALPOLE'S or SÖRENSEN'S buffer.

(3) The alcian blue method (AB) (MOWRY, 1956) and the colloidal iron method (CI) (RINEHART and ABU'L-HAJ, 1951) for acid mucopolysaccharide.

(4) The aldehyde-fuchsin method (AF) (HALMI and DAVIES, 1953), and either the aldehyde fuchsin-alcian blue method (AF-AB) or the alcian blue-aldehyde fuchsin method (AB-AF) (SPICER and MEYER, 1960).

(5) The alcian blue-PAS method (AB-PAS) (MOWRY and MORAND, 1957).

(6) Methylation for the blocking acid groups was carried out by the method of FISHER and LILLIE (1954). In this method, incubation was made in 50ml of methanol with addition of 0.5% of concentrated hydrochloric acid at 37 or 60°C.

(7) Saponification was performed in a 1% potassium hydroxide solution in 70% ethanol at 25°C for 30 minutes, according to the method of LILLIE (1958).

(8) Mild acid hydrolysis was carried out in 0.1M acetate buffer, at pH 2.5, at 37 or 60°C for 4 hours in such manner as described by QUINTARELLI et al. (1961).

(9) The ninhydrin-Schiff reaction (YASUMA and ICHIKAWA, 1951) and the mercuric bromphenol blue test (MAZIA et al., 1953) for protein.

(10) Digestion with hyaluronidase (testicular hyaluronidase produced by the Tokyo Kasei Co.) was done as described by MCMANUS and MOWRY (1960). Digestion with diastase (malt diastase produced by the Sigma Co.) was made by the procedure of LILLIE and GRECO (1947). Digestion with sialidase (influenza virus vaccine produced by the Microbiological Research Institute, Osaka University) was performed in the following manner: A few drops of sialidase solution were placed on a section kept at 37°C four times at 6 hours intervals.

## RESULTS

Histologically, the salivary glands of the chicken generally resembled one another in structure. They consisted universally of aggregates of branched tubular glands. Their excretory ducts opened into the oral cavity with many openings, except the angulus oris and maxillary glands which had only one opening. The glandular epithelium was composed of a single layer of tall columnar cells. The glandular cells varied somewhat in size and shape with the stage of secreting activity, but they were essentially different in minute structure from one salivary gland to another. The salivary glands, therefore, were divided into two large types, A and B, by the structure of their glandular cells. This division of the salivary glands agreed with the classification by HEIDRICH (1908), who discriminated two types of glands by the arrangement of excretory ducts. Type A was composed of the maxillary, anterior lingual, and angulus oris glands, and type B of the palatine, anterior and posterior submandibular, sphenopterygoid, posterior lingual, and crico-arytenoid glands. In type A, the glandular cells were low columnar in shape and contained a

somewhat round nucleus which was situated close to the proximal pole of the cell (Fig. 1). The cytoplasm appeared vesicular and somewhat dark when stained with hematoxylin and eosin. On the contrary, the glandular cells of type B were tall in height and contained a nucleus flattened at the basis of the cell (Fig. 2). In this type, the cytoplasm appeared light and extensively vesicular. The lumina of the glands were filled with a large amount of secretion.

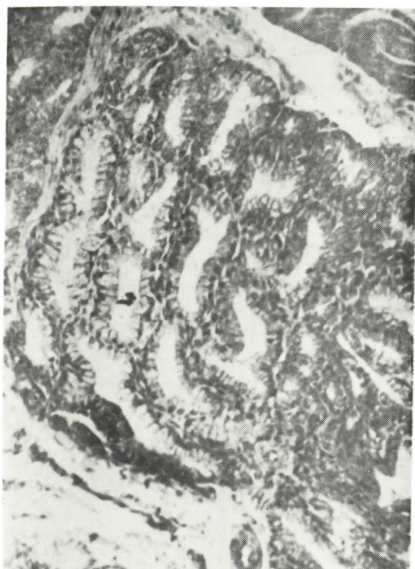


Fig. 1. Maxillary gland. The glandular cell is low columnar. The nucleus is somewhat round. In the present study, this sort of salivary gland is classified into type A. Hematoxylin and eosin stain.  $\times 100$ .

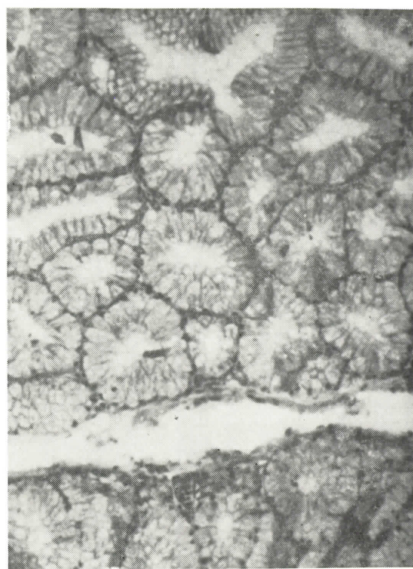


Fig. 2. Posterior lingual gland. The glandular cell is tall columnar. The nucleus is flattened at the basis of the cell. This sort of salivary gland is classified into type B. Hematoxylin and eosin stain.  $\times 100$ .

Histochemically, the contents of the secretory epithelium and the secretion mass in the lumen were identical in reaction. The results obtained from histochemical examinations of the salivary glands are summarized in Table 1. As shown in the table, all the salivary glands generally manifested similar staining reactions. In more detail, two patterns of staining were noted in the mucin of the gland in accordance with the structural types, A and B, mentioned above.

In both types, the contents of the glandular cell and the secretion in the lumen were stained diffusely dark red by the PAS method. The intensity of color, however, was more conspicuous in type B than in type A (Fig. 3). The positive PAS materials did not disappear after digestion with diastase. They were also stained metachromatically with azure A at a controlled value of pH, though the extinction value of metachromasia was different between the two types. The metachromasia in type A was faint at pH 1.5, a little intense at pH 2.5, and the most intense at a pH range from 3.2 to 4.1. On the contrary, that in type B was intense even at pH

Table 1. Staining properties of mucin in salivary glands of chicken

|  | Maxillary     | Spheno-<br>pterygoid | Crico-ary-<br>tenoid | Anterior<br>lingual | Posterior<br>lingual | Anterior<br>submandibular | Posterior<br>submandibular | Angulus<br>oris | Palatine |
|--|---------------|----------------------|----------------------|---------------------|----------------------|---------------------------|----------------------------|-----------------|----------|
| Periodic acid-Schiff                                     | ++            | +++                  | +++                  | ++                  | +++                  | +++                       | +++                        | ++              | +++      |
| Azure A metachromasia<br>at pH 1.5                       | +             | +++                  | +++                  | +                   | +++                  | +++                       | +++                        | +               | +++      |
| at pH 2.5  | ++            | +++                  | +++                  | ++                  | +++                  | +++                       | +++                        | ++              | +++      |
| at pH 3.2  | +++           | +++                  | +++                  | +++                 | +++                  | +++                       | +++                        | +++             | +++      |
| at pH 4.1  | +++           | ++                   | ++                   | +++                 | ++                   | ++                        | ++                         | +++             | ++       |
| followed by methylation<br>37°C (pH 2.5)                 | +             | ++                   | ++                   | +                   | ++                   | ++                        | ++                         | +               | ++       |
| 60°C ( // )  | -             | -                    | -                    | -                   | -                    | -                         | -                          | -               | -        |
| followed by methyl.-saponi-<br>fication (at pH 2.5)      | ++            | ++                   | ++                   | ++                  | ++                   | ++                        | ++                         | ++              | ++       |
| Alcian blue<br>control                                   | ++            | +++                  | +++                  | ++                  | +++                  | +++                       | +++                        | +++             | ++       |
| followed by methyl.<br>followed by methyl.-saponific.    | -             | -                    | -                    | -                   | -                    | -                         | -                          | -               | -        |
|  | ++            | +                    | +                    | ++                  | +                    | +                         | +                          | ++              | +        |
| Colloidal iron   | ++            | +++                  | +++                  | ++                  | +++                  | +++                       | +++                        | ++              | +++      |
| Aldehyde fuchsin   | ++            | +++                  | +++                  | ++                  | +++                  | +++                       | +++                        | ++              | +++      |
| Aldehyde fuchsin-alcian blue                             | purplish blue | purple               | purple               | purplish blue       | purple               | blue                      | purple                     | purplish blue   | purple   |
| Alcian blue-aldehyde fuchsin                             | purple        | blue                 | blue                 | purple              | blue                 | purple                    | blue                       | purple          | blue     |
| Alcian blue-PAS<br>control                               | purplish red  | purplish red         | purple               | purple              | purple               | purple                    | purple                     | purple          | purple   |
| followed by methyl.                                      | red           | purplish red         | red                  | purple              | red                  | purple                    | red                        | purple          | purple   |
| Mild acid hydrolysis (60°C)<br>metachromasia (at pH 2.5) | +             | ++                   | ++                   | +                   | +                    | +                         | ++                         | +               | +        |
| alcian blue  | +             | +++                  | ++                   | +                   | +++                  | +                         | +++                        | +               | ++       |
| Diastase digestion                                       |               |                      |                      | no effect           |                      |                           |                            |                 |          |
| Sialidase digestion                                      |               |                      |                      | no effect           |                      |                           |                            |                 |          |
| Hyaluronidase digestion                                  |               |                      |                      | no effect           |                      |                           |                            |                 |          |
| Ninhydrin-Schiff   |               |                      |                      | + ~ ±               |                      |                           |                            |                 |          |
| Mercuric bromphenol blue                                 |               |                      |                      | + ~ ±               |                      |                           |                            |                 |          |

+ = positive reaction. The number of plus signs is proportional to the intensity of the reaction. ± = doubtful or exceedingly weak reaction.

- = negative reaction.

1.5 or lower, the most intense at a pH range from 1.5 to 3.2, and less intense at pH 4.1. The positive PAS materials were also stained by method AB (Figs. 6 and 9) or CI (Fig. 4). The stained color was more striking in type B than in type A. When stained by method AF, those materials were bright purple in type B (Fig. 5) and feeble purple in type A. After double staining by method AF-AB or its reciprocal method AB-AF, they were purplish blue by AF-AB and purple by AB-AF in type A, whereas they were purple and blue, respectively, in type B. This indicates that

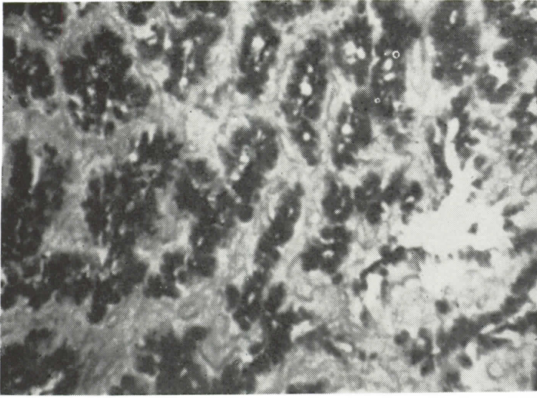


Fig. 3. Maxillary gland. The cytoplasm of the glandular cell is strongly positive for staining. Periodic acid-Schiff staining.  $\times 100$ .

Fig. 4. Maxillary gland. The cytoplasm is deeply stained. Colloidal iron staining.  $\times 100$ .

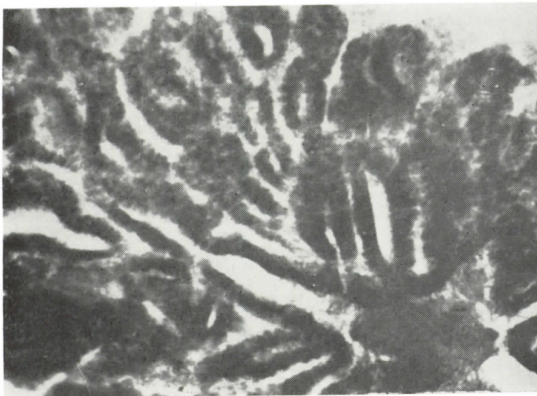
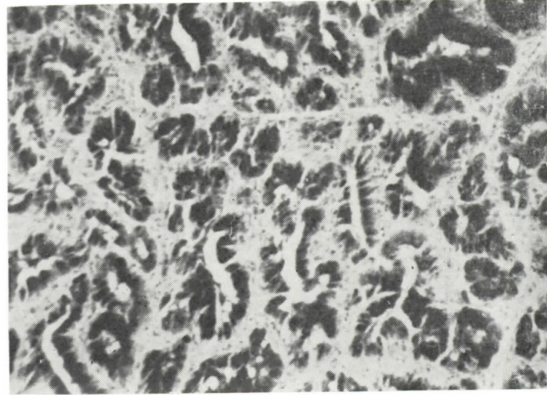


Fig. 5. Crico-arytenoid gland. The cytoplasm of the glandular cell is deeply stained. Aldehyde fuchsin method.  $\times 100$ .

the mucin of type A always took the second dye and that of type B the first dye, regardless of the sequence of staining with the two dyes. By method AB-PAS, the positive PAS materials were stained in varying colors from purple to purplish red, and no clear difference was observed in staining between the two types of glands.

The alcianophilia and azurophilic metachromasia of the mucin partly diminished by methylation at 37°C for 4 hours and entirely disappeared by methylation at 60°C for 4 hours (Fig. 7). When saponification was carried out after methylation, such properties as alcianophilia and metachromasia of the mucin were restored relatively well in type A, but only poorly in type B (Fig. 8). Accordingly, after methylation the coloration by method AB-PAS was changed from purple to red owing to the elimination of alcianophilia, and the PAS reactivity diminished slightly. Mild acid hydrolysis at 60°C for 4 hours reduced the alcianophilia and metachromasia of the glands of type A, and the anterior submandibular glands characteristically, while it did those of the glands of type A only slightly. The ninhydrin-Schiff reaction and mercuric bromphenol blue test for protein were faintly positive or perfectly negative. Neither hyaluronidase nor sialidase affected the alcianophilia and metachromasia of the mucin.

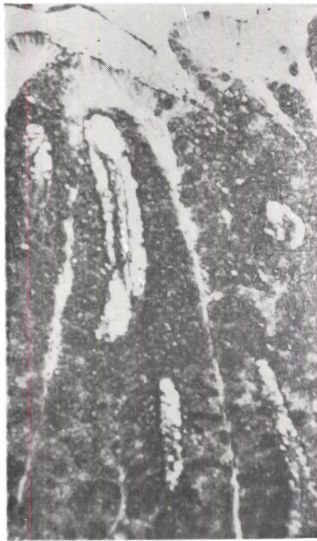

Fig. 6



Fig. 7

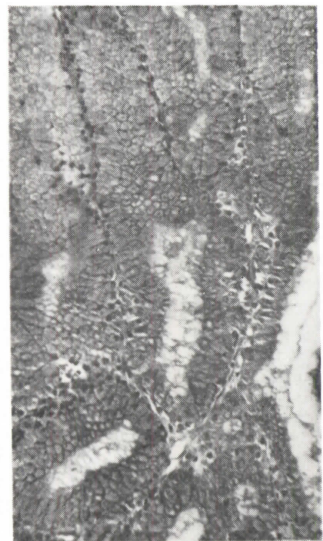


Fig. 8

- Fig. 6. Anterior submandibular gland. The cytoplasm of the glandular cell is deeply stained. Control. Alcian blue method.  $\times 100$ .
- Fig. 7. Anterior submandibular gland. Alcianophilia disappeared completely from the cytoplasm. Compare with Fig. 6. Alcian blue method.  $\times 100$ .
- Fig. 8. Anterior submandibular gland. Note restoration of alcianophilia blocked by methylation. Compare with Figs. 6 and 7. Alcian blue method after saponification.  $\times 100$ .

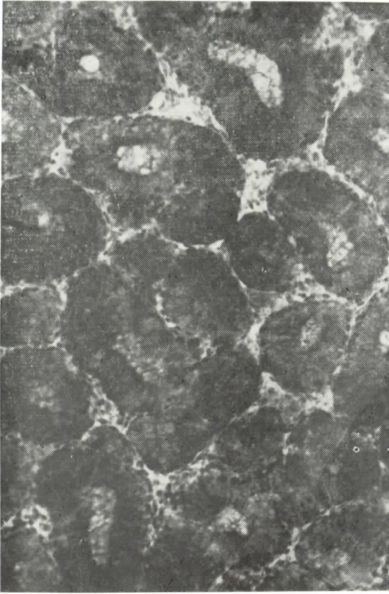

Fig. 9. Anterior submandibular gland. Control, Alcian blue method.  $\times 150$ .

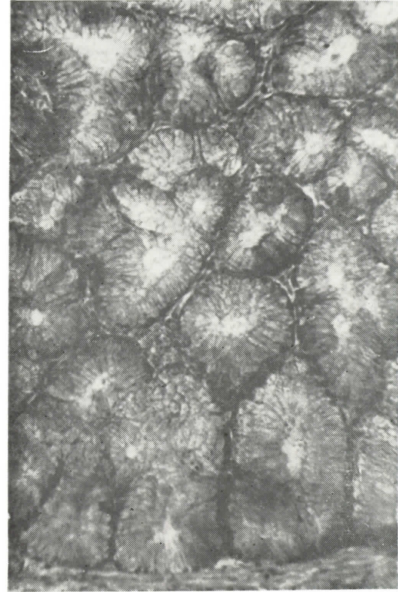


Fig. 10. Anterior submandibular gland. Alcianophilia disappeared almost completely from the cytoplasm. Compare with Fig. 9. Alcian blue method after mild acid hydrolysis.  $\times 150$ .

## DISCUSSION

According to the many workers cited above, the salivary glands of the chicken are all mucin-secreting ones, being different from those of the mammal which are composed of mucous and serous glands. Differentiation of a mucous salivary gland was made by such stain as thionin, Bismarck brown, and mucihematein. In the present study, the contents of the glandular cell were strongly PAS-reactive, azure A-metachromatic, and strongly alcianophilic, and showed affinity to various acid mucin stains. Furthermore, they were almost or entirely negative for such protein tests as the ninhydrin-Schiff reaction and the mercuric bromphenol blue test. Diastase digestion did not alter the PAS reactivity. The use of hyaluronidase and sialidase modified none of the properties, including alcianophilia, metachromasia, and PAS reaction. These results indicate that the glandular cell is devoid of glycogen, basic protein which shows metachromasia, and hyaluronic and sialic acid, both of which belong to acid mucin. The occurrence of these histochemical reactions is attributed to the properties of acid mucopolysaccharide. It is clear, therefore, that the salivary glands of the chicken are all mucous ones, and that the mucin secreted is acid mucin which has no connection with sialic or hyaluronic acid.

According to FISHER and LILLIE (1954), and SPICER and LILLIE (1959), acid

mucin is characterized by the presence of such acid radicals as sulphyl, carboxyl, and phospholyl in the polymer. The alcianophilia and metachromasia of acid mucin are induced by the presence of these acid radicals. Therefore, a question arises which acid radical is related to the formation of acid mucin in the salivary glands. As already stated, there were small differences in the histochemical reactions of acid mucin between the two types of salivary glands. The mucin of the type A gland manifested metachromasia when stained with azure A at a pH range from 3.2 to 4.1. It was stained feeble purple by method AF and took the second dye used in double staining by method AF-AB or AB-AF. On the other hand, the mucin of type B gland manifested metachromasia when stained with azure A at a pH range from 1.5 to 3.2. It was stained bright purple by method AF and took the first dye used in double staining by method AF-AB or AB-AF. These histochemical differences of acid mucin between the two types of salivary glands may probably be derived from the difference in acid radicals contained in the mucin or in constituents of the mucin.

Previously, ABU'L-HAJ and RINEHART (1952) stated that a bright purple stain by method AF and metachromasia by staining at pH 1.5 indicated the presence of sulfated mucopolysaccharide. SPICER (1961), who established standards for histochemical differentiation of mucin, pointed out that sulfated mucopolysaccharide revealed a clear metachromasia at pH 1.5 or lower and was stained much more strongly by method AF than nonsulfated mucopolysaccharide. He also found that sulfated mucin was always stained with the first dye used either in method AF-AB or in method AB-AF, and nonsulfated mucin with the second dye used in either method. From these findings, in addition to the results obtained from the present study, it may well be that the mucin substrates of the salivary glands are compounds of nonsulfated and sulfated mucopolysaccharide, and that the mucin of the type A salivary glands (the maxillary, anterior lingual, and angulus oris glands) is mainly composed of nonsulfated mucin, and that of the type B ones (the palatine, anterior and posterior submandibular, spheno-pterygoid, posterior lingual, and crico-arytenoid glands) of sulfated mucin.

This presumption was supported by the results of the methylation and the subsequent saponification of the mucin. FISHER and LILLIE (1954) reported that the methylation eliminated metachromasia and alcianophilia of acid mucin, because it esterized the carboxyl or phospholyl group and hydrolyzed the sulphyl group. In the former case, saponification following methylation restored the original structure and, accordingly, the properties of acid reactions. In the latter case, saponification no longer restored the original structure and, accordingly, the properties of acid reactions. In fact, in the present study, metachromasia and alcianophilia disappeared completely from the mucin by methylation in all the salivary glands. With saponification following methylation, they were restored almost completely in the mucin of the type A gland, but only partly in that of the type B gland. Particularly, the incomplete restoration of acid reactions after saponification in the mucin of the type B gland seemed to lend support to the alleged presence of sulfated mucin in this



gland.

It is worthy of noting that mild acid hydrolysis markedly reduced the alcianophilia and metachromasia of the mucin in the anterior submandibular glands. QUINTARELLI et al. (1961), who were the first to apply this method to the identification of sialomucin, reported that the sialic acid was destroyed by means of mild acid hydrolysis and hydrolyzed with sialidase, causing the entire disappearance of acid reactions. From their report, the nature of the mucin of the anterior submandibular glands is likely to suggest the presence of sialic acid. In the present study, however, treatment with sialidase failed to induce any change in the acid reactions of the mucin. Judging from these results and the occurrence of a strong metachromasia at a low value of pH, only a small amount, if any, of sialic acid seems to be contained in the anterior submandibular glands. At any rate, further investigation will be necessary to clarify the character of the mucin contained in the anterior submandibular glands.

Concerning the structure of the salivary gland, many workers are not always of the same opinion. HEIDRICH (1908) divided the salivary glands into three types by structure, classifying most of them into two types. HOLTING (1912), CALHOUN (1954), and some other workers asserted that all the glands developed into the same structure. In the present investigation, two types of glands were distinguished histologically by the minute structure of the constituent glandular cells. The two types of glands were differentiated clearly by the histochemical properties of the acid mucin contained. Therefore, it is preferable to divide the salivary glands into two types, as did Heidrich.

## SUMMARY

The mucin of the salivary glands of the chicken was examined histochemically. The results obtained are as follows.

(1) In all the salivary glands, the contents of the glandular cell and the secretion in the glandular lumen were strongly periodic acid-Schiff reactive, azure A-metachromatic at a low value of pH, and alcianophilic, and showed affinity to various acid mucin stains. Methylation completely deprived the glandular cell of such properties as alcianophilia and metachromasia. Saponification after methylation almost completely restored those properties blocked by methylation. Digestion with such an enzyme as diastase, hyaluronidase, or sialidase failed to modify the staining properties of the glandular cell. The cell was almost negative for ninhydrin-Schiff and mercuric bromphenol blue reactions for protein. From the results of these histochemical reactions, it was concluded that the salivary glands of the chicken were all mucin-secreting ones, and that the mucosubstance contained in the glands was acid mucopolysaccharide in nature.

(2) The acid mucin of the salivary glands was considered as compounds of nonsulfated and sulfated acid mucopolysaccharide. It was different in composition from one gland to another. The salivary glands were divided into two groups on

the basis of this difference. The maxillary, anterior lingual, and angulus oris glands were composed mainly of nonsulfated acid mucopolysaccharide and classified into one group. The palatine, anterior and posterior submandibular, spheno-pterygoid, posterior lingual, and crico-arytenoid glands consisted mainly of sulfated acid mucopolysaccharide and formed the other group.

#### REFERENCES

- ABU'L-HAJ, S.K., and J.F. RINEHART: Fuchsin-aldehyde staining of sulfated mucopolysaccharides and related substances. *J. Nat. Cancer Inst.*, **13**, 232-233 (1952).
- ANTONY, M.: Über die Speicheldrüsen der Vögel. *Zool. Jahrb. Abt. Anat. u. Ontog. Tiere*, **41**, 547-660 (1920).
- BRADLEY, O.C., and T. GRAHAME: *The Structure of the Fowl*. Oliver and Boyd Co., Edinburgh, 1960.
- CALHOUN, M.L.: *Microscopic Anatomy of the Digestive System of the Chicken*. The Iowa State University Press, Ames, Iowa, 1954.
- CHODNIK, K.S.: A cytological study of the alimentary tract of the domestic fowl (*Gallus domesticus*). *Quart. J. Micros. Sci.*, **88**, 419-443 (1947).
- : Cytology of the glands associated with the alimentary tract of domestic fowl (*Gallus domesticus*). *Ibid.*, **89**, 75-87 (1948).
- FISHER, E.R., and R.D. LILLIE: The effect of methylation on basophilia. *J. Histochem. Cytochem.*, **2**, 81-87 (1954).
- HALMI, N.S., and J. DAVIES: Comparison of aldehyde fuchsin staining, metachromasia and periodic acid-Schiff reactivity of various tissues. *J. Histochem. Cytochem.*, **1**, 447-459 (1953).
- HEIDRICH, K.: Die Mund-Schlundkopfhöhle der Vögel und ihre Drüsen. *Morph. Jahrb.* **37**, 10-69 (1908).
- HOLTING, H.: Über den mikroskopischen Bau der Speicheldrüsen einiger Vögel. *Diss. Giessen*, 1912 (cited from Calhoun, M.L.: *Microscopic Anatomy of the Digestive System of the Chicken*).
- LILLIE, R.D.: *Histopathologic technique and practical histochemistry*. McGraw-Hill Co., New York, 1958.
- LILLIE, R.D., and J. GRECO: Malt diastase and ptyalin in places of saliva in the identification of glycogen. *Stain Technol.*, **22**, 67-70 (1947).
- MCCALLIN, D.J., and H.E. AITKEN: A cytological study of the anterior submaxillary glands of the fowl, *Gallus domesticus*. *Canad. J. Zool.*, **31**, 173-178 (1953).
- MCMANUS, J.F.A.: Histological and histochemical uses of periodic acid. *Stain Technol.*, **23**, 99-108 (1948).
- MCMANUS, J.F.A. and R.W. MOWRY: *Staining methods, Histologic and Histochemical*. Paul B. Hoeber, Inc., 1960.
- MAZIA, D., P.A. BREWER, and M. ALFERT: The cytochemical study and measurement of protein with mercuric bromphenol blue. *Biol. Bull.*, **104**, 57-67 (1953).
- MOWRY, R.W.: Alcian blue techniques for histochemical study of acidic carbohydrates. *J. Histochem. Cytochem.*, **4**, 407 (1956).
- MOWRY, R.W., and J.C. MORAND: Distribution of acid mucopolysaccharides in normal kidney, as shown by the alcian blue-Feulgen (AB-F) and alcian blue periodic acid-Schiff (AB-PAS) stain. *Amer. J. Pathol.*, **33**, 620-621 (1957).
- QUINTARELLI, G.S., S. TSUIKI, Y. HASHIMOTO, and W. PIGMANN: Studies of sialic acid-containing mucins in bovine submaxillary and rat sublingual glands. *J. Histochem. Cytochem.*, **9**, 176-183 (1961).
- RINEHART, J.F., and S.K. ABU'L-HAJ: An improved method for histologic demonstration of acid mucopolysaccharides in tissues. *Arch. Path.*, **52**, 189-194 (1951).

- SPICER, S.S., and R.D. LILLIE: Saponification as a means of selectively reversing the methylation blockade of tissue basophilia. *J. Histochem. Cytochem.*, **7**, 123-125 (1959).
- SPICER, S.S., and D.B. MEYER: Histochemical differentiation of acid mucopolysaccharides by means of combined aldehyde fuchsin-alcian blue staining. *Amer. J. Clin. Path.*, **33**, 453-460 (1960).
- SPICER, S.S.: Histochemical differentiation on mammalian mucopolysaccharides. *Ann. N.Y. Acad. Sci.*, **106**, 379-388 (1961).
- ZIETSCHMANN, O.: Der Verdauungsapparat der Vögel. *In ELLENBERGER'S Handbuch der vergleichenden mikroskopischen Anatomie der Haustiere*. Paul Parey, Berlin, 1911.
- YASUMA, A., and T. ICHIKAWA: A new cytochemical staining of protein. *Medicine and Biology*, **19**, 197-200 (1951). (in Japanese)

### 鶏の唾液腺ムチンの組織化学

藤井俊策・田村達堂

鶏の口腔に開口するいわゆる唾液腺はいずれも粘液性腺であるといわれている。しかしこの唾液腺粘液物質の性状についての報告は少ない。そこで鶏の唾液腺ムチンを組織化学的に観察した。

調べた9種の唾液腺はすべて粘液性腺であり、粘液物質は酸性粘液多糖類の性状を示した。しかし腺により多少酸性粘液の性状が異なっていた。詳しくは、単口上顎腺、前舌腺、口角腺のムチンは主として非硫酸性粘液多糖類の性質を示し、口蓋腺、前および後顎下腺、蝶形翼状腺、後舌腺、輪状披裂腺のそれは主として硫酸性粘液多糖類の性質を示した。