

Histochemical Study of Mucopolysaccharides in Goblet Cells of the Chicken Oviduct

Shunsaku FUJII, Tatsudo TAMURA and Hakaru KUNISAKI

*Department of Animal Husbandry, Faculty of Fisheries and
Animal Husbandry, Hiroshima University*

(Table 1, Text-fig. 1-6)

The inner surface of the chicken oviduct, as is well known, is thoroughly covered with a single layer of epithelial cells composed of two types, ciliated and nonciliated columnar cells. The nonciliated cells vary widely in appearance and distribution in the epithelium of each segment of the oviduct, but they are generally characteristic goblet cells which secrete mucin. The goblet cells seem to play a particular role in egg formation. They were studied histologically by many workers, including SURFACE (1912), GIERSBERG (1923), BRADLEY (1928), RICHARDSON (1935), AITKEN et al (1963), and JOHNSTON et al (1963), all of whom described the structure of the oviduct. On the other hand, they were examined histochemically by a few authors, including BRADLEY (1928), RICHARDSON (1935), and CHAKRAVORTI (1961). They were described, however, only briefly and there was no mentioning about the histochemical property of mucin. The mucin contained in the goblet cells seems to be different in histochemical properties from one portion of the oviduct to another. The present investigation was made, therefore, to clarify histochemically the mucin components of the goblet cells in the mucosa of the chicken oviduct.

MATERIALS AND METHODS

Adult White Leghorn hens in various stages of laying were used. They were sacrificed by bleeding from the jugular vein, and the whole oviducts were removed promptly from them. Small pieces of tissues were collected from five parts of the oviduct; that is, infundibulum, magnum, isthmus, uterus, and vagina. They were fixed in Bouin's, Zenker's, Carnoy's solution, or 10% formalin and made routinely to paraffin sections 5 μ thick. The sections from each part of the oviduct were mounted on a slide glass and subjected simultaneously to every examination. For usual histological observation, hematoxylin and eosin, or Heidenhain's iron hematoxylin was used. For histochemical reaction of mucin, the following methods were employed.

- (1) The periodic acid-Schiff (PAS) reaction for mucopolysaccharide (McMANUS, 1948).
- (2) Toluidine blue was used for detection of acid mucopolysaccharide in the form of 0.05% solution buffered at pH 1.5, 2.5, 4.1, and 7.0 at room temperature for 20 minutes.

- (3) The alcian blue method (AB) (MOWRY, 1956) and the colloidal iron method (CI) (RINEHART and ABUL-HAJ, 1951) for acid mucopolysaccharide.
- (4) The aldehyde-fuchsin method (AF) (HALMI, 1953) and the aldehyde fuchsin-alcian blue method (AF-AB) or the alcian blue-aldehyde fuchsin method (AB-AF) (SPICER and MEYER, 1960).
- (5) The alcian blue-PAS method (AB-PAS) (MOWRY, 1956).
- (6) The periodic acid-phenylhydrazine-Schiff method was used by a 5-hour blockade in 5% phenylhydrazine hydrochloride interposed between periodic acid oxidation and Schiff reagent (LILLIE, 1954).
- (7) Methylation for the blocking acid groups was accomplished, by incubation at 37° or 60°C, in a mixture of 50 ml of methanol and 0.4 ml of concentrated hydrochloric acid (FISHER and LILLIE, 1954).
- (8) Saponification was performed in 100 ml of 80% ethanol containing 1g of potassium hydrochloride at 25°C for 30 minutes (LILLIE, 1958).
- (9) Sulfation was performed according to the method of LEWIS and GRILLO (1959).
- (10) Testicular hyaluronidase (product of the Tokyo Kasei Company) was used for the removal of hyaluronic acid by incubation at 37°C for 5-12 hours, in the form of 1mg per 2 ml solution adjusted to pH 6.5 with phosphate-citrate buffer.
- (11) Sialidase was used for the removal of sialic acid in the form of a commercial influenza virus vaccine. A few drops of the enzyme solution buffered at pH 5.5 were placed on section at 37°C every 6 hours up to 24 hours.
- (12) Saliva digestion was used for the removal of glycogen according to the method of ACARDI (1952).

RESULTS

The results of histochemical investigation on the mucin of the goblet cells are summarized in Table 1.

Infundibulum

The mucosa of the infundibulum had folds with low longitudinal ridges in the anterior region. The folds increased gradually in height and thickness toward the posterior region. The lining epithelium was formed only by ciliated cuboidal cells in the anterior region, but by both ciliated columnar and goblet cells in the posterior region. The goblet cells were distributed sparsely among the ciliated cells and filled with minute secretion granules at their tips (Fig. 1). They were stained strong red by the PAS method. The positive PAS reaction withstood to saliva digestion. With toluidine blue, they were so stained as to present β -metachromasia at a range of pH from 1.5 to 4.1 and orthochromasia at pH 7.0. The mucin was stained clear reddish purple with the AF stain, while it was not stained so strongly by the AB and CI method. They were stained purple by the combined AB-PAS method and always faint purple by the AB-AF as well as AF-AB method. No changes in staining reaction were observed when sections were

Table 1. Histochemical reactions of mucins of goblet cells of chicken oviduct

		Infundibulum	Magnum	Isthmus	Uterus	Vagina
Periodic acid -Schiff reaction	Control	++	+++	+++	+	++
	followed by methylation	+	++	++	±	+
	followed by methyl.- saponific.	+	++	++	±	+
	Phenylhydrazine -Schiff reaction	++	+++	-	-	++
Toluidine blue (metachromasia)	Control					
	at pH 1.5	+++	+++	-	-	+++*
	at pH 2.5	+++	+++	-	-	+++*
	at pH 4.1	+++	+++	-	-	++
	at pH 7.0	+	++	-	-	-
	followed by methylation(at pH 2.5) followed by methyl.- saponific. (at pH 2.5) followed by sulfation (at pH 2.5)	-	+	-	-	-
	+	++	-	-	+	
	+++	+++	++	++	+++	
Alcian blue	Control	±~+	+++	±	-	++
	followed by methylation followed by methyl.- saponific.	-	+	-	-	-
		±	++	-	-	+
	Colloidal iron	±~+	+++	±~+	-	-
	Aldehyde fuchsin	+++	+++	+	-	-
	Alcian blue-periodic acid-Schiff	purple	blue	red	-	purplish blue
	followed by methylation	purple	red	red	-	purplish red
	followed by methyl.- saponific.	purple	bluish red	red	-	purplish red
	Aldehyde fuchsin -alcian blue	purple	purple	-	-	blue
	Alcian blue -aldehyde fuchsin	purple	blue	-	-	blue
	Saliva digestion			not effective		
	Sialidase digestion			not effective		
	Hyaluronidase			not effective		

+ = positive reaction; the number of plus signs is proportional to the intensity of the reaction; ± = doubtful or exceedingly weak reaction; - = negative reaction; * = false metachromasia

incubated with hyaluronidase and sialidase. Methylation at 37°C for 4 hours completely deprived mucin of toluidine-blue metachromasia and alcian-blue affinity, so that the color of mucin stained by the AB-PAS method changed from purple to red. However, when the mucin was subjected to saponification after methylation, it restored both metachromasia and alcianophilia relatively well.

Magnum

In the magnum, the longitudinal folds of the mucosa were better developed than

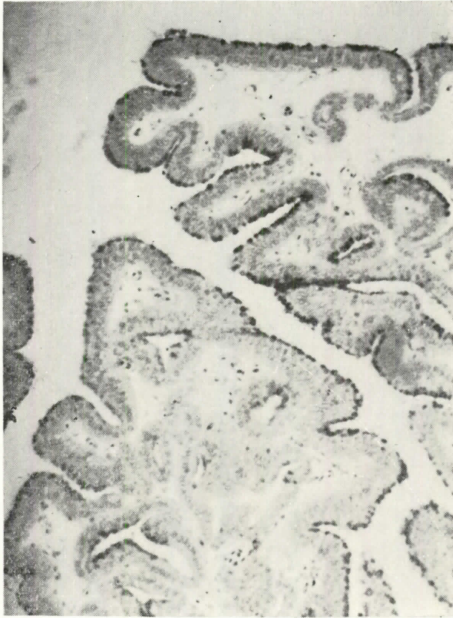


Fig. 1. The goblet cells of the infundibular epithelium of the chicken oviduct. The cells are located sparsely among the ciliated cells and contained secretion granules at their tips. PAS staining. X150.

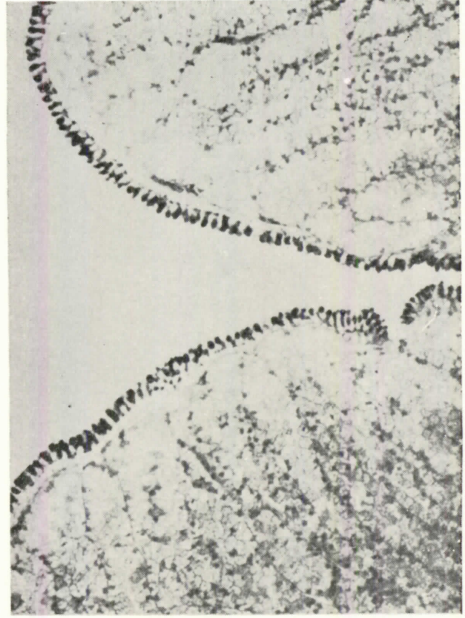

Fig. 2. The goblet cells of the magnum portion. The cells are located regularly among the ciliated cells. Their cytoplasm are strongly positive with PAS. PAS staining. X150.

in the infundibulum. They were quite high and broad. The epithelium was lined with altered ciliated and goblet cells (Fig. 2). Each goblet cell showed a typical goblet-form and contained secretion granules in its cytoplasm. In the caudal portion about 4 cm broad of the magnum, which was named the "*mucous zone*" by RICHARDSON (1935), the goblet cells were exceedingly tall and so predominant in distribution that they were hardly distinguished from the ciliated cells (Fig. 3).

The goblet cells in this zone showed essentially the same histochemical reaction as those in the infundibulum, except in some respects. The mucin of those cells manifested a strong metachromasia with toluidine blue at every pH value examined, but a particularly conspicuous one at a pH value below 4.1. The PAS-reactivity, alcianophilia, and affinity to colloidal iron or aldehyde fuchsin were much more pronounced in the magnum than in the infundibulum. In the AB-PAS procedure, the goblet cells were generally stained blue, while those at the bottom of the folds were stained purple or red. They always took the first dye in the AF-AB sequence as well as in the AB-AF procedure. After methylation, the toluidine-blue metachromasia and alcianophilia remained faintly even when incubation was made at 55°C for 4 hours. The above-mentioned histochemical

reactions increased gradually in intensity toward the posterior region and reached their maximum in the "mucous zone" which is the end of the magnum.

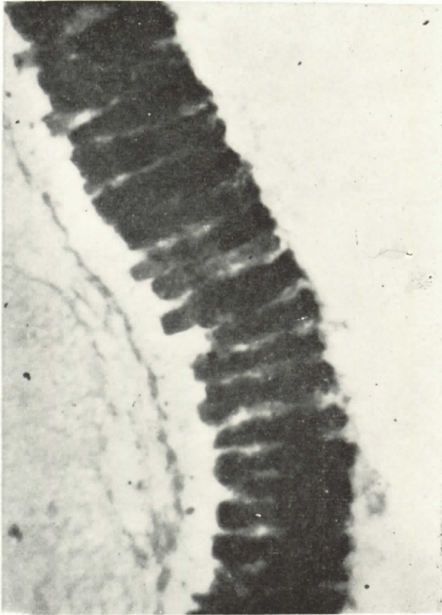


Fig. 3. The goblet cells of the *mucous zone*. The cells are broad in width and tall in height, and they are more prevalent than those of the magnum. Colloidal iron staining. X600.

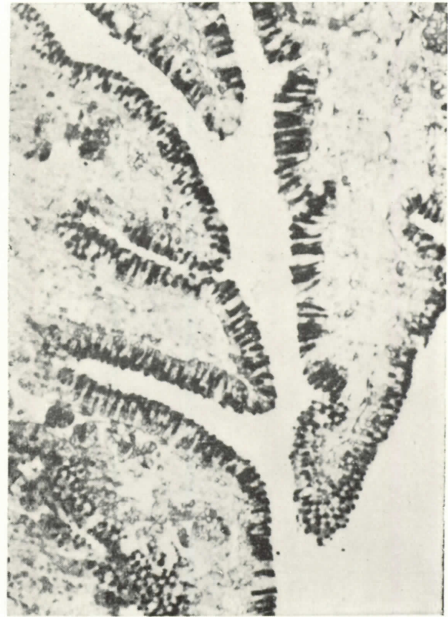

Fig. 4. The goblet cells of the *isthmus* portion. The cells are somewhat slender. PAS staining. X200.

Isthmus

In the isthmus, the mucosa had folds with longitudinal ridges as in the preceding region, but the folds were not so broad or so high as those in the magnum. The epithelium, like that of the magnum, was composed of ciliated and goblet cells. The goblet cells of the isthmus were less developed than those of the magnum (Fig. 4). They abruptly showed noticeable histochemical reactions. They were intensively PAS-reactive. They were not metachromatic with toluidine blue, but sometimes weakly metachromatic at pH 4.1. Sulfation imparted a clear metachromasia to the mucin. The goblet cells were stained blue with AB-PAS, but not with AB and CI, which are used to stain acid mucin. It is noted, however, that the PAS reactivity was completely eliminated when phenylhydrazine had been introduced between the periodic-acid oxidation and the Schiff reaction.

Uterus

In the uterus, the mucosa was thrown into leaf-like folds different from those in the rest of the oviduct. It was lined with a pseudostratified epithelium composed of

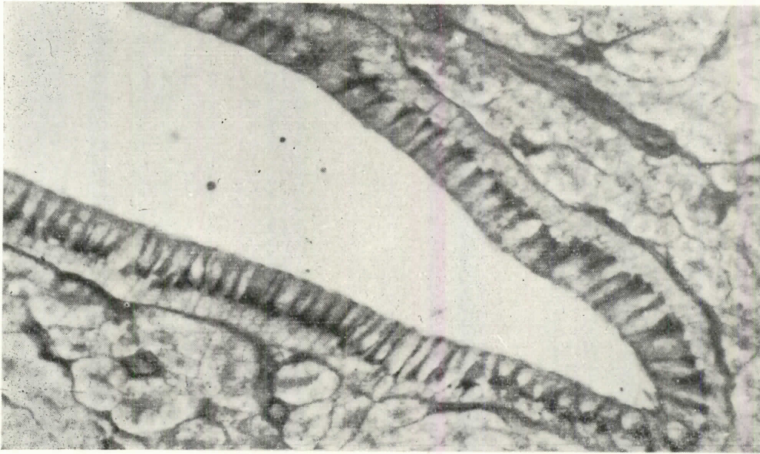


Fig. 5. The goblet cells of the uterus portion. The cells are markedly slender. Their cytoplasm are stained relatively well with PAS. PAS staining. X400.

ciliated columnar and goblet cells. The goblet cells were markedly slender, compressed among the ciliated cells. They showed histochemical reactions similar to those of the goblet cells of the isthmus. They were, however, somewhat weak in the PAS reactivity (Fig. 5), which was diastase-resistant and which was blocked completely by the use of phenylhydrazine, like that of the goblet cells of the isthmus. They were not metachromatic at all, but revealed a clear metachromasia by sulfation. All the other methods employed failed to stain the mucin. Exceptionally, the cells of the narrow anterior region of the uterine pouch were stained with the AB as well as CI method and showed a metachromatic reaction with toluidine blue.

Vagina

In the vagina, the mucosa was thrown into tall longitudinal folds with many secondary ridges, which were arranged parallel to the folds in transverse direction. The epithelium was composed of ciliated and goblet cells. The goblet cells were predominant at the bottom of the grooves (Fig. 6). They were stained intensively by the PAS and AB procedure, but not stained by the AF method. They showed a curious reaction to toluidine blue stain. The mucin reacted strongly to toluidine blue at pH 1.5 and 2.5, and weakly at pH 4.1 in wet preparation, but the metachromasia disappeared quickly when the sections had been dehydrated with alcohol. Metachromasia after sulfation was present

consistently even when dehydration was carried out for a long time. The mucin was stained purplish blue with double stain of AB-PAS and always blue by the AF-AB or the AB-AF procedure. Alcianophilia and metachromasia disappeared completely from the mucin after methylation, but they were recovered by saponification.

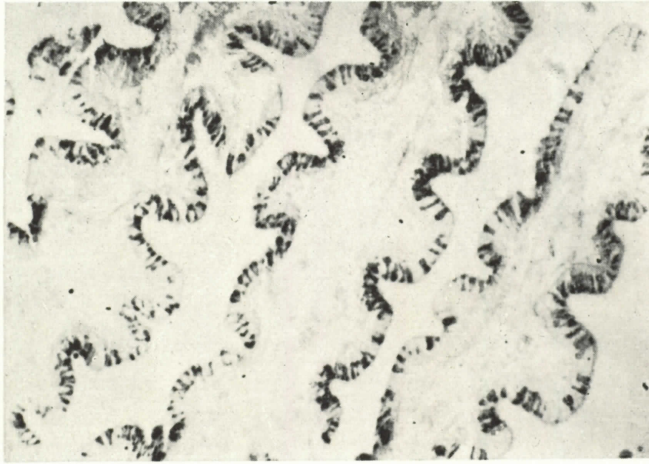


Fig. 6. The goblet cells of the uterus portion. They are crowded at the bottom of the secondary ridges. PAS staining. X150.

DISCUSSION

In his early histochemical study on goblet cells contained in the mucosa of the oviduct of the fowl, BRADLEY (1928) observed that the goblet cells were stained strongly in the infundibulum and magnum, somewhat weakly in the vagina, poorly in the isthmus, and not at all in the uterus when they were subjected to such mucin stains as neutral red, thionin blue, and Bismarck brown. RICHARDSON (1935) obtained the same results as Bradley. CHAKRAVORTI (1961) found that the goblet cells of the uterus and vagina were stained extensively positive with PAS, Hale's colloidal iron, and alcian blue, and stated that they possibly contained an acid mucopolysaccharide.

The present study indicates that the mucins of goblet cells were markedly different in histochemical properties according to the portion of the oviduct. In general, the PAS reaction was positive in all goblet cells throughout the oviduct, though it was weakly positive in those of the uterus. The PAS reactivity was preserved against saliva digestion. The use of hyaluronidase and sialidase changed none of such properties of mucin as PAS reaction and affinity to alcian blue and toluidine blue, so that no glycogen, hyaluronic acid, nor sialic acid occurred in the mucin.

Concerning the goblet cells of the infundibulum, the previous authors (BRADLEY, and RICHARDSON) stated briefly that they were stained readily with usual mucin stains.

In the present study, they were strongly PAS-reactive, toluidine-blue metachromatic, weakly alcianophilic, and aldehyde-fuchsin reactive. It is well known that these histochemical reactions are attributed to the properties of acid mucopolysaccharides. A question, however, arises whether the acidity of the mucin is due to the presence of a sulphyl, carboxyl, or phospholyl radical. FISHER and LILLIE (1954), and SPICER and LILLIE (1959) reported that the metachromasia and alcianophilia of mucopolysaccharides were owing to the presence of the above-mentioned acid radicals in the polymers. The same authors pointed out that the methylation of acid mucopolysaccharides eliminated such staining reactions as based on acid radicals, because it esterified the carboxyl or phospholyl group and hydrolyzed the sulphyl group. In the former case, saponification following methylation restored the original structure and, therefore, the properties of acid reactions. In the latter case, however, saponification no longer restored the original structure and, therefore, the properties of acid reactions. In fact, in the present study, the metachromasia and alcianophilia of mucin were completely abolished by methylation, but restored partially by saponification after methylation. This shows that the acid mucins of the goblet cells may contain nonsulfated acid mucopolysaccharides.

On the other hand, the goblet cells were stained reddish-purple intensively with AF alone and purple with AF-AB, as well as AB-AF. This finding, together with the weak alcianophilia and strong metachromasia of mucin at a low pH, is also likely to suggest the presence of sulfated mucopolysaccharides in the mucins, for ABUL-HAJ (1952) pointed out that a clear purple stain with AF and metachromasia at pH 1.5 indicated the occurrence of sulfated mucopolysaccharides. SPICER and MEYER (1960) stated that sulfated mucopolysaccharides were stained strongly with AF and stained always with the first dye in the AF-AB or AB-AF sequence, whereas nonsulfated ones were stained relatively weak with AF and stained with the second dye in the AF-AB or AB-AF procedure. From the above-mentioned results, it may well be that the mucin substrates of the goblet cells in the infundibulum are compounds of nonsulfated and sulfated mucopolysaccharides, and that the former is more prevalent than the latter.

The previous authors (BRADLEY, and RICHARDSON) found that the goblet cells of the magnum had stronger affinity for mucin stains than those of any other portion of the oviduct. In the present study, goblet cells showed strong PAS-reactivity, affinity to alcian blue or colloidal iron, and metachromasia with toluidine blue in the magnum, as in the infundibulum. The present data, therefore, will clearly indicate the presence of nonsulfated mucopolysaccharides. On the other hand, the goblet cells of these portions were stained strongly reddish-purple with AF, purple with AF-AB, and blue with AB-AF. These findings suggest the presence of sulfated mucins in those cells, according to the opinion of SPICER and MEYER cited above. Furthermore, the incomplete disappearance of metachromasia and alcianophilia after methylation seems to support the presence of sulfated mucins in the cells. From these results, it may well be that the mucin substrates of the goblet cells of the magnum are compounds of sulfated and nonsulfated mucopolysaccharides, and that the former is more prevalent than the latter.

The goblet cells of the isthmus showed conspicuously different histochemical reactions from those of the magnum. They were strongly PAS-positive, diastase-resistant,

and of nonbasophilic character. These properties of mucin suggest the presence of neutral mucopolysaccharides, according to SPICER (1961). This suggestion is ascertained by the fact that the positive PAS reaction of mucin was completely eliminated by the treatment with phenylhydrazine. SPICER (1961) pointed out that the Schiff reactivity of the periodate-derived aldehyde in neutral mucin was readily blocked by phenylhydrazine; in other words, these mucins became no reactive with the Schiff reagent. Further evidence is that the mucin was stained light red with AB-PAS. MOWRY and MORAND (1957), who first advocated the AB-PAS method, stated that neutral mucins were stained red and acid ones blue or various colors by this method. Accordingly, the mucin substrates of the goblet cells of the isthmus were identified as neutral mucopolysaccharides.

On the goblet cells of the uterus, there are different opinions. BRADLEY found that the mucin stains used by him stained the goblet cells of this portion faintly only when applied to them for a prolonged time, and stated that these goblet cells had "a puzzling feature". On the contrary, CHAKRAVORTI reported, as mentioned above, that they were readily stained with usual acid mucin stains. In the present study, the goblet cells of the uterus were PAS-positive, although they were less intense in positivity than those of any other portion of the oviduct. The PAS-reactivity resisted to saliva digestion, and it was very liable to phenylhydrazine blockage. They were not basophilic, but showed pronounced sulfation-induced metachromasia. These histochemical reactions were identical with those given by the goblet cells of the isthmus. Therefore, it is probable that the mucin substrates of the goblet cells of the uterus are the same as neutral mucopolysaccharides contained in those of the isthmus, and that they are small in quantity, because of their weak PAS positivity.

The previous authors (BRADLEY, and RICHARDSON) stated that the goblet cells of the vagina were readily stained with usual mucin stains, although they were stained far less strongly than those of the magnum. CHAKRAVORTI observed the presence of acid mucins in goblet cells. In the present study, the PAS, alcian-blue or colloidal-iron, and toluidine-blue reaction were all intensively positive. These results suggest that acid mucopolysaccharide may be presented in goblet cells. The metachromasia of mucin, however, was pronounced only at a pH value below 4.1 and was so characteristic as to disappear entirely through alcohol dehydration. This "false metachromasia" was observed by QUINTARELLI et al (1961) in the submaxillary and sublingual glands of the rat and ox. These glands contain sialomucins. However, the goblet cells of the vagina did not contain sialic acid at all, because sialidase digestion for mucin failed in them. On the other hand, the lack of affinity for aldehyde fuchsin and staining by the AF-AB procedure did not show the presence of sulfated mucins. Judging from these results, the entire disappearance of metachromasia and alcianiphilia after methylation, and restoration of them by saponification following methylation, the mucin substrates of the goblet cells of the vagina seem to contain nonsulfated acid mucopolysaccharides.

SUMMARY

Mucopolysaccharides of the goblet cells in the mucosa of the chicken oviduct were

examined histochemically. The results obtained are summarized as follows.

1. The goblet cells of the oviducal mucosa were different not only in the appearance and arrangement in the epithelium, but also in the histochemical properties of mucin they contained, depending on the portion of the oviduct they were located.

2. The goblet cells of the infundibulum and those of the magnum manifested essentially the same histochemical reactions. They were periodic acid-Schiff (PAS)-reactive, alcianophilic, and metachromatic in character. These characters were more pronounced in the magnum than in the infundibulum. From these findings and the results of methylation and saponification following methylation, it was concluded that the mucin substrates of the goblet cells were compounds of nonsulfated and sulfated acid mucopolysaccharides. The goblet cells of the infundibulum were mainly composed of nonsulfated mucin, and those of the magnum of sulfated mucin.

3. The goblet cells of the isthmus were PAS-reactive, diastase-resistant, and nonbasophilic in character. Their PAS-reactivity was blocked by phenylhydrazine. They were stained red by the alcian blue-PAS (AB-PAS) method. Accordingly, the mucin substrates of these cells were identified as neutral mucopolysaccharides.

4. The goblet cells of the uterus showed the same histochemical reactions as those of the isthmus, although their reactions were less remarkable than those exhibited by the latter. Therefore, the mucin substrates of the uterin goblet cells were probably neutral mucopolysaccharides. The goblet cells at the anterior narrow region of the uterus showed the presence of acid mucopolysaccharides.

5. The goblet cells of the vagina were strongly PAS-reactive, alcianophilic, and metachromatic in character, but had no affinity for aldehyde fuchsin. The mucin substrates of these cells seemed to be nonsulfated acid mucopolysaccharides.

REFERENCES

- ABUL-HAJ, S.K., and J.F. RINEHART: Fuchsin-aldehyde staining of sulfated mucopolysaccharides and related substances. *J. Nat. Cancer Inst.*, **13**, 232-233(1952).
- AITKEN, R.N.C., and H.S. JOHNSTON: Observations on the fine structure of the infundibulum of the avian oviduct. *J. Anat.*, **97**, 87-99(1963).
- ARCADI, J.A.: Some polysaccharide components of the prostate gland of the dog. *Anat. Rec.*, **112**, 593-607(1952).
- BRADLEY, D.C.: Note on the histology of the oviduct of the domestic hen. *J. Anat.*, **62**, 339-345(1928).
- CHAKRAVORTI, K.P., and D.P. Sadhu: Some aspects of the histological and histochemical studies on the oviduct of the hen, *Gallus domesticus*. *Proc. Zool. Soc. (Calcutta)*, **14**, 27-32(1961).
- FISHER, E.R., and R.D. RILLIE: The effect of methylation on basophilia. *J. Histochem. Cytochem.*, **2**, 81-87(1954).
- GIERSBERG, H.: Untersuchungen über Physiologie und Histologie des Eileiters der Reptilien und Vögeln, nebst einem Beitrag zur Fasogenese. *Z. wiss. Zool.*, **120**, 1-97(1923).
- HALMI, N.S., and J. DAVIES: Comparison of aldehyde fuchsin staining, metachromasia and periodic acid-Schiff reactivity of various tissues. *J. Histochem. Cytochem.*, **1**, 447-459(1953).
- JOHNSTON, H.S., R.N.C. AITKEN, and G.M. WYBURN: The fine structure of uterus of the domestic fowl. *J. Anat.*, **97**, 334-344(1963).
- LEWIS, P.R., and T. A.I. GRILLO: Histochemical demonstration of carbohydrates by a convenient sulfation technique. *Histochemie*, **1**, 3931-402(1959).

- LILLIE, R.D.: Histopathologic technique and practical histochemistry, Blakiston, New York (1954).
- LILLIE, R.D.: The Nile blue reaction of peptic gland zymogen granules: the effect of methylation and alkali demethylation. *J. Histochem. Cytochem.*, **6**, 130-132 (1958).
- McMANUS, J.F.A.: Histological and histochemical uses of periodic acid. *Stain Technol.*, **23**, 99-108 (1948).
- MOWRY, R.W.: Alcian blue techniques for histochemical study of acidic carbohydrates. *J. Histochem. Cytochem.*, **4**, 407 (1956).
- MOWRY, R.W., and J.C. MORAND: Distribution of acid mucopolysaccharides in normal kidney, as shown by the Alcian blue-Feulgen (AB-F) and Alcian blue periodic acid-Schiff (AB-PAS) stains. *Amer. J. Pathol.*, **33**, 620-621 (1957).
- QUINTARELLI, G. S. TSUKI, Y. HASHIMOTO and W. PIGMAN: Studies of sialic acid-containing mucins in bovine submaxillary and rat sublingual glands. *J. Histochem. Cytochem.*, **9**, 176-183 (1961).
- RICHARDSON, K.C.: The secretory phenomena in the oviduct of the fowl, including the process of shell formation examined by the microincineration technique. *Phil. Trans. Roy. Soc. Lond., Series B*, **225**, 149-194 (1935).
- RINEHART, J. F., and S. K. ABUL-HAJ: *Arch. Pathol.*, **52**, 189 (1951) (quoted by Pearse's *Histochemistry, Theoretical and Applied*, J. A. Churchill Ltd. London (1960)).
- SPICER, S.S.: Histochemical differentiation on mammalian mucopolysaccharides. *Ann. N.Y. Acad. Sci.*, **106**, 379-388 (1961).
- SPICER, S.S., and R.D. LILLIE: Saponification as a means of selectively reversing the methylation blockade of tissue basophilia. *J. Histochem. Cytochem.*, **7**, 123-125 (1959).
- SPICER, S.S., and D.B. MEYER: Histochemical differentiation of acid mucopolysaccharides by means of combined aldehyde fuchsin-Alcian blue staining. *Amer. J. Clin. Pathol.*, **33**, 453-460 (1960).
- SURFACE, F.M.: The histology of the oviduct of the domestic hen. *Ann. Rep. Maine Agric. Exp. Station*, **206**, 395-430 (1912).

鶏の卵管杯細胞の粘液多糖体の組織化学的研究

藤井俊策・田村達堂・国崎 格

鶏の卵管粘膜は、その全長を通じて一様に柱形繊毛細胞と杯細胞より成る単層上皮によって覆れている。この杯細胞は卵管の各部位において、形や分布が著しく特徴的であることから、分泌粘液にも差があることが推察される。そこで卵管各部の杯細胞の粘液物質を組織化学的に調べた。

卵管漏斗部の杯細胞は非硫酸化-と硫酸化粘液多糖体を含み、とくに非硫酸化粘液多糖体に富むようである。膨大部(卵白分泌部)の杯細胞は漏斗部に似て、非硫酸化-と硫酸化粘液多糖体の複合より成るが、末端に移行するに従い硫酸化粘液多糖体が増してくる。膨大部末端ではほとんど硫酸化粘液多糖体のみより成る。峽部の杯細胞は膨大部のそれとは全く異り中性多糖体を含む。子宮部(卵殻粉分泌部)の杯細胞は峽部に似て中性多糖体を持つようであるが、峽部に比べて量的には少い。膣部の杯細胞は非硫酸化粘液多糖体を持つ。以上のごとく卵管上皮の杯細胞は、卵管の各部において形態的のみならず分泌物の組織化学的組成において異なることが知られた。