

Cytological Studies on Abnormal Ova in Mature Ovaries of Mice observed at Different Phases of Oestrous Cycle

Tsunenori NAKAMURA

*Department of Animal Husbandry, Faculty of Fisheries
and Animal Husbandry, Hiroshima University, Fukuyama*

(Tables 1-3; Pls. 1-5; Text-figs. 1-2)

(I) INTRODUCTION

The cyclic changes of the sex organ are more pronounced in mammals than in other animals; they are known as an oestrous cycle, and occur at different intervals of days or weeks according to the species. It is only during a period of the oestrus that the mature eggs are produced in the ovary, and the female becomes sexually receptive so that fertilization can occur. The oestrous cycle has so far been most closely studied in rodents, particularly in the Muridae, since they breed in every season through the year. For example, an unmated female mouse ovulates repeatedly about once every 5 days from the age of 60 days. KNAUER ('96) seems to be the first who studied the mechanism of ovulation, and STOCKARD & PAPANICOLAOU ('17) dealt with the maturation process in the Graafian follicles using the smear method with vaginal contents. ALLEN ('21) put forward a theory on the oestrous cycle in the Muridae. PARKES ('43), CASIDA ('44), ZWADOWSKY ('45), ROBINSON ('49), and RAESIDA & LAMOND ('56), etc. reported the effects of estrogen and pregnant mare serum following the administration to higher vertebrates.

The cytological study has revealed that a great number of ova are produced in the mammalian ovary during the oestrous, but the majority of them undergo degeneration, only a few attaining maturation, and developing into functional ova. MAKINO ('41) and SIGEMORO ('47) reported the cytological features of normal and abnormal follicles in mature ovaries of mice and rats. The atretic follicles that are destined to undergo degeneration without growing into the functional follicle are also morphologically investigated by ASAMI ('20), BRANCA ('25), ENGLE ('27), PAROES ('31), EREUD & VEDDER ('38), PLISKE ('40) and SIGEMORO ('47).

The present paper deals with cytological observations on abnormal ova which showed advance towards the first maturation division in mature mouse ovaries during the normal and abnormal sexual cycles. Also this is the first report as a cytological research with particular concern for the influence of pituitary gonadotrophic hormones on the atretic follicular apparatus of mature female mice.

The author wishes to acknowledge his great indebtedness to President Dr. J. YAMANE of the Hiroshima Agricultural College and Prof. Dr. S. MAKINO of the Hokkaido Uni-

versity for their expert advice and kind help in the preparation of the manuscript. Sincere thanks should be extended also to Mr. H. MORITA for his technical assistance during the course of this study.

(II) MATERIAL AND METHOD

Unmated mature female mice (*Mus musculus*) at 70~120 days of age furnished the material for the present study; they are Swiss-albinos purely bred in our laboratory. The ovaries of 33 individuals were used as material: 30 specimens out of them showed a normal sexual cycle with the vaginal smear method, while 3 individuals were abnormal in sexual cycle. The ovaries were fixed with Bouin's solution. The sections were made according to the usual paraffin method and stained with Heidenhain's iron-haematoxylin. The work was carried out during from late autumn to early summer.

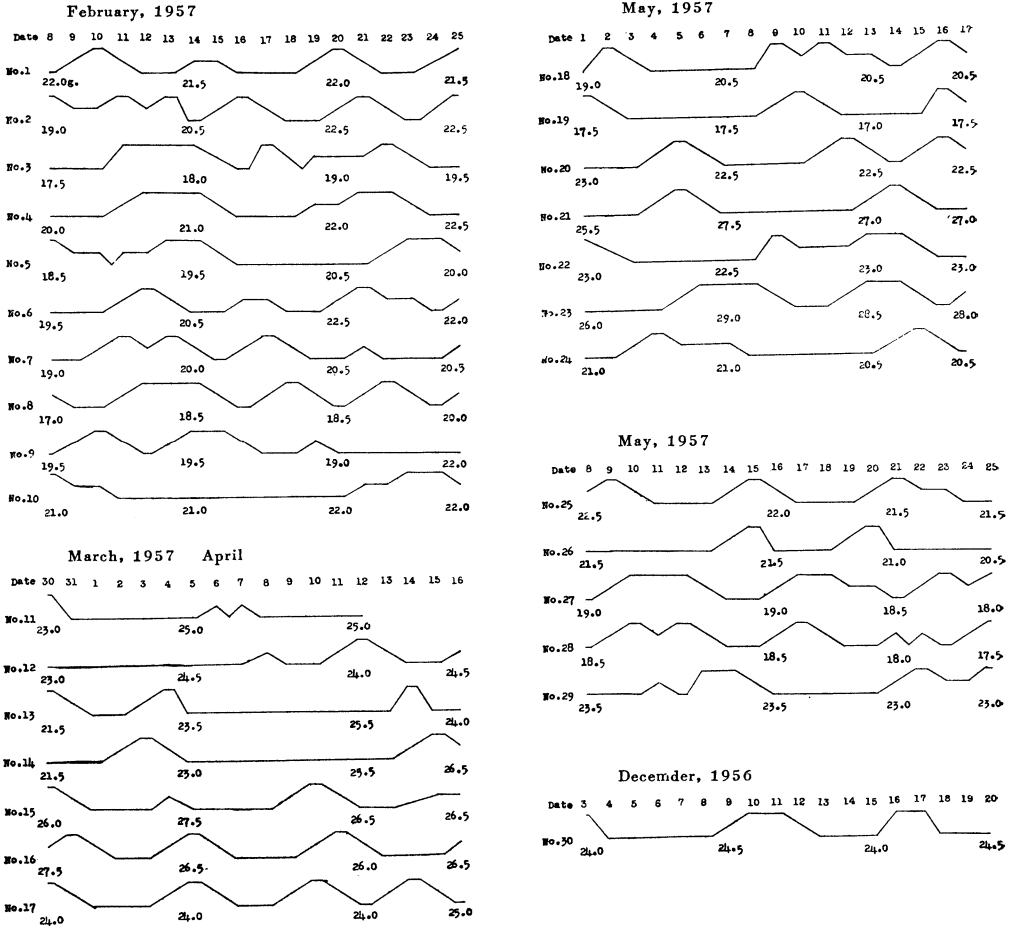
(III) OBSERVATIONS

1. The mature ova in mice with a normal sexual cycle

Functional mature ovum of the mouse which showed a normal sexual cycle was found in the Graafian follicle before its rupture. The ovum contained in the Graafian follicle is surrounded by a gelatine membrane, called *zona pellucida*, and the latter again by *corona radiata*. Surrounding the *corona radiata* there are granulosa cells which enclose a huge cavity filled up with the fluid, *liquor folliculi*. In the mature follicle being 217~290 μ in diameter, the mature ovum shows a diameter of 51~82 μ . Following the penetration of the spermatozoon the ovum generally reduces in diameter. After the disappearance of the nuclear membrane, the chromosomes arrange on the equatorial plate to form the first polar spindle in the ovum. After the division of chromosomes, the outer pole of the spindle which upheaves on the egg surface gets extruded as the first polar body. The ovum thus undergoes the first maturation division prior to ovulation, and still further advances in its maturation course up to the metaphase stage of the second division. The maturation process in the ovum stops at this stage, until insemination occurs following ovulation. The detailed descriptions regarding the maturation phenomena on the normal mature ovum in mice are referred to the paper by MAKINO ('41).

The author chanced to observe some Graafian follicles which had a great antrum (Pl. 1, figs. 7-9): the ovum has undergone the second maturation division carrying the first polar body, and lies practically free from the granulosa cells and the *corona radiata* cells, suspended in a naked state in the *liquor folliculi* (Pl. 1, fig. 9).

The other abnormal ova showed the chromosomes which arrange on the equatorial plate with the first polar spindle, having no nuclear membrane and antrum (Pl. 4, figs. 23-24). Some ova showed the second polar spindle at metaphase accompanied by the first polar body in the follicle with a few antra (Pl. 1, fig. 2); this type of abnormality is rather common



Text-fig. 1. Oestrous cycles and body weights in thirty mice.
 The upper level indicates oestrus, the lower level, dioestrus, and numbers under the line denote body weight (gram.).

in mature ovaries. Some others showed the completion of the second division offering the second polar body, through the *antrum folliculi* has not been formed (Pl. 5, fig. 28). There were also found abnormalities of chromosomes (Pl. 1, figs. 1, 6), and the first division showing a tetra-polar spindle (Pl. 3, figs. 16-17). The irregularity in shape of the ovum was also common; in the extreme case, the ovum contained many vacuoles in the ooplasm (Pl. 3, figs. 14-15). The atretic follicles which advance towards the maturation course were rather abundant in number; 85 examples were found in 30 individuals under study. Thirty-two follicles from 12 ovaries of 6 individuals were at the phase of proestrus; 15 follicles from 10 ovaries were at the stage of oestrus; 8 follicles from 14 ovaries were metoestrus; 4 follicles from 8 ovaries were dioestrus; 26 follicles from 16 ovaries were late dioestrus. Based on the vaginal smear method, the number of mature ovaries at five stages of oestrous cycle is graphically indicated in Text-fig. 2. It is shown that the atretic follicles at the stage of the proestrus are very frequent through the oestrous cycle. The data pre-

sented here suggest a numerical relationship between the atretic follicles and the normal mature follicles in an ovary. It seems probable that in the course of degeneration the disintegration takes place in both the egg body and the granulosa cells, and as a result it exerts some influence on the hormone secretion in the mature ovary.

For the sake of convenience, the stages of atretic follicles are divided into two general types. Type I refers to the small primary follicle with several rows of granulosa cells: some of them show the *antrum folliculi* consisting of several rows of granulosa cells, while some others contain no *antrum folliculi*. Type II deals with all follicles which advance to the maturation phase; they mostly have no antrum, though a few show an antrum. The

Table 1. Mature normal and abnormal follicles from sixty ovaries of mice with normal oestrous cycle.

Mouse Number	Body weight in gram.	Phase of oestrous cycle	Normal mature follicle			Abnormal follicle			Polyovular follicle		
			Ovary		Total	Ovary		Total	Ovary		Total
			Right	Left		Right	Left		Right	Left	
No. 6	22.0	Proestrus	2	3	5	1	3	4	2	0	2
No. 7	20.5	"	3	2	5	2	1	3	0	3	3
No. 8	20.0	"	4	7	11	0	3	3	1	3	4
No. 12	24.5	"	7	9	16	5	5	10	3	3	6
No. 16	26.5	"	1	2	3	3	5	8	1	0	1
No. 23	28.0	"	2	3	5	1	3	4	1	1	2
<hr/>											
No. 1	21.5	Oestrus	1	3	4	1	0	1	0	3	3
No. 2	22.5	"	3	2	5	0	0	0	1	2	3
No. 27	18.0	"	0	2	2	3	2	5	0	0	0
No. 28	17.5	"	1	1	2	3	4	7	2	0	2
No. 29	23.0	"	5	2	7	0	2	2	1	0	1
<hr/>											
No. 5	20.0	Metoestrus	1	1	2	0	0	0	1	1	2
No. 10	22.0	"	4	4	8	0	1	1	4	2	6
No. 14	26.5	"	1	3	4	1	0	1	1	0	1
No. 15	26.5	"	0	2	2	0	1	1	1	1	2
No. 18	20.5	"	4	1	5	2	0	2	1	0	1
No. 19	17.5	"	3	2	5	1	1	2	3	1	4
No. 20	22.5	"	2	0	2	0	1	1	2	0	2
<hr/>											
No. 11	25.0	Dioestrus	0	0	0	0	0	0	0	1	1
No. 17	25.0	"	0	0	0	1	1	2	3	2	5
No. 26	20.5	"	0	0	0	0	0	0	0	1	1
No. 30	24.5	"	0	0	0	2	0	2	1	1	2

No. 3	19.5	Late Dioestrus	1	2	3	2	2	4	1	0	1
No. 4	22.5	"	4	4	8	3	2	5	5	0	5
No. 9	22.0	"	6	7	13	2	2	4	1	2	3
No. 13	24.0	"	3	4	7	2	0	2	1	2	3
No. 21	27.0	"	5	4	9	2	2	4	2	2	4
No. 22	23.0	"	3	4	7	1	1	2	3	1	4
No. 24	20.5	"	7	5	12	0	1	1	0	3	3
No. 25	21.5	"	2	3	5	1	3	4	1	2	3

Table 2. Abnormal mature follicles in six ovaries from mice having abnormally long dioestrus cycle.

Mouse Number	Body weight in gram.	Normal mature follicle		Abnormal follicle		Polyovular follicle				
		Ovary	Total	Ovary	Total	Ovary	Total			
		Right : Left		Right : Left		Right : Left				
No. 2'	23.0	0	0	0	3	1	4	1	1	2
No. 14'	22.0	0	0	0	0	2	2	0	2	2
No. 16'	22.5	0	0	0	2	2	4	1	2	3

Table 3. Total number of normal mature follicles and abnormal follicles in mice taken at different phases of the oestrous cycle.

Phase of oestrous cycle	Number of individual	Normal mature follicle	Abnormal follicle	Polyovular follicle
Proestrus	6	45	32	18
Oestrus	5	20	15	9
Metoestrus	7	28	8	18
Dioestrus	4	0	4	9
Late Dioestrus	8	64	26	26
Long Dioestrus	3	0	10	7

follicles belonging to type I are found in the ovum before the first maturation division, whereas type II in the ovum undergoing the first maturation division. The number of type II as observed in 60 ovaries was 85 follicles, while normal mature ova were 157 in number, as given in Tables 1 and 3. The degenerating follicles belonging to type II range in diameter from 158 to 237 μ .

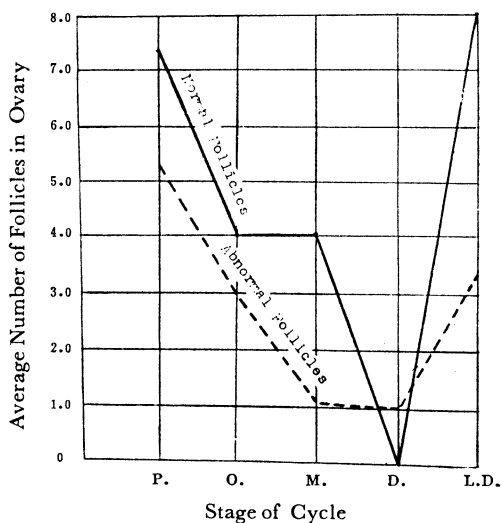
Many papers have been published on the polyovular follicles, discussing the view of twinning presented by HARTMAN ('26). The present study with mice, 70~120 days of age, has revealed that the polyovular follicle is rather rare in occurrence; 80 polyovular follicles were found to occur in 60 ovaries under study. They were biovular follicles in 78%, triovular follicles in 16% and tetraovular follicles in 6%. The majority of poly-

ovular follicles were small in size with no antrum. It seems most probable that the polyovular follicles are in the process of degeneration without the establishment of the *antrum folliculi*. Only three biovular follicles were found in the stage of the antrum formation. One of them showed an ovum advancing to the maturation division, while the other remained without the first maturation division (Figs. 4-5). There were also two other examples in which the first maturation spindle was formed in the ovum (Pl. 4, fig. 21). The evidence presented seems to suggest that polyovular follicles originate from fusion of the previously separated follicles, or arise through abnormal nuclear division, though there are a few polyovular follicles which resulted in the separation of an original ovum. In general, they are in the process of disintegration without advancing to the ovulation stage.

2. The mature ova in mice with an abnormal sexual cycle

The three unmated mice aged from 70 to 120 days, which had shown an abnormally long dioestrus cycle were studied, and the data obtained are presented below (Table 2).

In six ovaries, mature ova showing the second maturation division with the first polar body are abundant in number, being 10 in total. The Graafian follicles in which the above ova were involved showed no remarkable feature and the antrum follicles have not been formed (Fig. 29). There was an example which showed a mature ovum undergoing the abnormal division of chromosomes (Pl. 5, fig. 30). Polyovular follicles were also found to occur in a few follicles. They all offer obvious evidence of atresia. It is most probable that they do not develop into the ovulation stage, and that such atretic follicles may cause abnormally long dioestrus cycle, probably due to the influence of the anterior pituitary hormone.



P. Proestrus; O. Oestrus; M. Metoestrus; D. Dioestrus; L. D. Late Dioestrus.

Text-fig. 2. Average number of normal mature follicles and abnormal follicles in the ovary at five stages of the estrous cycle.

(IV) DISCUSSION

The literature relating to atretic follicles that contain abnormal and polyovular follicles has been repeatedly published by many authors (ASAMI '20, ENGLE '27, PLISKE '47, MAKINO '41, SIGEMORO '47). The results of the present investigation indicate that mature ova undergo degeneration without growing into the functional follicle through several abnormal processes during the maturation. ENGLE ('27) in the mouse and SIGEMORO ('47) in the rat have emphasized that in the course of degeneration the disintegration takes place in the egg body. On the other hand, ASAMI ('20), BRANCA ('25), EREUD & VEDDER ('38) and PLISKE ('40), all in the rat, have pointed out that the disintegration occurs in the granulosa cells. It is probable that the disintegration of the egg body is due to the influence of the anterior pituitary hormone. Probably the follicle-

stimulating hormone of the anterior pituitary induced rapid growth of a Graafian follicle; the growth may be partly achieved by multiplication of follicle cells and partly by the hormonal secretion into the antrum of the follicular fluid. It has been known that the follicular fluid contains a large amount of estrogen; the latter may increase the mitotic activity of follicle cells. Therefore, it may be the estrogen that practically causes the growth of the follicle. This may be proved by the investigation on the effect of estrogen or pregnant mare serum on the sexual cycle of mice.

Morphologically the atretic follicles are divided into two general types. Type I refers to the small primary follicle with several rows of granulosa cells, but having no *antrum folliculi*. Type II denotes the follicles which advance to the maturation division, the majority of which have an antrum. The present paper is concerned with some morphological aspects of atretic follicles of mice belonging to type II.

The occurrence of polyovular follicles is rather rare; 80 polyovular follicles were observed in 60 ovaries. According to SIGEMORO ('47) the total number of polyovular follicles in 120 mature rat ovaries from 60 individuals was found to be 375: among them 316 follicles (84%) were biovular. ENGLE ('27) reported 18 polyovular follicles based on one hundred ovaries in the mouse, and TAKEWAKI ('37) recorded a five-ova-containing follicle which occurred in ovaries from three individuals of the mouse. Concerning the origin of polyovular follicles, HARTMAN ('26) enumerated three possible ways of formation; 1) by division of polyovular ova, 2) by concrescence of previously separated follicles, 3) by persistent union of ova in the egg tube. The present author is of opinion that polyovular follicles arise by concrescence of previously separated follicles, by abnormal nuclear division of ova, and by separation of the original definitive ovum. A biovular follicle was found in which one ovum advancing toward maturation division and the other ovum was in the stage prior to the first maturation division (Pl. 1, figs. 4-5). There were also two other instances which showed the first maturation spindle in the ovum. Many investigators have been interested in polyovular follicles in relation to the problem of human twinning. Most of polyovular follicles observed in the present study, however, were found to be in the process of degeneration.

In the present study six ovaries derived from mice with abnormally long dioestrus cycle were cytologically investigated. HARTMAN ('23) reported that the disintegration of follicles initiated in the granulosa cells in the ovaries of mice which showed abnormally long dioestrus cycle. It is probable that the mice which showed a prolonged dioestrus also seem to be in a pseudopregnant condition.

It is of interest that many mature ova in mature ovaries of mice undergo the course of degeneration. The data given in Table 2 indicate that the abnormal ova observed in 60 ovaries were 85 in total. Considered from the data shown in Text-fig. 2, a large number of the atretic follicles deal with late dioestrus from proestrus. This may be an evidence that it associates with the problem of ovulation controlled by the influence of the hormone.

(V) SUMMARY

A cytological investigation has been carried out with the ova derived from 66 ovaries which were taken from a series of thirty-three mature unmated mice (*Mus musculus*, "Swiss

albinos") at different phases of the oestrous cycle, with special reference to the maturation and degeneration of ova in mature ovaries.

The atretic follicles of ova which showed advance towards the first maturation division are very abundant in number in the mature ovary, being 85 (35%) in total. The abnormal ova are mostly at the phase of proestrus in the oestrous cycle. It is most probable that the atretic follicles are in the process of degeneration, and the disintegration takes place either in the egg body or in the granulosa cells.

The polyovular follicles observed in 60 normal ovaries are 80 in total. Out of them 62 follicles (78%) contain biovular ones. The majority of polyovular follicles are in the process of degeneration, though there are a few examples which are suggestive of the possibility of their maturation.

The atretic follicles are very abundant in three mice which showed an abnormally long dioestrus cycle. From this evidence it is presumable that there is a relationship between the maturation of ova and the effect of the anterior pituitary hormone.

(VI) LITERATURE CITED

- ALLEN, E. 1923. Ovogenesis during Sexual Maturity. *Am. J. Anat.*, **31**: 439-480.
- ASAMI, G. 1920. Observations on the Follicular Atresia in the Rabbit Ovary. *Anat. Rec.*, **18**: 323-343.
- ENGLER, M. T. 1927. A Quantitative Study of Follicular Atresia in the Mouse. *Am. J. Anat.*, **39**, No. 2: 187-203.
- BULLOUGH, W. S. 1951. Vertebrate Sexual Cycles. Methuen's Monographs on Biological Subjects.
- GUYER, M. E. & E. C. PEARL. 1933. Induced Sterility. *Physiological Zool.*, **6**, No. 3: 253-288.
- LANE, Ch. E. 1938. Aberrant Ovarian Follicles in the Immature Rat. *Anat. Rec.* **71**: 243-245.
- MAKINO, S. 1941. Studies on the Murine Chromosomes, I. Cytological Investigations of Mice, included in the Genus *Mus*. *J. Fac. Sci. Hokkaido Imp. Univ. Ser. VI, Zool.* **7**: 305-380.
- 1947. Mammalian Ova. (In Japanese) *Rigaku Monograph* 7.
- NAKAMURA, T. & S. MAKINO. 1950. On the Degeneration of Germ Cells in Experimental Cryptorchid Testes of the White Rat. *Cytologia*, **16**, No. 1: 27-36.
- PARKES, A. S. *et al.* 1952. Marshall's Physiology of Reproduction. Vol. 3.
- PLISKE, E. C. 1940. Studies on the Influence of the Zona Pellucida in Atresia. *J. Morph.* **67**: 321-346.
- RAESIDA, J. I. & D. R. LAMOND. 1956. Effects of Progesterone and Pregnant Mare Serum Administration in the Anoestrous Ewe. *Aust. J. Agric. Rec.*, **7**, No. 6: 591-607.
- SIGEMORO, E. 1947. Morphological Observations of Abnormal Follicles in Mature Ovaries of the Norway Rat, *Rattus norvegicus*. *J. Fac. Sci. Hokkaido Univ. Ser. VI.* **9**: 233-241.
- & S. MAKINO. 1947. On the polyovular Follicles found in Ovaries of the Norway Rat, *Rattus norvegicus*. *Seibutu, Suppl. No. 1*: 63-67.

EXPLANATION OF PLATES 1-5

Plate 1.

Figs. 1-6. Ovum at proestrus.

Fig. 1. Chromosome abnormalities observed in a mature ovum.

Fig. 2. Ovum showing the second polar spindle at metaphase accompanied by the first polar body in the follicle with a few antra.

Fig. 3. First maturation division showing stickiness of chromosomes.

Figs. 4-5. Biovular follicles containing one ovum advancing toward the maturation, but other ovum is prior to maturation.

Fig. 6. Mature follicle showing the abnormal division of the ovum.

Plate 2.

- Figs. 7-12. Ovum at oestrus.
Figs. 7-9. Graafian follicles showing the normal course of maturation.
Fig. 10. Abnormal ovum with no antrum showing the first maturation spindle.
Figs. 11-12. Polyovular follicles.

Plate 3.

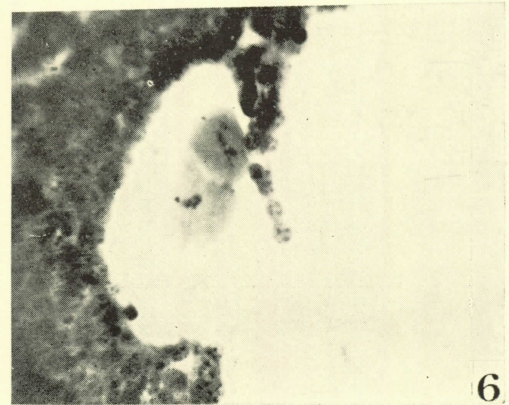
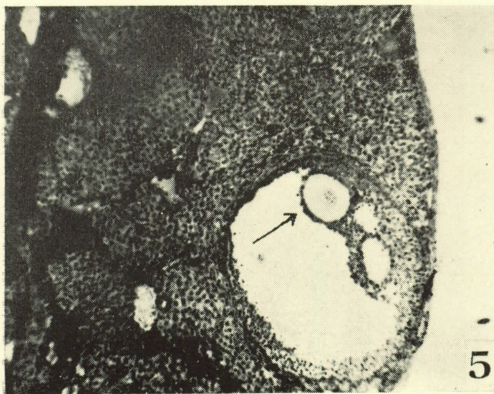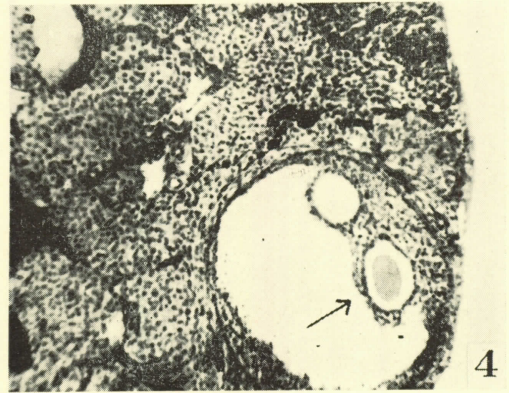
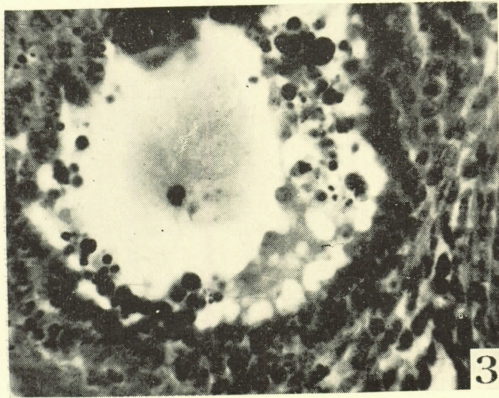
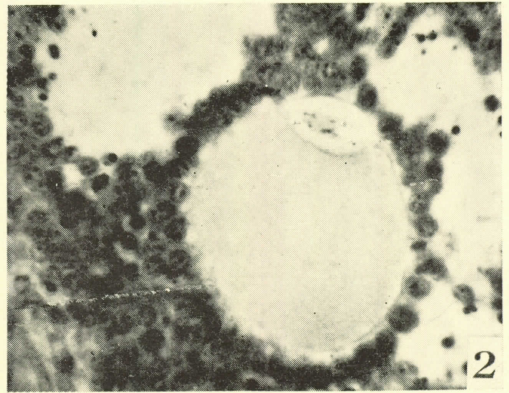
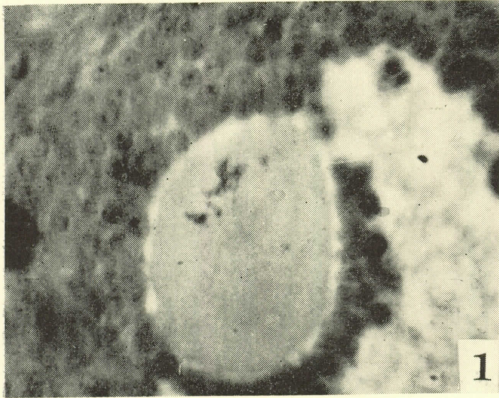
- Figs. 13-18. Ovum at oestrus.
Fig. 13. Abnormal ovum with a few antra showing the first maturation spindle.
Figs. 14-15. Abnormal ova showing vacuoles in the cytoplasm.
Figs. 16-17. Mature ova showing the metaphase of the first division
with tetra-polar spindles, probably in a bi-nucleate cell.
Fig. 18. Unshed ovum showing the second polar spindle at metaphase.

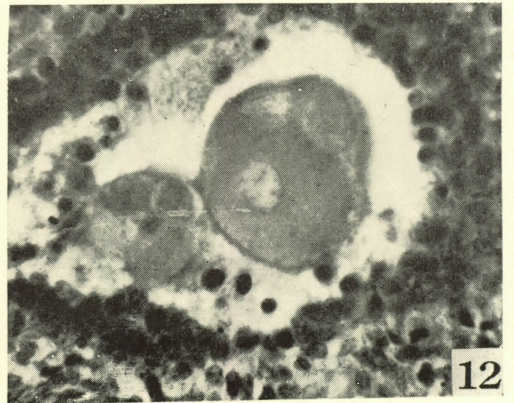
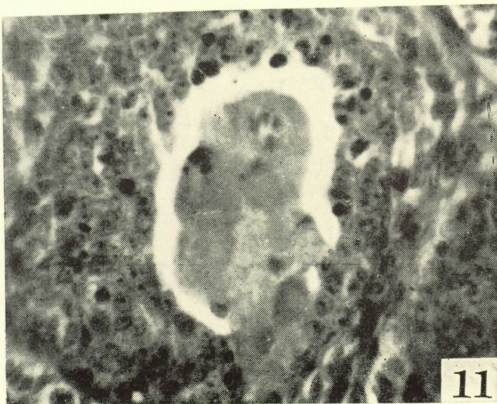
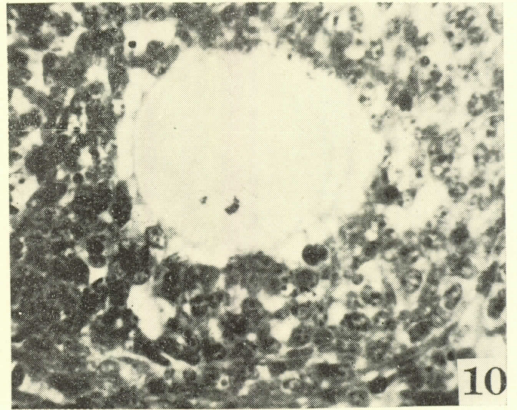
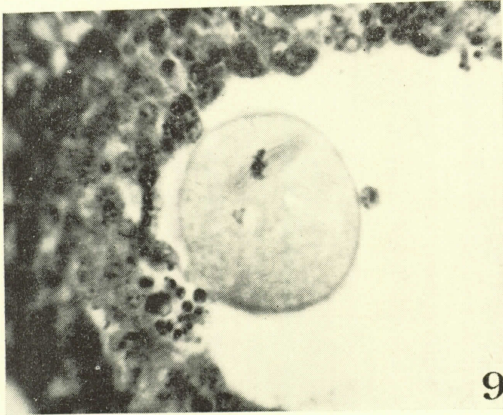
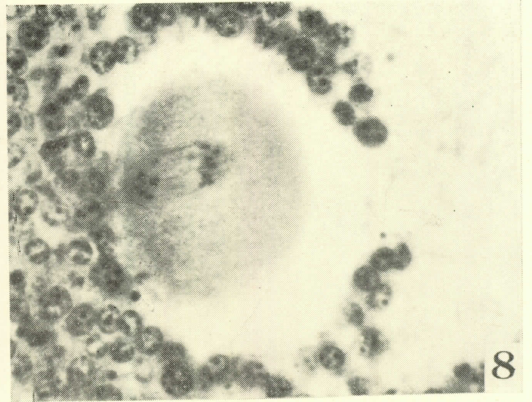
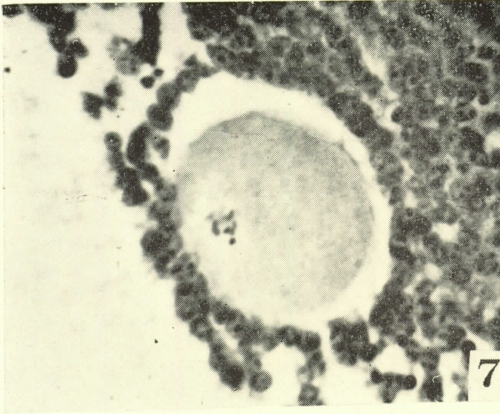
Plate 4.

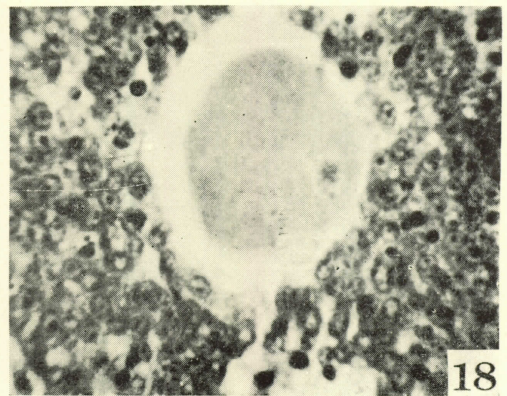
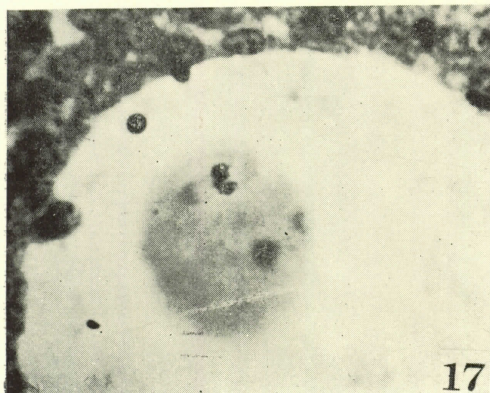
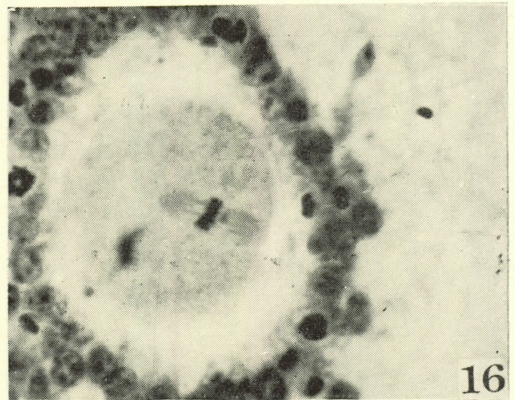
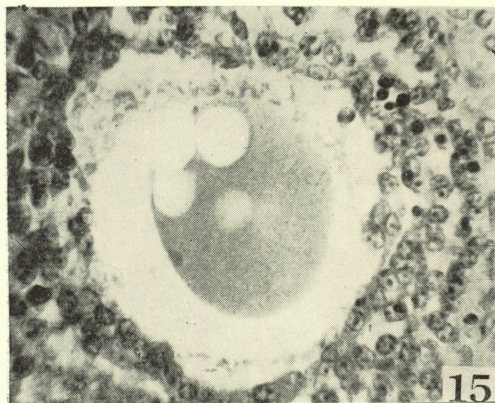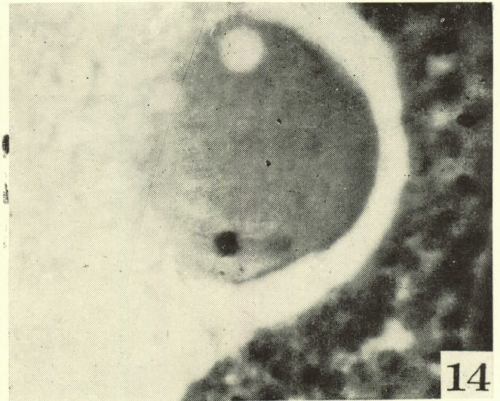
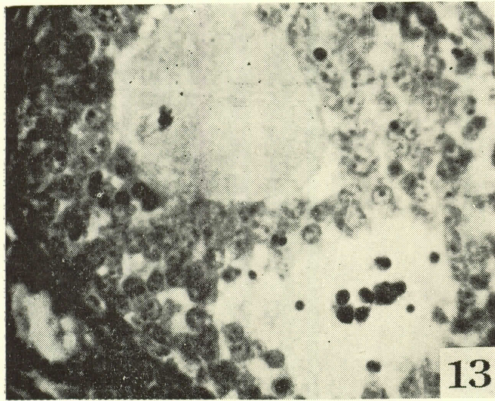
- Figs. 19-20. Ovum at metoestrus.
Fig. 19. Mature ovum undergoing the normal first maturation division.
Fig. 20. Bi-nucleate ovum.
Figs. 21-24. Ovum at dioestrus.
Fig. 21. Biovular follicle.
Fig. 22. Chromosome abnormalities observed in an ovum.
Figs. 23-24. Ova with no antrum showing the first maturation spindle at metaphase.

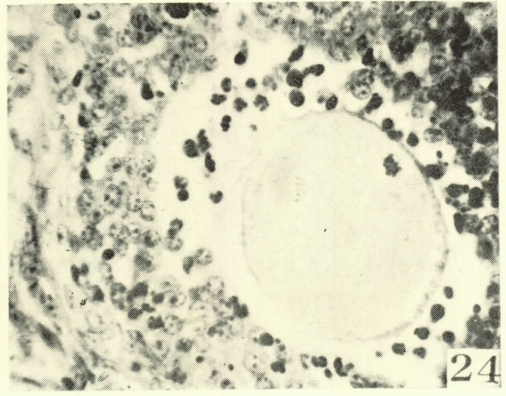
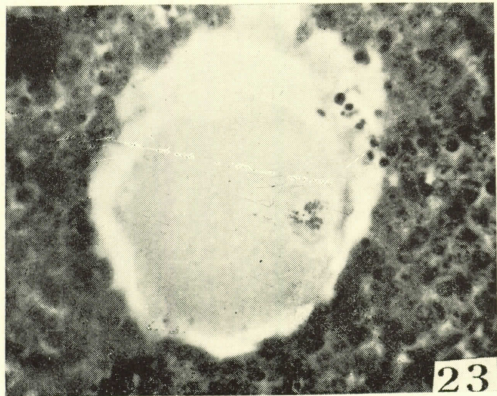
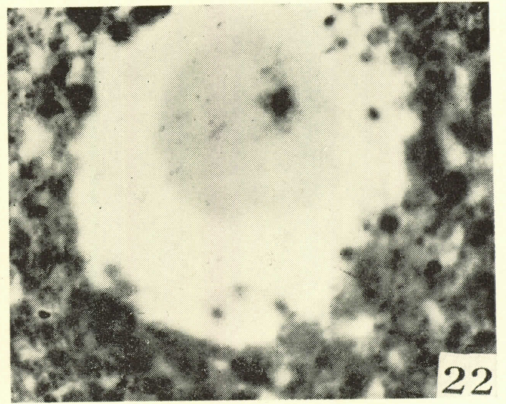
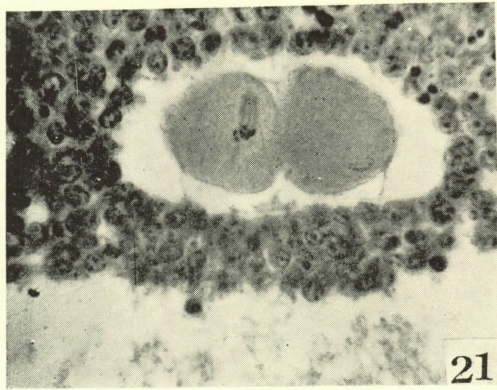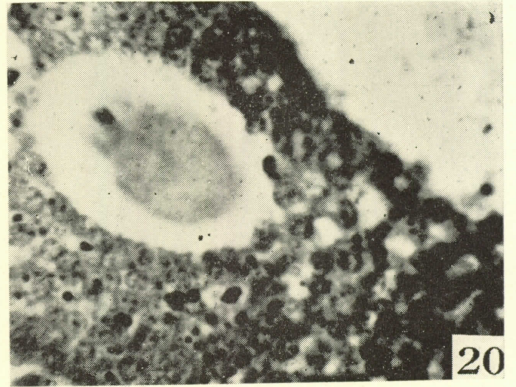
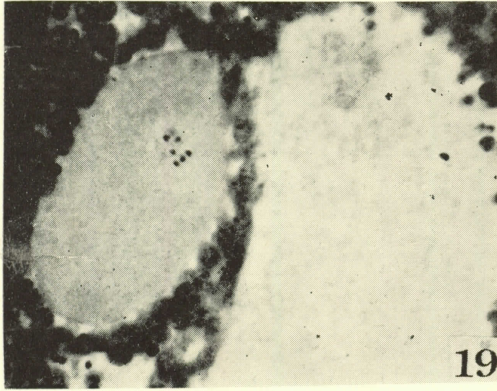
Plate 5.

- Figs. 25-28. Ovum at dioestrus.
Figs. 25-27. Abnormal ova showing the second polar spindle at metaphase with no antrum.
Fig. 28. Abnormal ovum showing the first and second polar bodies.
Figs. 29-30. Ovum at the long dioestrus.
Fig. 29. Unshed ova showing the second maturation spindle.
Fig. 30. Abnormal mature ovum undergoing the abnormal nuclear division.









NAKAMURA : Abnormal Ova of Mice

