

Effectiveness of Levamisole on Stromal Herpetic Keratitis*

Hiroshi SAKATA, Hideto YOSHIDA, Noboru HIYAMA,
Hideaki KONDO and Yuji HIRAKAWA

*Department of Ophthalmology, Hiroshima University School of Medicine, 1-2-3, Kasumi,
Minami-ku, Hiroshima 734, Japan*

(Received September 24, 1983)

Key words: Levamisole, Herpetic keratitis, Cellular immunity

ABSTRACT

Stromal herpetic keratitis has a poor prognosis. To date, corticosteroids appear to be the most efficacious agents against the condition. However, corticosteroids are immunosuppressive, and may cause recurrences. The recent findings of decreased cellular immunity in the condition offer the possibility of using levamisole as the therapeutic agent. The present investigation was undertaken to evaluate the clinical effects of levamisole on the twenty-one patients with stromal herpetic keratitis. Results were favorable in sixteen. The side effects of levamisole were relatively mild and transient. The results of the present study confirm the efficacy and safety of levamisole for the treatment of stromal herpetic keratitis.

INTRODUCTION

Treatment of stromal herpetic keratitis presents a difficult problem. Corticosteroid therapy in combination with antivirals is commonly employed to treat this condition, but may prolong the disease in some cases⁷⁾ and does not prevent a high rate of recurrences¹⁾.

It has recently been reported that decreased cellular immunity plays a role in determining the severity of stromal herpetic keratitis^{2, 4)}. If immunosuppression of the host is responsible for the pathogenesis of stromal herpetic keratitis, immunopotentiating drug may be effective against the disease. The findings obtained in previous experimental studies also suggest the effectiveness of levamisole against the disease^{10, 12)}.

The present investigation was undertaken to evaluate the clinical effects of levamisole on stromal herpetic keratitis.

SUBJECTS AND METHODS

Twenty-one patients with severe stromal herpetic keratitis and with a past history of devel-

opment of dendritic or geographic keratitis were treated with levamisole. Of these patients, fourteen eyes were diagnosed as a type of disciform keratitis (Fig. 1), six eyes as localized or diffuse parenchymatous keratitis (Fig. 2 and 3) and one eye as corneal deep ulcer (Fig. 4). The age of the patients ranged from 22 to 68 years. Levamisole at dose of 100 mg was given orally three consecutive days every week until keratitis disappeared, and once every week for three months after corneal inflammation became inactive. The average length of follow-up in these cases was 20 months and the minimum length was 6 months.

Topical application of cycloplegics, collagenase inhibitor and antibiotics were used in all cases, but IDU and corticosteroids were not applied. All patients had a complete eye examination during therapy. Blood examples were obtained for leucocyte classification and liver function test once every week. Tuberculin skin test was performed before and during therapy. When required for diagnostic purposes, viral isolation was attempted.

*1) 坂田広志, 吉田秀人, 日山 昇, 近藤英明, 平川裕二: 実質型角膜ヘルペスに対するレバミゾールの効果

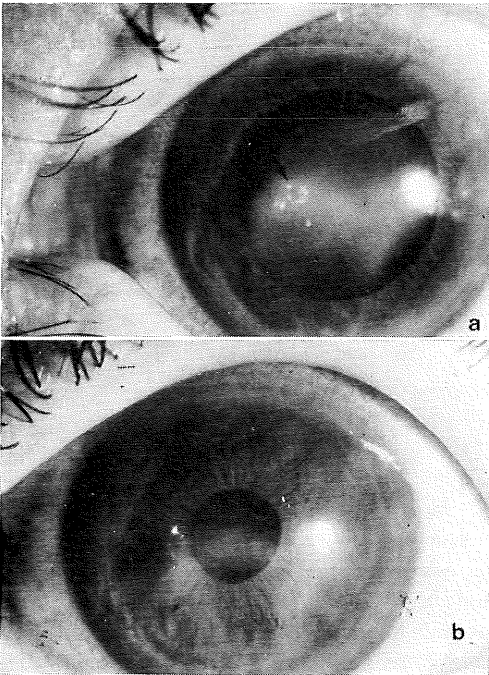


Fig. 1a. (Case 1) Disciform keratitis with atrophic ulcer (arrow).
1b. (Case 1) Same eye. Eight weeks after treatment.

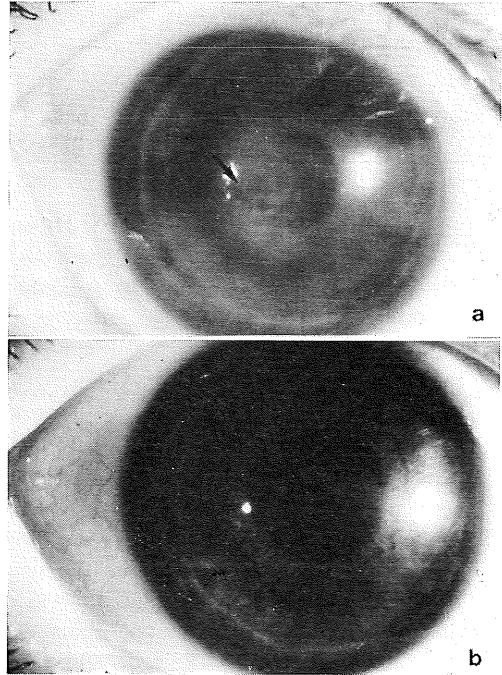


Fig. 3a. (Case 3) Diffuse parenchymatous keratitis with atrophic ulcer (arrow).
3b. (Case 3) Same eye. Three weeks after treatment.

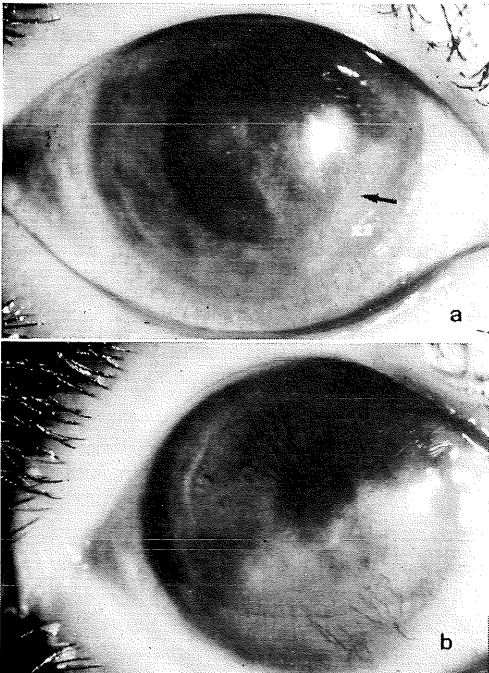


Fig. 2a. (Case 2) Localized parenchymatous keratitis with atrophic ulcer (arrow).
2b. (Case 2) Same eye. Eight weeks after treatment. Ulcer disappeared, but corneal vascularization developed.

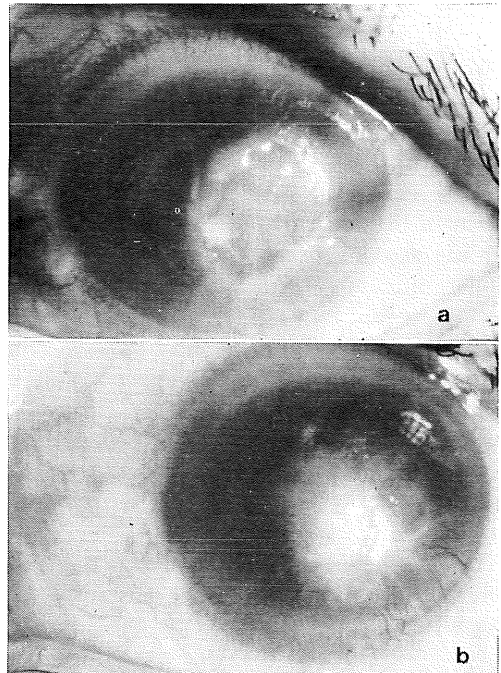


Fig. 4a. (Case 4) Corneal deep ulcer.
4b. (Case 4) Same eye. Eight weeks after treatment. Corneal vascularization developed, but ulcer disappeared.

RESULTS

1. Corneal inflammatory change

Of the twenty-one cases, sixteen responded to levamisole and the inflammatory changes in the corneal stroma disappeared within two to twelve weeks. The average period of disappearance was 4.9 weeks (Table 1). Five patients could not be controlled with levamisole and the drug was discontinued within three to four weeks after initial medication. Of the five patients, corneal inflammation of three cases aggravated, and that of two cases remained unchanged. These five cases responded to topical corticosteroids. Generally, the corneal lesion of cases who received levamisole therapy has healed leaving more marked opacities of the cornea than those of steroid-treated eyes.

2. Visual acuity

Only the best final visual acuity was used for this analysis. Of sixteen patients who responded to levamisole, twelve had a visual acuity of 0.2 or better. Visual acuity of one

case deteriorated from hand motion to light perception (Fig. 5).

3. Corneal vascularization

In most patients, pretreatment corneal deep vascularization became more marked after levamisole treatment. This finding was observed in three of fourteen cases with disciform keratitis (Fig. 6). The remaining eleven cases without pretreatment vascularization did not newly develop the condition. In one case with corneal deep ulcer (Fig. 4), neovascularization gradually progressed to the center of the ulcer; accompanied by epithelization. Of six cases with

Table 1. Period from initial medication to disappearance of keratitis (average: 4.9 weeks)

period (weeks)	cases
2	4
6	5
8	3
12	4

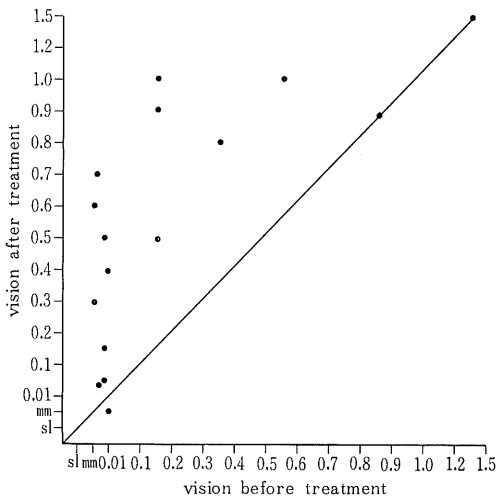


Fig. 5. Visual results of cases who responded to levamisole

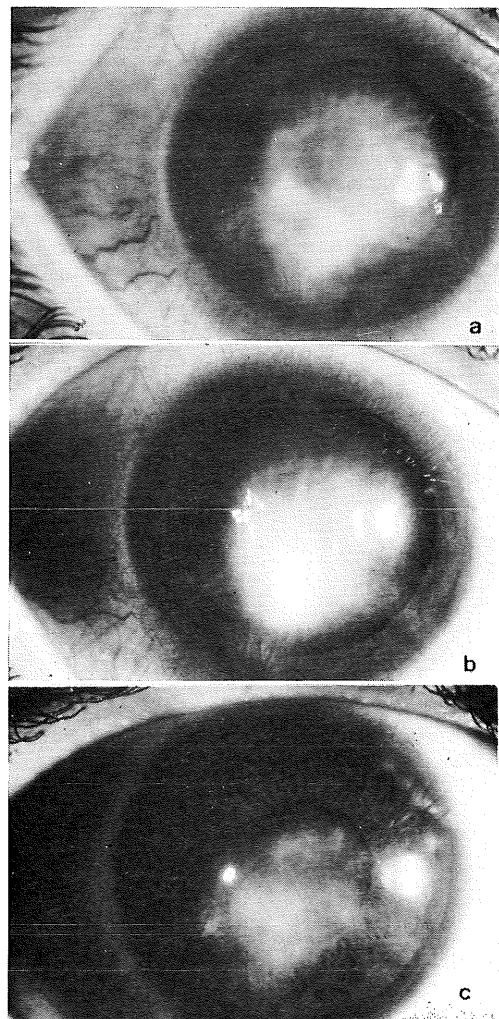


Fig. 6a. (Case 5) Severe disciform keratitis with corneal vascularization (arrow).
6b. (Case 5) Same eye. Two weeks after treatment.
6c. (Case 5) Same eye. Eight weeks after treatment.

localized or diffuse parenchymatous keratitis, corneal vascularization occurred in two cases with atrophic ulcer (Fig. 2). The remaining five cases did not develop corneal vascularization.

4. Previous steroid medication

Eight of twenty-one cases had received previous steroid medication. Of these, stromal keratitis in one case aggravated until two weeks from initial medication, but it thereafter subsided within twelve weeks (Fig. 6). Four cases took the same course as the case not receiving steroids. The remaining three cases did not respond to levamisole.

5. Tuberculin skin test

In thirteen of sixteen cases who responded to levamisole, tuberculin skin reactivity strongly increased one or two weeks from initial medication (Fig. 7).

6. Recurrence

Recurrences were observed in two of sixteen cases. One case developed dendritic keratitis at the twenty-first month after treatment was discontinued, and the other, stromal keratitis at the sixteenth month. The former responded to IDU and the latter responded to cortico-

steroids but not to levamisole and became steroid-dependent.

7. Complication

Three cases complained of abdominal discomfort for a few hours after medication. GTP value of one case increased to 68 U at the third week after initial medication, but returned to the normal level the following week. One case developed leucocytopenia. The pretreatment leucocyte count was 11,200/ml, which fell to 2,760/ml at the third week from initial medication but three days later it returned to the normal level. Two cases developed eruption of the extremities immediately after medication (Table 2).

Table 2. Complications during therapy

complication	cases
abdominal discomfort	3
eruption	2
impaired liver function	1

DISCUSSION

The etiology of stromal herpetic keratitis has long been disputed. Recently, evidence has been accumulated that severity of stromal herpetic keratitis depends on decreased cellular immunity of the host^{2,4}). The finding of decreased cellular immunity in the condition offers a possibility of using an immunopotentiating agent, levamisole, as therapeutic drug. Smolin et al.¹²) have obtained favorable results in treating experimental stromal herpetic keratitis in rabbits by levamisole. The present clinical investigation also demonstrated that levamisole has a remarkable effect on patients with stromal herpetic keratitis. So far the mechanism of levamisole potentiation of cellular immunity function, levamisole is considered to exert its therapeutic effect mainly through activated phagocytosis by polymorphonuclear cells⁹) or macrophages¹¹) and through increased function of T cells⁹). This has also been suggested by the findings of tuberculin skin test in patients who responded to levamisole in the present study.

Corticosteroids in combination with antivirals may shorten the duration of inflammatory process, but frequently fail to prevent a high rate of recurrences^{1,9}). The present finding that levamisole therapy is followed by a lower

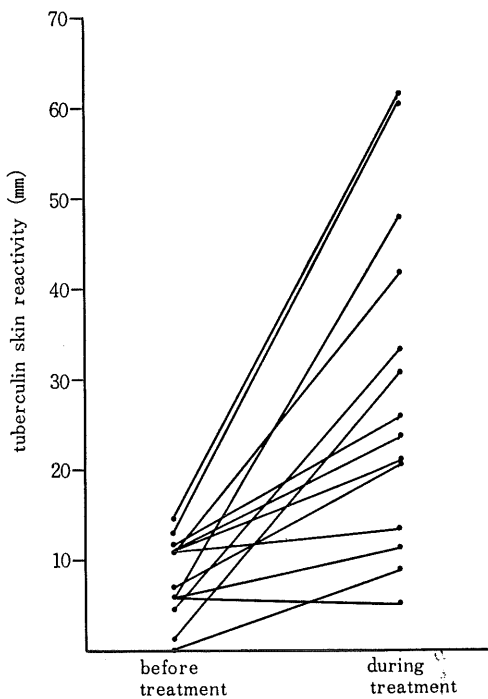


Fig. 7. Tuberculin skin test before and during treatment

recurrence is in good agreement with the results of Ohno et al.⁸⁾ So far recurrences, levamisole is superior to corticosteroids in combination of antivirals. The mechanism of a lower recurrence in levamisole-treated patients is unknown. Hiyam et al.⁵⁾ have documented that levamisole does not inhibit herpetic ganglionic latency in mice. It is assumed that augmentation of cellular immunity in the peripheral organs by levamisole is responsible for suppression of recurrences.

The side effects of levamisole must be carefully considered and monitored closely during therapy. In the present investigation, one patient developed transient leucocytopenia, three patients abdominal discomfort, and two patients eruption of the extremities. However, these symptoms were relatively mild and transient. The results of the present study confirm the efficacy and safety of levamisole for the treatment of stromal herpetic keratitis.

REFERENCES

1. **Caroll, M., Martola, E., Laibson, P.R. and Dohlman, C.H.** 1967. The recurrence of herpetic keratitis following idoxuridine therapy. *Am. J. Ophthalmol.* **63** : 103-107.
2. **Centifanto, Y.M., Zam, A.S., Mcneil, J.I. and Kaufman, H.E.** 1978. Leucocyte migration inhibitory factor in HSV infections. *Invest. Ophthalmol. Visual Sci.* **17** : 863-868.
3. **De Cree, J., Verhaegen, H., De Cock, W., Vanhenle, R., Brugman, J. and Scherman, S.V.** 1974. Impaired neutrophil phagocytosis. *Lancet* **2** : 294-298.
4. **Easty, D.L., Maini, R.N. and Jones, B.R.** 1973. Cellular immunity in herpes simplex keratitis. *Trans. Ophthalmol. Soc. U.K.* **93** : 171-180.
5. **Hiyama, N., Sakata, H., Yoshida, H., Kondo, H. and Hirakawa, Y.** 1983. Effectiveness of levamisole on herpetic ganglionic latency. *Hiroshima J. Med.* **32** : 219-222.
6. **Hiyama, N.** 1983. Studies on the effectiveness of levamisole on experimental herpetic keratitis in mice, 2. the effect of levamisole on cell-mediated immunity. *Folia Ophthalmol. Jpn.* **34** : in press.
7. **Hughes, W.F.** 1969. Treatment of herpes simplex keratitis. *Am. J. Ophthalmol.* **67** : 313-328.
8. **Ohno, S., Kato, F. and Matsuda, H.** 1982. Studies of immunotherapy for the herpetic stromal keratitis with levamisole. *Herpesvirus* edited by Shiota, H., *Excerpta Medica* **571** : 250-261.
9. **Polack, F.M., Burdette, M.G. and Sidrys, L.A.** 1982. Trifluorothymidine therapy of severe herpetic keratouveitis resistant to IDU and Vira-A. *Cornea* **1** : 29-33.
10. **Sakata, H.** 1980. Effectiveness of levamisole on experimental stromal herpes simplex keratitis. *Acta Soc. Ophthalmol. Jpn.* **84** : 175-182.
11. **Schulze, H.J. and Raettig, H.J.** 1973. Steigerung der Aktivität von Peritoneal Makrophagen der Maus durch Levamisole. *Vrh. Dtsch. Ges. Inn. Med.* **79** : 622-623.
12. **Smolin, G., Okumoto, M. and Friedlaender, M.** 1978. Treatment of herpes simplex keratitis with levamisole. *Arch. Ophthalmol.* **96** : 1078-1081.