

## A Case of Obstructive Jaundice Due to Abdominal Aneurysm Compression<sup>\*</sup>

Kiyohiko DOHI<sup>1)</sup>, Yasuhiko FUKUDA<sup>1)</sup>, Kenji NAKAGAWA<sup>1)</sup>,  
Masaharu TAKENAKA<sup>1)</sup>, Hiroshi YAHATA<sup>1)</sup>, Eiji ONO<sup>1)</sup>,  
Haruo EZAKI<sup>1)</sup>, Toshio NAKANISHI<sup>2)</sup>, Taku FUJIWARA<sup>2)</sup>  
and Yasuji TABE<sup>3)</sup>

- 1) *The Second Department of Surgery, Hiroshima University School of Medicine*  
2) *The First Department of Medicine Hiroshima University School of Medicine, 1-2-3, Kasumi, Minami-ku, Hiroshima 734, Japan*  
3) *The Department of Surgery, Hiroshima Sanatorium Hospital*

(Received September 25, 1984)

---

*Key words: Abdominal aneurysm, Complication, Obstructive jaundice*

---

### ABSTRACT

The authors have experienced a very rare case of obstructive jaundice resulting from direct compression of the region of the porta hepatis by an abdominal aneurysm developing below the renal artery, whose life was saved by an operation performed just before rupture of the aneurysm occurred. The case is reported.

### INTRODUCTION

The diagnosis of abdominal aneurysm is considered to be comparatively easy because a pulsating mass is palpable through the abdominal wall<sup>6)</sup>. However, it is difficult to grasp the state of compression of surrounding organs, because aneurysms develop at different sites with different morphologies and the compression symptoms they cause are various<sup>1, 6)</sup>.

We report here a very rare case of obstructive jaundice we experienced in which an abdominal aneurysm developing below the bifurcation of the renal artery directly compressed the region of the porta hepatis.

### THE CASE

- Patient: A 69-year-old female.
- Chief complaints: Jaundice, upper abdominal tumor.
- Past medical history: Gastric ulcer at age 68.
- History of present illness: Had hypertension (B. P. 200~190 mmHg) from the time she was 60 years old and was receiving medical care at a neighborhood clinic. A pulsating

mass was palpated in the upper abdomen in July 1981 and diagnosed as abdominal aneurysm. Obstructive jaundice appeared in February 1982.

◦ Present status: Examination on 7 April 1982 showed generalized jaundice, blood pressure of 160~110 mmHg, and a pulsating tumor with bruit(+), 13×14cm in size, in the epigastrium.

### LABORATORY FINDINGS

#### a) Blood chemistry

Examination on 19 February 1982 showed obstructive jaundice with the findings of total bilirubin 11.3, GOT 78, GPT 74, and alkaline phosphatase 30.8.

#### b) Tc-HIDA (Fig. 1)

The liver presented pictures of compression in the lower region of the right lobe and in the left lobe, and excretion of bile was observed to be markedly delayed, it occurring after two hours into the intrahepatic bile duct, after three hours into the common bile duct, after five hours into the gall bladder, and after seven hours into the intestinal canal.

<sup>\*</sup> 土肥雪彦, 福田康彦, 中川健二, 竹中正治, 八幡 浩, 小野栄治, 江崎治夫, 中西敏夫, 藤原 卓, 田部康次: 閉塞性黄疸をきたした腹部大動脈瘤の一例

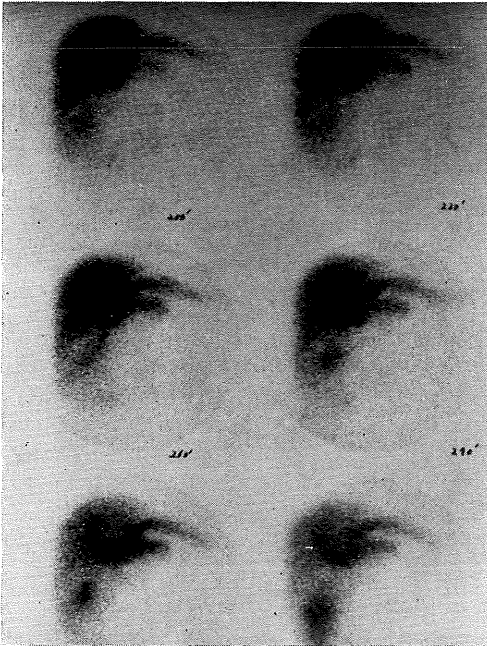


Fig. 1. Tc-HIDA

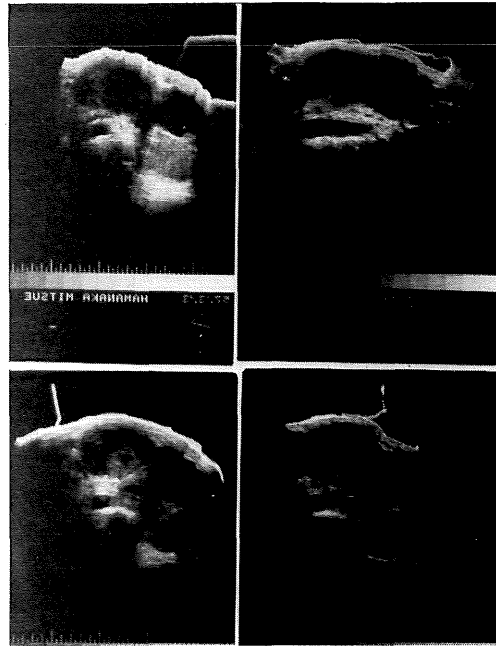


Fig. 3. Echogram

c) Liver scintigram (Fig. 2)

A picture of compression from the porta hepatis toward the lowermost region of the right lobe was depicted, which was considered to be compression by the region of thrombus formation in the aneurysm and by the dilated gall bladder.

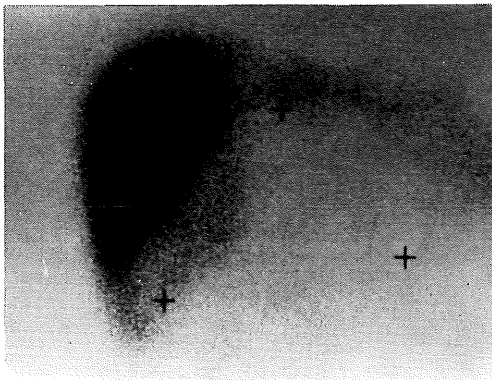


Fig. 2. Liver scintigram

e) R. I. angiography (Fig. 4)

No aneurysm was present in the thoracic aorta. A saccular abdominal aneurysm was found to compress the region of the porta hepatis.

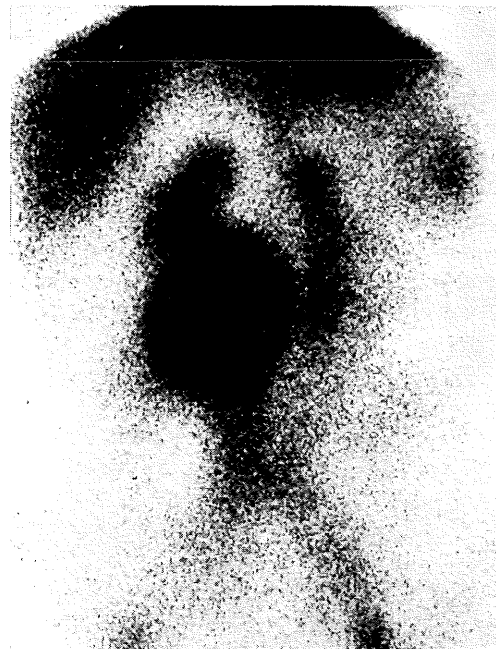

Fig. 4. R. I. angiography

d) Echogram (Fig. 3)

The gall bladder was swollen in the manner of Courvoisier's sign, and malignancy could not be ruled out. A huge abdominal aneurysm was found with thrombus formation in the lumen.

f) C. T. (Fig. 5)

The aneurysm, which had developed below

the bifurcation of the renal artery, protruded remarkably forward and upward, and compressed and displaced the common bile duct, portal vein, pancreas, and hepatic artery. Because the common bile duct was compressed by the aneurysm, the pancreatic duct, intrahepatic bile duct, and gall bladder were full and tautly stretched. The duodenum was also compressed and displaced to the right side by the aneurysm.

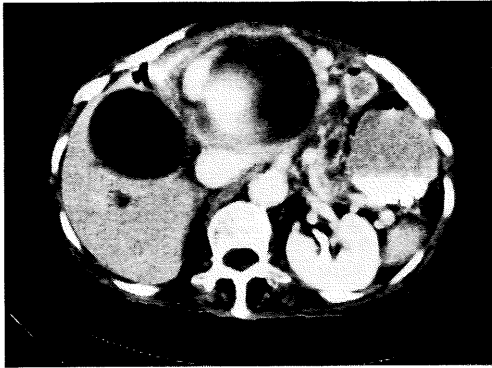


Fig. 5. C. T.

g) Angiography (Fig. 6, 7, 8)

The abdominal aorta showed stenosis from the region of L<sub>2</sub>, and due to this, the angiogram peripheral to the stenosis was poor and the relative positions of the aneurysm and the right and the left renal arteries could not be

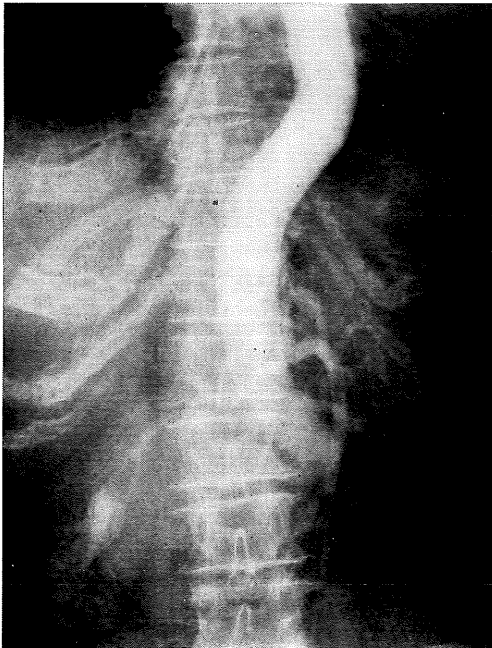


Fig. 6. Angiography

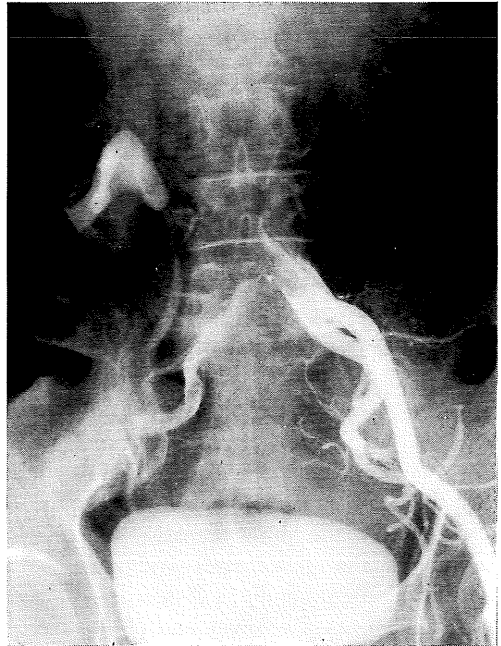


Fig. 7. Angiography

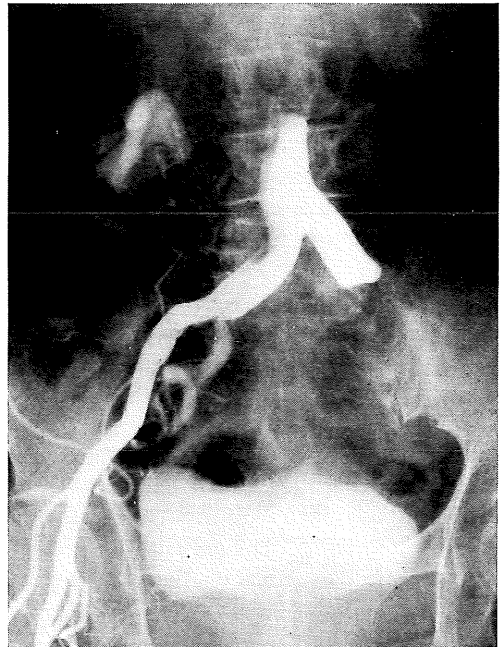


Fig. 8. Angiography

determined. The aneurysm was of the saccular type and extended from Th<sub>12</sub> to L<sub>5</sub>, and dissection to the bifurcation of the internal iliac artery was found bilaterally in the peripheral wall of the aneurysm.

Based on the above-described laboratory findings, the case was diagnosed as obstructive

jaundice resulting from compression of the region of the porta hepatis by an abdominal aneurysm developing from the abdominal aorta below the renal artery.

### OPERATION

On 26 April, emergency operation was performed because the patient had hematemesis and bloody discharge and, as the aneurysm tended to rapidly increase in size, the risk of rupture was very great.

As findings during the operation, the aneurysm was of the saccular type and had developed from the abdominal aorta 4 cm peripherally from the bifurcation of the left renal artery. The aneurysm was of the size of an infant's head, the head side of which directly compressed the region of the porta hepatis, and marked dilatation of the choledochus and gall bladder was found. Peripherally, a dissecting aneurysm had formed from the lower end of the sac.

As cause of hematemesis and bloody discharge, the duodenum, compressed by the aneurysm, had become almost completely necrotic and bleeding was suspected to have occurred from that site. The aneurysm was not excised. Incision was made in the aneurysm and a Y-shaped Dacron grafe was implanted by intrasaccular anastomosis method.

The postoperative course was satisfactory.

### DISCUSSION

For definite diagnosis of abdominal aorta aneurysm and decision of the indication of operation, angiography by the Seldinger method or the Dos Santos method has been employed heretofore at some risk<sup>2,7</sup>.

Recently, however, examinations have come to be made by generally safe, easy and noninvasive methods, such as ultrasound, R. I. angiography, C. T., etc<sup>1</sup>. The present case presented on biochemical examination the pattern of obstructive jaundice comprising mainly a huge pulsating mass in the epigastrium, and abdominal aneurysm complicated with tumor of the hepatobiliary duct was tentatively suspected. However, complication of tumor was ruled out by the aforementioned noninvasive examinations. In cases of abdominal aneurysm such as the present case, angiography by the Dos Santos method is very dangerous; information concerning the morphology of the aneurysm,

the site occupied, etc. should first be collected by the aforementioned noninvasive examinations.

According to Krestein<sup>6</sup>, abdominal aneurysm usually develops from the abdominal aorta below the left renal artery and presents through symptoms, namely, the symptoms of rupture, embolism and compression.

According to the reports of various investigators, the compression symptoms of abdominal aorta aneurysm are: (1) lumbar pain radiating to the lower extremities due to compression of the spinal and lumbar nerve root, (2) edema in the lower extremities due to compression of the iliac vein, (3) hydronephrosis due to compression of the ureter, (4) varicocele and hydrocele due to compression of the spermatic cord artery and vein, and (5) nausea and vomiting due to compression of the third part of the duodenum toward Traiz ligament<sup>8-6</sup>. However, no report has been made so far of obstructive jaundice developing as a result of direct compression of the region of the porta hepatis by an abdominal aneurysm which developed below the renal artery as in the present case. Ours is the first report.

The present case, which showed rapid enlargement of the aneurysm while waiting for the operation and developed hematemesis and bloody discharge due to compression of the duodenum, whose duodenal wall had become almost completely necrotic, was given an emergency operation just before rupture of the aneurysm occurred.

The operative procedure we followed was, as in the procedures reported by various investigators<sup>6</sup>, to retain the aneurysmal wall without detachment and excision, remove the thrombus inside and in its place implant a Y-shaped Dacron graft and then lap the aneurysmal wall around the artificial blood vessel to reinforce it.

An experienced case of abdominal aneurysm which presented the very rare symptom of obstructive jaundice has been reported.

### REFERENCES

1. Bernstein, E. F., Harris, R. D. and Leopold, G. R. 1982. Echography and computed tomography in the diagnosis and evaluation of abdominal aortic aneurysms. p. 31-44. Veith, F. G., Critical problems in vascular surgery. ACC, New York.

2. **Brewster, D., Rettana, A., Waltman, A. and Darling, C.** 1975. Angiography and the management of aneurysms of the abdominal aorta. *N. Eng. J. Med* 292 : 833-825.
3. **Culp, O. S. and Bernatz, P. E.** 1961. Urologic aspects of lesions in the abdominal aorta. *J. Urol.* 86 : 189-195.
4. **Darling, R. C.** 1970. Rupture of arterioscleotic abdominal aneurysms. A pathologic and clinical study. *Am. J. Surg.* 119 : 397-341.
5. **Gliedman, M. L., Ayers, W. B. and Vestal, B. L.** 1957. Aneurysmas of the abdominal aorta and its branches. A study of untreated patients. *Ann. Surg.* 146 : 207-214.
6. **Kerstein, M. and Sweeney, T. F.** 1981. Abdominal aortic aneurysms. P. 139-190. Campbell, C. D. *Aortic aneurysms*, Futura, New York.
7. **Kwann, J., Connolly, J., Vandermolen, R. and Conroy, R.** 1977. Value of arteriography before abdominal aortic aneurysmectomy. *Am. J. Surg.* 134 : 108-114.
8. **Sondheimer, J. L. and Steinbergs, I.** 1964. Gastrointestinal manifestations of abdominal aortic aneurysms. *Am. J. Roent.* 92 : 1110-1122.