

Surgical Treatment for Periapullary Carcinoma : A Study of 129 Patients^{*)}

Tsuneo TANAKA, Motomu KODAMA, Rokuro SEIKOH,
Hitoshi TAKEUCHI, Nobuaki ITOH, Osamu KODAMA
and Haruo EZAKI

*The Second Department of Surgery, Hiroshima University School of Medicine, 1-2-3,
Kasumi, Minami-ku, Hiroshima 734, Japan*

(Received March 21, 1984)

Key words: Periapullary carcinoma

ABSTRACT

The results of operations on 129 cases of periampullary carcinoma performed in our department during the period from January 1969 to June 1983 were studied.

The rates of resection in ampullary carcinoma and inferior bile duct carcinoma were high, while the rate in pancreas head carcinoma was low. The operative mortality in resected cases was as low as 4.3%. The number of longer survival for over five years was 1 case of inferior bile duct carcinoma (33.3%) and 6 cases of ampullary carcinoma (60.0%), all showing no serosal infiltration and non-presence of metastasis to lymphnodes. The five-year survival case of pancreas head carcinoma was only 1 (10.0%) which was found by chance, and its prognosis was poor.

The curative resectability of pancreaticoduodenectomy for ampullary carcinoma and inferior bile duct carcinoma was recognized, but the resectability of pancreaticoduodenectomy for pancreas head carcinoma was low. This is our problem to solve in future.

INTRODUCTION

In 1935 Whipple et al.¹⁰⁾ succeeded in performing pancreaticoduodenectomy (PD) on periampullary carcinoma for the first time. Thereafter, PD has been established as the standard surgical formula for periampullary carcinoma, but the mortality directly due to operations was high, and the late results were very pessimistic. In the present study, the authors examined the late results after operations on periampullary carcinoma performed in our department, especially those after resections.

MATERIALS AND METHODS

The number of operations on the carcinomas of the bile duct and pancreas conducted in our department during the period from January 1969 to June 1983 was 216. These cases were classified retrospectively for the study on the basis of the General Rules for Surgical Studies

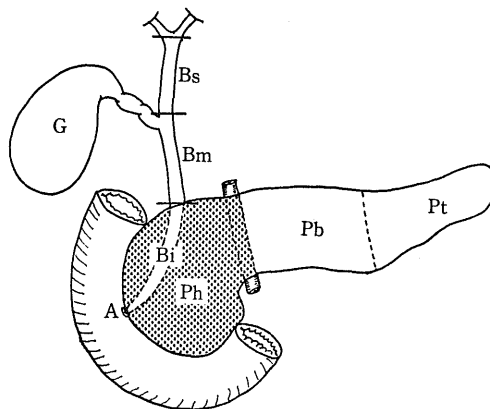


Fig. 1. Classification of the biliary tract and the pancreas by General rules for surgical studies on cancer of biliary tract and pancreas. G: Gall bladder, Bs: Superior bile-duct, Bm: Middle bile-duct, Bi: Inferior bile-duct, A: Ampulla of Vater, Ph: Pancreas head, Pb: Pancreas body, Pt: Pancreas tail.

^{*)} 田中恒夫, 児玉 求, 清光六郎, 竹内仁志, 伊藤信昭, 児玉 治, 江崎治夫: 膵頭部領域癌129例の外科的治療成績

on Cancer of Biliary Tract⁶⁾ and Pancreas⁷⁾ (Fig. 1). According to the classification, our cases of periampullary carcinoma could be subdivided into 13 cases of the carcinoma of the inferior bile duct (intrapancreatic bile duct, Bi), 26 cases of the carcinoma of the ampulla of Vater (A), and 90 cases of the carcinoma of the head of the pancreas (Ph), 129 cases in total. As of June 1983, the followup study was started in order to obtain the remote results classified by the lesion of tumors.

Surgical technique of PD:

The head of the pancreas was cut at the left margin of the superior mesenteric vein. The stomach was resected within a small range, but truncal vagotomy was added. The biliary tract was cut at the common hepatic duct and cholecystectomy was done. The jejunum was cut on the anal side about 20 cm from the Treitz ligament. The lymph nodes around the celiac axis, common hepatic artery, left gastric artery, superior mesenteric artery, hepatoduode-

nal ligament and retropancreas, were cleared out. The method for the reconstruction of the digestive tract was to pull up the jejunum to the posterior of the colon, and pancreatojejunostomy, choledochojejunostomy, gastrojejunostomy and jejunojejunostomy, was made in this order.

RESULTS

The resected cases included 43 of PD and 3 of papillectomy for ampullary carcinoma, 46 cases in total. As shown in Table 1, the rate of resections classified by the lesion, and the rate of curative operation, were high in ampullary carcinoma and inferior bile duct carcinoma, whereas they were low in pancreas head carcinoma.

As shown in Table 2, on the other hand, the operative mortality was 4.3% in resected cases, while it was 7.2% in non-resected cases. It was 6.2% in both cases put together.

The rates of survival for one year, three

Table 1. The rate of resection and curative operation in patients with periampullary carcinoma

Portion	No. of operation	No. of resection	No. of curative operation
Intrapancreatic bile duct	13	10(76.9%)	7(53.8%)
Ampulla	26	21(80.8%)	16(61.5%)
Pancreas head	90	15(16.7%)	7(7.8%)
Total	129	46(35.7%)	30(23.3%)

Table 2. The operative mortality in patients with periampullary carcinoma

Portion	Operative Mortality		
	Resectable case	Unresectable case	Total case
Intrapancreatic bile duct	1/10(10.0%)	0/3(0%)	1/13(7.7%)
Ampulla	0/21(0%)	0/5(0%)	0/26(0%)
Pancreas head	1/15(6.7%)	6/75(8.0%)	7/90(7.8%)
Total	2/46(4.3%)	6/83(7.2%)	8/129(6.2%)

Table 3. Survival rate in patients with periampullary carcinoma who received operation

Portion	1-year survivors	3-year survivors	5-year survivors
Intrapancreatic bile duct	6/10(60.0%)	3/8 (37.5%)	1/3 (33.3%)
Ampulla	16/19(84.2%)	10/15(66.7%)	6/10(60.0%)
Pancreas head	7/15(46.7%)	1/11(9.1%)	1/10(10.0%)
Total	29/44(65.9%)	14/34(41.2%)	8/23(34.8%)

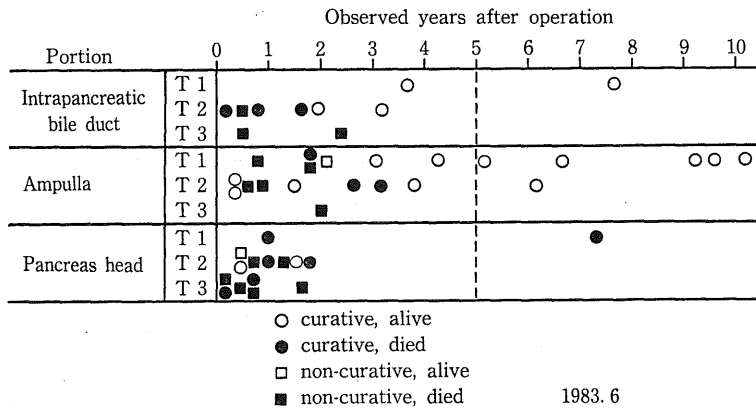


Fig. 2. Relation between Tumor factor and prognosis, in patients with periampullary carcinoma who were resected.

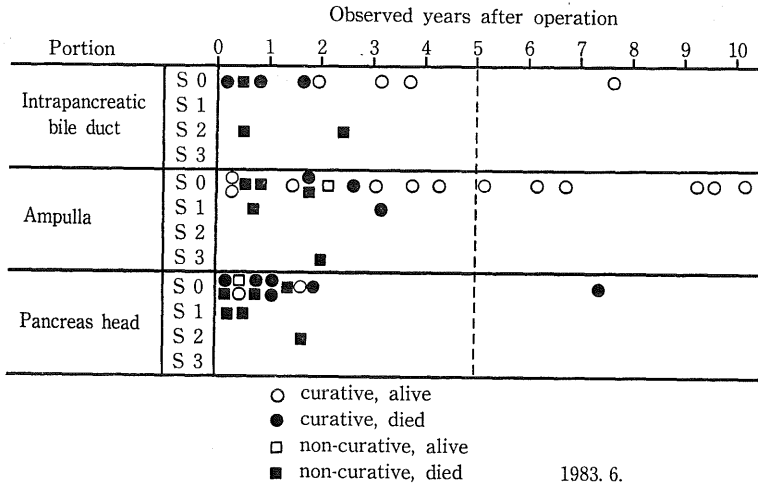


Fig. 3. Relation between Serosal factor and prognosis, in patients with periampullary carcinoma who were resected.

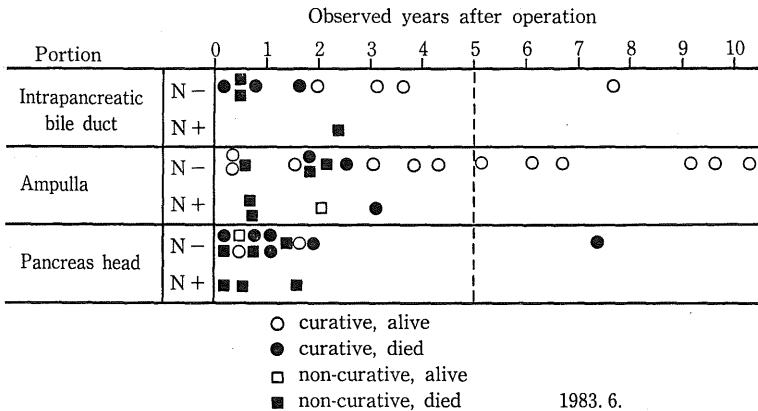


Fig. 4. Relation between Lymph Node factor and prognosis, in patients with periampullary carcinoma who were resected.

years and five years classified by the lesion of tumors are shown in Table 3. The number of longer survival for over five years was 8, including 1 of inferior bile duct carcinoma, 6 of ampullary carcinoma and 1 of pancreas head carcinoma. The survival rates were better in the order of ampullary and inferior bile duct carcinoma, and inferior in pancreas head carcinoma.

The relationship between the diameter of the tumor (T), serosal infiltration (S), presence or non-presence of metastasis to lymph nodes (N) vs. prognosis was studied with 46 resected cases (Fig. 2-Fig. 4).

DISCUSSION

In recent years, the progress of diagnostic techniques by angiography, endoscopic retrograde cholangio-pancreatography (ERCP) ultrasonography and computed tomography (CT), has promoted the early diagnosis for periampullary carcinoma, so that the number of resected cases, especially that of curative operations, has been increasing. In carcinoma of ampulla of Vater, the rate of curative resections has risen to about 60%. The success may be attributable to the fact that ampullary carcinoma is liable to cause jaundice at an early stage, and that the diagnosis is easy to give. It is regrettable, however, that the early discovery of the carcinoma of the pancreas is difficult, and the rate of its resection is as low as below 20%. The majority of the cases are progressive.

The safety of operations has been markedly improved recently, thanks to the better preoperative and postoperative management of the cases by hyperalimentation, or percutaneous transhepatic cholangio-drainage (PTCD), as well as by improved surgical techniques. The authors found that the operative mortality in our department was higher in non-resected cases, rather than in resected cases. This may be due to the facts that almost all non-resected cases were progressive, including many of poor surgical risks, and that resected cases included many of those where jaundice was reduced by PTCD. At any rate, the operative mortality in all our cases was only 6.2%, a satisfactory outcome.

The prognosis of periampullary carcinoma differed largely by the lesions of tumors, and the question of resectability must be considered

separately. In the present study, three factors of tumor diameter (T), serosal infiltration (S) and the presence or non-presence of metastasis to lymph nodes (N), were examined. In all 6 cases of ampullary carcinoma survived for long years, no serosal infiltration (S0) and no metastasis to lymph nodes (N0) were observed, and the prognosis of the cases of curative resection was satisfactory. On the other hand, the prognosis of the cases where metastasis to lymph nodes (N+) was better than that of the non-resection cases, but so far no cases of longer survival have been noted. Examination of literature on the therapeutic results of PD for ampullary carcinoma revealed that the rate of five-year survival reported by Warren et al.⁹⁾ was 32%, by Akwari et al.¹⁾ 34%, and by Forrest et al.⁴⁾ 24%. These results were as good as ours. Consequently, the curative resectability of PD for ampullary carcinoma can be fully recognized. Coopermann⁸⁾ reported on ampullary carcinoma as follows: "These lesions are favorable because they tend to be papillary and exophytic, and cause jaundice early."

In inferior bile duct carcinoma, as in ampullary carcinoma, there is no serosal infiltration (S0), nor is there metastasis to lymph nodes (N0), and the prognosis is good. However, since the number of resected cases is still small, detailed examination cannot be made yet. It is considered, however, that it can be regarded similarly as in the case of ampullary carcinoma.

In pancreas head carcinoma, only 1 case of longer survival for over five years was found by chance, but the prognosis of all other cases was very poor. It is not the time at present to examine these cases by classifying them by the factor. The reports from other institutes^{2, 5, 9)} are as miserable as ours, and the number of the case surviving for more than five years is extremely few. With PD, curative resectability can be recognized in some cases of early carcinomas, but currently improvements of therapeutic results with PD cannot be expected. Accordingly, extended PD or total pancreatectomy has been experimented positively for the carcinoma of the pancreas, but to no avail. Surgical therapy for the carcinoma of the pancreas is our task which belongs to the future.

As has been explained so far, many of the carcinomas of the pancreas are progressive and unresectable. Therefore, the authors⁸⁾ have

been experimenting a large-dose administration of a streptococcal preparation (OK-432) into the progressive pancreatic carcinoma from a long time since. Although the life-prolonging effect has not been found, a pain-removal effect has been noticed, and the therapy is considered effective.

REFERENCES

1. **Akwari, O. E., Heerden, J. A. and Adson, M. A.** 1977. Radical pancreatoduodenectomy for cancer of the papilla of Vater. *Arch. Surg.* 112 : 451-456.
2. **Child, C. G. 3rd. and Frey, C. F.** 1966. Pancreaticoduodenectomy, Surgical grand rounds—University of Michigan. *Surg. Clin. of North Am.* 46 : 1201-1213.
3. **Cooperman, A. M.** 1981. Cancer of the ampulla of Vater, bile duct, and duodenum. *Surg. Clin. of North Am.* 61 : 99-106.
4. **Forrest, J. F. and Longmire, W. P.** 1979. Carcinoma of the pancreas and periampullary region, a study of 279 patients. *Ann. Surg.* 189 : 129-137.
5. **Hermrek, A. S., Thomas, C. Y. IV. and Friesen, S. R.** 1974. Importance of pathologic staging in the surgical management of adenocarcinoma of the exocrine pancreas. *Am. J. Surg.* 127 : 653-657.
6. **Japanese Biliary Surgical Society.** 1981. General rules for surgical studies on cancer of biliary tract. Kanehara-shuppan, Tokyo.
7. **Japanese Pancreatic Society.** 1982. General rules for surgical and pathological studies on cancer of pancreas. Kanehara-shuppan, Tokyo.
8. **Kodama, M. and Tanaka, T.** 1983. Intratumoral administration of streptococcal preparation OK-432) to advanced pancreatic cancer. *Hiroshima J. Med. Sci.* 32 : 167-171.
9. **Warren, K. W., Choe, D. S., Plaza, J. and Relihan, M.** 1975. Results of radical resection for periampullary cancer. *Ann. Surg.* 181 : 534-540.
10. **Whipple, A. O., Parsons W. W. and Mullins, C. R.** 1935. Treatment of carcinoma of the ampulla of Vater. *Ann. Surg.* 102 : 763-779.