

Recent Knowledge on the Cleft Hand: it's Pathologic Pattern and Scope^{*)}

Shoichi WATARI, Yoshitaka HAGIYAMA and Kenya TSUGE

Department of Orthopedic Surgery, Hiroshima University School of Medicine, 1-2-3, Kasumi, Minami-ku, Hiroshima 734, Japan

(Received December 24, 1983)

Key words: Cleft hand complex, Central polydactyly, Digital ray fusion

ABSTRACT

Cleft hand is an anomaly in which the primary feature is oligodactyly, and it is considered an important congenital malformation. The authors have analyzed the cases they have handled and developed an independent classification based on the number of defective digits. It has been ascertained that the clinical symptoms correlate with the number of defective digits, and a regular pattern was observed. Study of cases considered to be in the main stream led us to feel that polydactyly of the middle finger is the developmental mechanism for this entity. That is, we feel that the polydactylous partner on the radial side is transpositioned to the index finger while the same on the ulnar side is transferred to the ring finger, which is followed by fusion of the respective rays resulting in the loss of the middle finger.

Generally when referring to the central fingers, it often the case that reference is being made to the index, middle and ring fingers. The kind of morphological anomalies that develop when cleft hand changes similar to the those of the middle finger occur in the index or ring finger are shown by schematic diagrams. As a result, in the case of index finger involvement, in addition to cleft hand of the index finger, there is development of Wassel VII type polydactyly of the thumb and single type triphalangeal thumb can be considered, while in the case of the ring finger, the occurrence of polydactyly of the little finger in addition to cleft hand of the ring finger can be considered.

Pursuit of such changes in the clinical cases from the standpoint of morphology or symptoms, indicates that many cases which had been difficult to diagnose in the past had findings which agreed with the above, which served to confirm the presence of such a developmental course.

That is, cleft hand is not a diagnosis to be assigned to a fixed morphological condition, but indicates a set scope, and from the standpoint of site it involves not only the middle finger, but it is obvious it can develop in any of the other central fingers as well. However, attention should be paid to the fact that the cleft hand changes which develop in the index and ring fingers present an entirely different morphology from that of the concept entertained in the past.

The above developmental mechanism is an anomaly in the distribution of digital rays which occurs to the formation of polydactyly within the hand plate, considered to be based upon this anomaly. It is presumed to be a typical congenital anomaly which occurs during the hand plate formation stage.

INTRODUCTION

There are many congenital anomalies and

diseases caused by such in the field of orthopedic surgery, and while they are important, when it comes to treatment difficulty is en-

^{*)} 渡 捷一, 萩山吉孝, 津下健哉: 裂手症に関する最近の知見——特に病態と抱括範囲について——

countered in many. Particularly, the ratio of congenital anomalies in the field of surgery of the hand is high. As research on reconstruction of functional defects due to trauma has reached a plateau interest has suddenly been focussed upon congenital anomalies. Of course, one of the great turning points which can not be forgotten is the development of congenital defects of the hand induced by thalidomide during the period 1958 to 1962. Subsequently, basic study field such as experimental teratology have made great strides to present.

On the other hand, it cannot be denied that there was a delay in research in the clinical area which should go hand-in-hand with basic studies. Despite the call for need of undertaking systematic review, there are yet only a few hand surgeons engaged in such studies on an individual basis. However, in comparison with the earlier days when there was not even a set interpretation of terms for diagnosis and descriptions of the pathological state, it can be said great progress has been achieved, but at present the stage is yet limited to efforts to ascertain the pathological state of each anomaly, and has yet to reach the stage of establishing definitions and discussing developmental mechanisms. However, earnest clinical research being carried out by these limited number of scientists have introduced much new knowledge through which the total picture of congenital anomalies of the hand are being elucidated.

During the course of such clinical research, the key to elucidation of the pathologic description was obtained by observation of clinical picture of cleft hand.

Cleft hand is a congenital anomaly named by Kümmel²⁾ back in 1895. Not only has a definition yet to be established, but not even has the pathologic description been fully ascertained. This is due to the diversity of the morphological pattern, but during recent years a number of phenomena considered to provide clues to the elucidation of the pathologic state have been discovered by hand surgeons in Japan, which have created breakthroughs for the elucidation of all congenital anomalies. That is, beginning with pursuit of the relationship of cleft hand and such findings as polydactyly and syndactyly often observed together with the it, has led to extremely interesting reports^{5,9)} on the analogy in developmental mechanism of

cleft hand, its scope and correlation with other abnormal entities.

In our department we have experienced cases of cleft hand and through pathological analysis, we have been able to formulate our own opinion on the above mentioned points. As our findings are not limited to cleft hand alone, but also serve to elucidate the true state of congenital anomalies of the hand, we felt it of value to report the results in detail.

CLASSIFICATION OF CLEFT HAND

The classification of cleft hand with the longest history and most widely known is that of Barsky¹⁾, in which he divides it into typical and atypical types, which has been the line of thinking since Lange⁴⁾. However, recent study has demonstrated that it is beyond doubt that the atypical type is the advanced form of synbrachydactyly, and thus the classification of cleft hand implies only the typical type, defeating the need for a separate category. Subsequently, attempt have been made to classify this entity on the basis of its external appearance and surgical findings, but there was a lack of general acceptability and it failed to be widely adopted.

Thus, the authors attempted to establish a classification using number of defective finger rays as the index which is the greatest characteristic feature of this entity⁹⁾, but as will be described later, this is linked to the elucidation of its developmental mechanism.

The defect of mildest degree in cleft hand is middle finger ray defect, which we termed single ray defect. This type can be subclassified largely into the distal type in which the defect begins at the proximal phalanx and the metacarpus is intact, and the proximal type where there is total absence of the middle finger ray. In the distal type a further subclass is the balanced form in which external appearance shows the index and ring fingers are in balance, and imbalanced form where there is marked hypertrophy of either the index or ring finger (more often the ring finger).

The external appearance of the balanced and imbalanced types shows that they are not independent, but are relative to one another. That is, even in the balanced type many have a slight degree of hypertrophy in the ring finger ray, and when comparison of the left and right

hands are made in bilaterally affected cases, it is obvious that there is continuity between the balanced and imbalanced types. However, in the typical imbalanced type, the X-rays show images which appear to suggest direct fusion of finger rays of the middle and ring or index and middle. Also central cleft which is the characteristic feature of this entity is not always present, in cases with good development of the third metacarpus, the central cleft is not deep, but presents a wide interdigital space of normal height. However, when development of the third metacarpus is poor and deviates towards the second or fourth metacarpus, the deep central cleft characteristic of cleft hands is presented. Further, in the case of single ray proximal defect type, all cases present a balanced appearance and have deep central cleft.

Two ray defect type consists of involvement of the middle finger ray plus a defect of one other finger ray, either the index or ring finger ray. The hand divided into the radial com-

ponent and ulnar component by a deep central cleft, and some hands have two fingers on the radial side while some have two on the ulnar side.

In the three finger ray defect type, two rays are left, one on the radial side and the other on the ulnar side, and if there is a defect of one more ray, we have the four finger ray defect type. Only one case of the latter has been experienced by us. In this case, both hands were involved, the contralateral hand had a three finger ray defect. This state closely resembled transverse developmental arrest, and it is considered it was at the transient point of this entity and transverse developmental arrest.

When the above classification was applied to the cases seen by us the most numerous was the 60 hands with single ray distal type defect followed by single ray proximal type defect with 30, 15 with two ray defect, 10 with three ray defect and 1 with four ray defect. This indicates that the more advanced the symptoms,

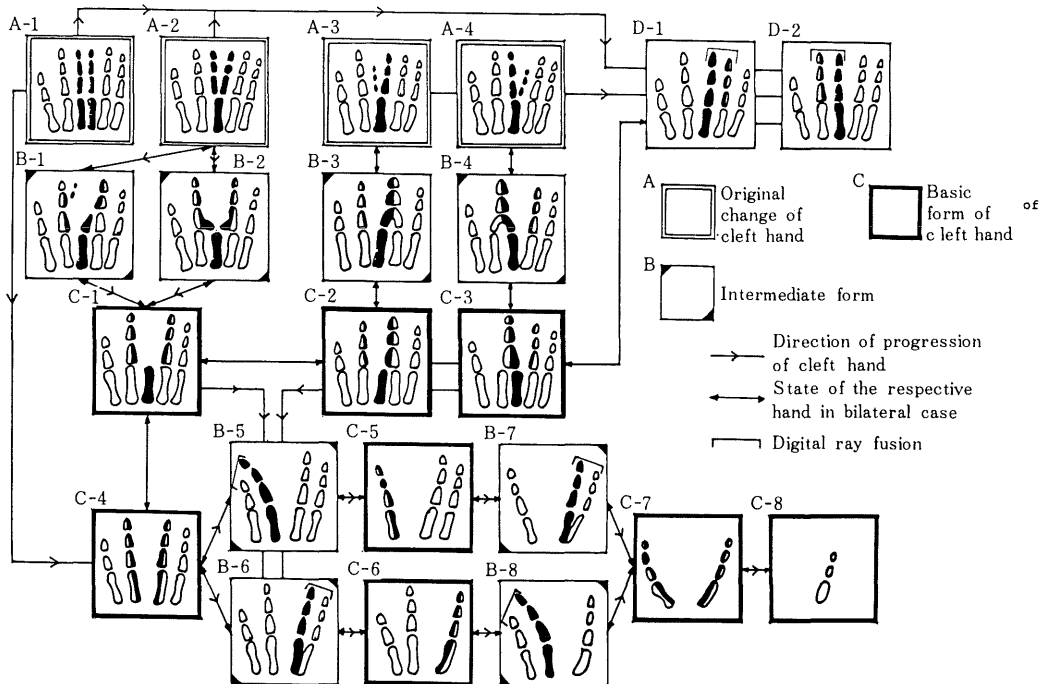


Fig. 1. Schematic diagram of cleft hand

The A-row shows the original changes of cleft, hand. The B-row shows the intermediate form and the C-row indicates the basic form. The D-row shows syndactyly in combination with cleft hand. The direction of progression of symptoms and the state of the respective hands in bilateral cleft hands are shown by arrows.

The changes shown in this schematic diagram are all cleft hand, and from this it can be well understood that cleft hand is not a name for a specific deformity but represent a flow of certain symptoms,

the lower is the frequency of the defect. This tendency shows that from the standpoint of symptoms, the single ray defect is the origin for the development of cleft hand.

These cases of cleft hand are the basic types of this anomaly which are shown in Fig. 1 in skematic drawings as C-1 (single ray defect, balanced type), C-2 (single ray distal defect, imbalanced, ring finger type), C-3 (single ray distal defect, imbalanced, index finger type), C-4 (single ray proximal defect type), C-5, C-6 (two ray defect type), C-7 (three ray defect type), and C-8 (four defect type).

DEVELOPMENTAL MECHANISM OF CLEFT HAND

The mildest form of defect is single ray distal defect type cleft hand, and when both hands are involved, in many instances both are cleft hand, but although small in number there are instances where the morphology of the contralateral hand is completely different. The most

well-known is that shown in Fig. 2 and Fig. 3 where there is a mixture of polydactyly and syndactyly in the contralateral hand. The X-ray image of the right hand in Fig. 2 shows partial defect of the middle finger which at the same time becomes fused with the ring finger, while polydactylous partner can be seen on the ulnar side of the index finger. Fig. 3 shows the external appearance of a similar case. The middle and ring fingers of the left hand form a tight fusion while there is polydactyly on the ulnar aspect of the index finger. Such cases are not numerous but they have been reported from long ago⁹⁾. However, it was only recently that the implication of such morphology was elucidated. That is, this phenomena is polydactyly of the middle finger⁹⁾ with the radial partner being transposed to the index finger, while the ulnar partner is transposed to the ring finger. Upon completion of the transposition, there will be no middle finger and thus a single ray distal defect type cleft hand will



Fig. 2. Remnant of polydactyly of middle finger seen in contralateral hand of case with single ray distal defect type cleft hand.

The left hand has single ray distal defect type cleft hand while the right hand has coexistence of polydactyly and syndactyly. In cases such as this in whom there is polydactyly in the middle finger, the radial partner is transposed to the index and the ulnar partner to the ring finger, which is considered the developmental mechanism of the cleft hand.

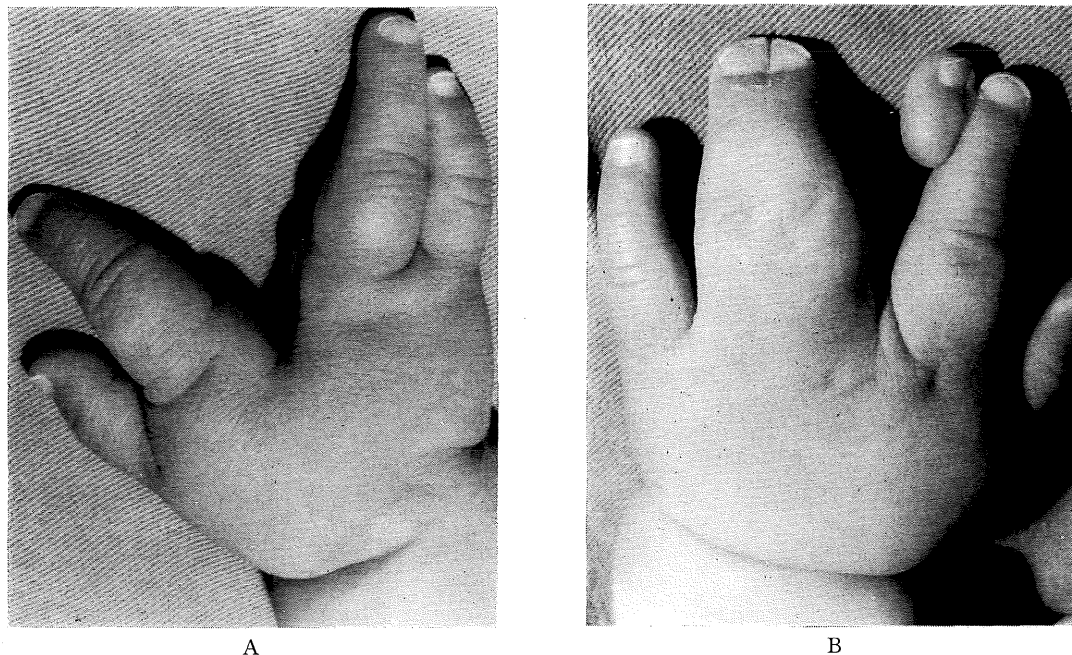


Fig. 3. Remnant of polydactyly of the middle finger as observed in the contralateral side of single ray distal defect type cleft hand. (External findings)

This is the external findings of a case similar to that of Fig. 2. The right hand is a single ray distal defect type cleft hand while there is coexistence of polydactyly in the left. That is, the middle and ring fingers form tight syndactyly, while a polydactylous partner can be seen on the ulnar side of the index finger. This is a typical case with remnant of polydactyly of the middle finger.

have developed. The authors have confirmed this phenomenon by animal experiments⁹. In retrospection one is made to realize that although the number of cases with this primitive type of middle finger polydactyly is few, cases with two cross bones oriented towards the radial and ulnar sides from the third metacarpus are not rare. Such cross bones are the remnants of the polydactylous component of the middle finger. These two cross bones clearly indicate the presence of the middle finger polydactyly phenomenon. In view of this, the conventional observation that cross bones are typical findings of cleft hand can be said to be appropriate. (Fig. 4-A, B)

This process is illustrated in Fig. 1, going from the intermediate transitional forms of A-1, B-1, B-2 etc. to C-1.

The other form of single ray distal defect type is the imbalanced form. Such transitory types as shown in Fig. 5-A, B are frequently observed, and thus are strongly considered to develop as a result of syndactyly of the middle and ring fingers. This condition is still some-

times referred to as osseous syndactyly. However, authors cannot accept this for a number of reasons. First, is that the imbalanced type is associated with the balanced type from the transitory point of view and the frequency is even greater than that of the balanced type, thus it is an established form of cleft hand. Secondly, is the question of whether patterns such as shown in Fig. 5-A, B can be called syndactyly. Originally, syndactyly result from a suppression for some reason of the formation of an interdigital space, also even so-called osseous syndactyly in which fusion of part of the distal phalanx take place, is not a primary failure of separation of the digital rays, but is interpreted as being due to a re-fusion of once separated digital rays because of poor development of an interdigital space. Therefore, it is obvious that the above mentioned massive fusion of phalanges or total union are not syndactyly, but are what may be called digital ray fusions. In this case, it should be understood that the implication of fusion is not of an active nature such as bones being fused into contact

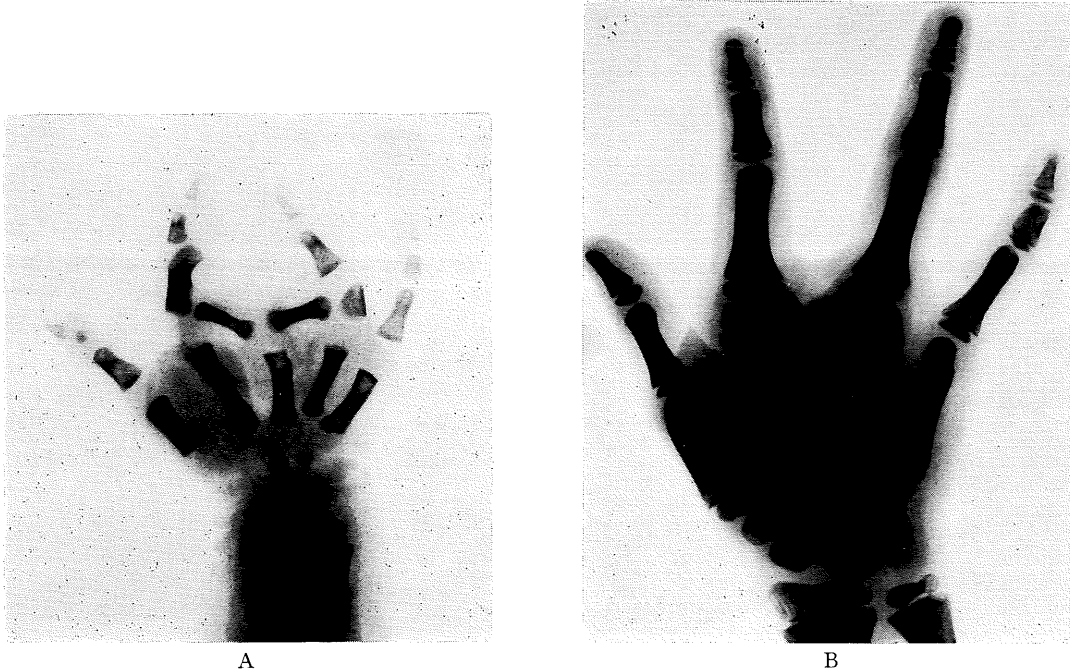


Fig. 4. Cross bone in cleft hand

Two cross bones oriented in the radial and ulnar directions from the third metacarpal are frequently observed in cleft hand, which are considered evidence of remnants of polydactyly of the middle finger.

A. Two cross bones which are of primordial type had maintained their shape of phalanges as can be seen.

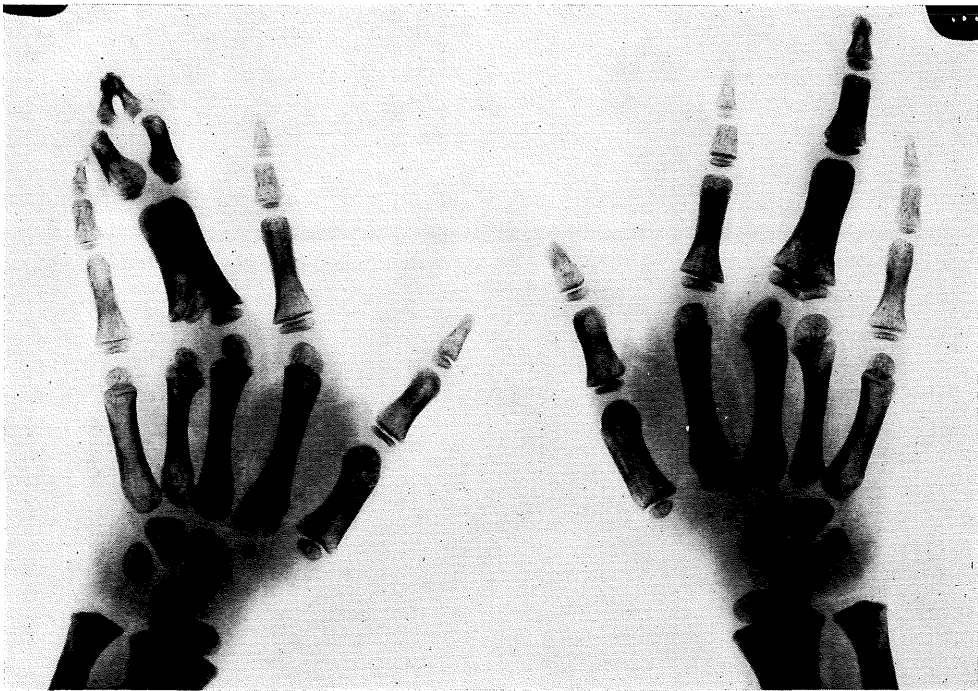
B. That on the radial side is a remnant bone, while that on the ulnar side has become part of the epiphysis of the proximal phalanx of the ring finger, and is thus a differential type.

with one another, but is of a passive one in which there is a primary failure of separation of the digital rays, and thus is rather an abnormality of the distribution of the mesenchymal cells. Thirdly, if it is assumed there is a different developmental mechanism for each the balanced and imbalanced types because there are some morphological differences, we could be subjected to criticism because this would be running contrary to the efforts towards generalization of theory.

Thus, analysis was made of the intermediate transitory type of the imbalanced form of single ray distal defect and the following interesting morphological points were noted. Fig. 6 and 7 show typical cases. The changes in the left hand of the patient in Fig. 6 indicate the primitive type of middle finger polydactyly. The ulnar partner of the polydactylous middle finger which has fused with ring finger is large and maintains its phalanx form whereas the radial partner which has transposed to the index finger

side is small and has become a differential type cross bone. However, there is no doubt that after these changes are completed, the imbalanced form of single ray distal defect will result, which indicate that the balance between the index and ring fingers in single ray distal defect type is determined by the size of the polydactylous partner of the finger rays that fused together. Fig. 7 shows a similar case where there is marked hypertrophy of the phalanges of the ring finger in which there was digital ray fusion of the ulnar partner in middle finger polydactyly, while the index finger in which there was no ray fusion the finger size was normal. These cases confirm the above described process.

In other words, the developmental mechanism of the imbalanced form of single ray distal defect is middle finger polydactyly and the size of the polydactylous partner clearly determines the balance between the index and middle finger. This process can be described schematically as



A



B

Fig. 5. Intermediate transitional type cleft hand seen in the contralateral hand of a single ray distal defect imbalanced type.

A. The right hand is of single ray distal defect imbalanced type, but the left hand appears to be syndactyly of the middle and ring fingers. Thus, this type of cleft hand has been considered to have been caused by syndactyly, and not only the left hand but even the right hand which has a hypertrophic finger ray called osseous syndactyly.

B. A similar case in whom bony fusion is more advanced.

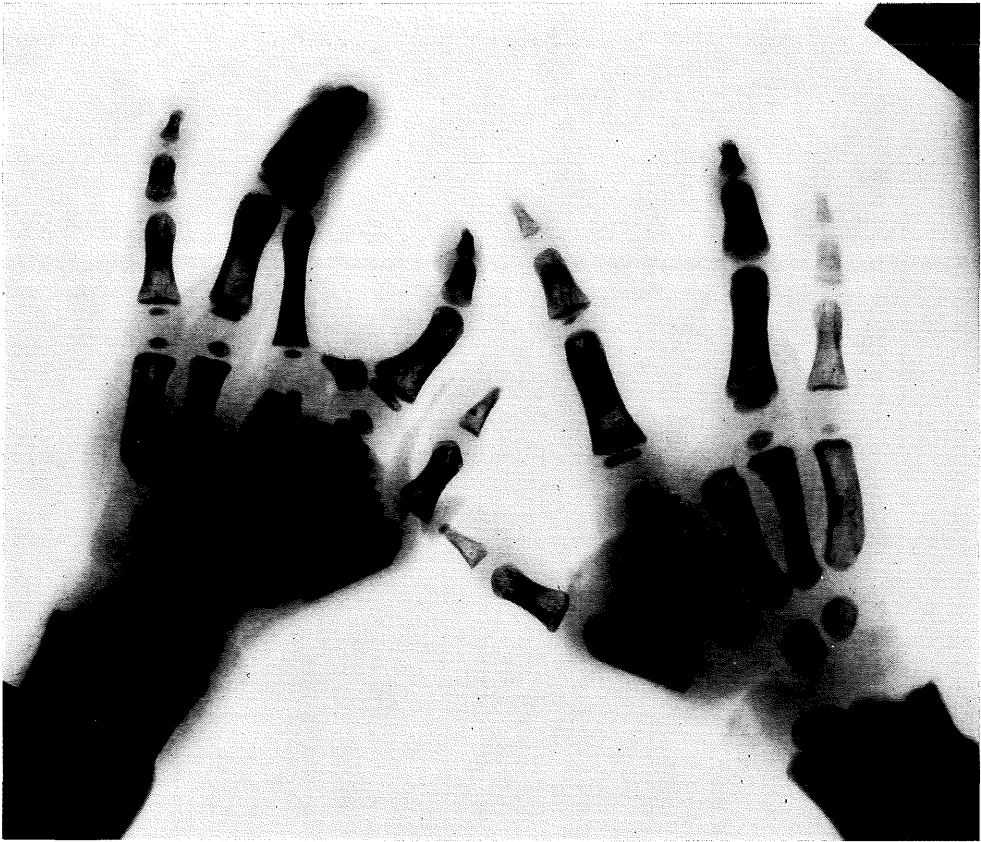


Fig. 6. Intermediate transitional type cleft hand which shows that the single ray distal defect imbalanced type also oriented from polydactyly of the middle finger.

Changes in the left hand are remnant of polydactyly of the middle finger which is of primordial type. However, the ray in the course of being transposed to the ring finger ray is a large polydactylous component in which the morphology has been preserved and a hypertrophic ray is being formulated. The bone being transposed to the index fingers, is a mere trace of a crossbone. Upon completion of the change, this case will be a definite single ray distal defect imbalanced type. In other words, hypertrophy of the phalanges is determined by the size of polydactylous component of the middle finger undergoing transposition.

shown in Fig. 1 whereby the intermediate transitory types of A-3, A-4, B-3 and B-4 progress to C-2 and C-3.

When the defect advance further and involves the third metacarpal, it is called single ray proximal defect type. What is the developmental mechanism for this? As the distal and proximal defect types are frequently observed in different hands of the same patient, the respective causes are proximal phalangeal type of middle finger polydactyly in distal defect type and metacarpal type in proximal defect type. As in the case shown in Fig. 8, the ring finger ray is composed of hypertrophic phalanges including metacarpal and there are definite sign

of ray fusion, but the index finger ray which shows no hypertrophy has a delta phalanx in the middle phalanx. The signs of fusion are findings which support the above mechanism. A schematic drawing that illustrate this process can be seen from A-1 to C-4 in Fig. 1.

More severely advanced cases of cleft hand than single ray proximal defect type can often be seen in those in whom both hands are affected. Fig. 9 shows such a case. The two radial or ulnar digits in single ray proximal defect type develop finger ray fusion, and thus the number of fingers is reduced. This process progresses from the intermediate transitory types of C-4 or C-2, C-3 to C-5, B-6 on to

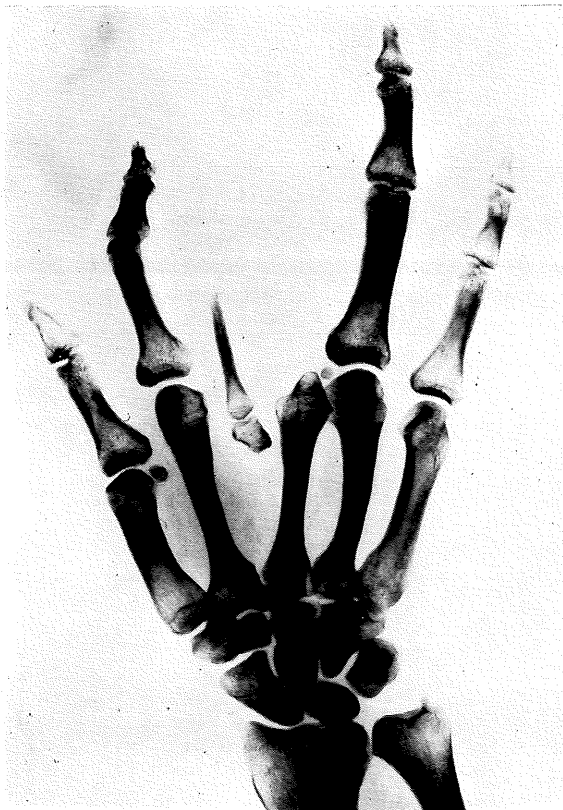

Fig. 7. An intermediate transitional type cleft hand which shows that the single ray distal defect imbalanced type also originated from polydactyly of the middle finger.

The ulnar component of the polydactylous middle finger has transposed to the ring finger and forms a hypertrophic finger ray, but the ulnar component remains as a cross bone. No hypertrophy can be seen in the index finger. This indicates that the degree of phalangeal hypertrophy in cleft hand is determined by the size of the polydactylous component that is transposed.

the two ray defect types of C-5, C-6 in Fig. 1. As shown in the figure, there are two types depending upon whether the two radial digit fuse first or the two ulnar digit fuse first. Attention is directed to the fact that when the state involving fusion of the two radial digit progresses from B-5 to C-5, it produce a triphalangeal thumb. This offers a suggestion as to the development of the triphalangeal thumb and also indicate that digital ray fusion is carried out additively concerning the number of phalanx.

The progression from two finger ray defect to three ray defect is achieved by fusion of the

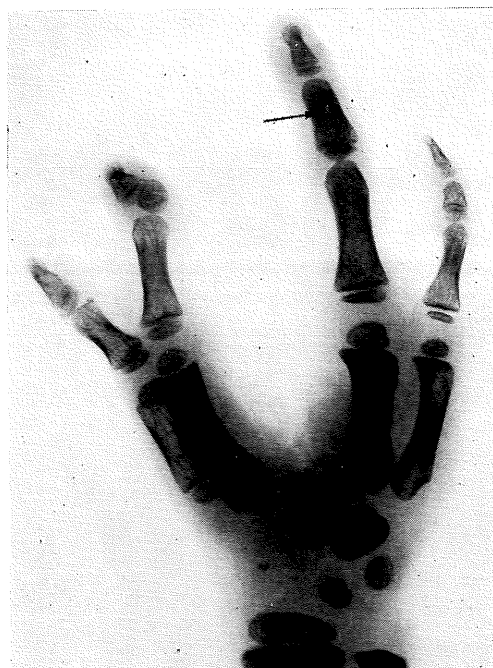

Fig. 8. A case with single ray proximal defect type cleft hand.

Hypertrophy of the fourth metacarpus is noted and there is marked hypertrophy of the ring finger ray and a small hole can be seen in the middle phalanx.

In the index finger ray, hypertrophy can be seen in the second metacarpus only, but the middle phalanx shows a definite delta phalanx. These, too, indicate the presence of digital ray fusion.

two remaining finger rays as in the case shown in Fig. 10. That is, the process goes from C-5, C-6 via B-7, B-8 to C-7. Thus the radial digit in three ray defect type often has three phalanges.

In the development of four finger ray defect, the above mechanism does not apply, and it is felt that earlier mentioned transverse developmental arrest mechanism plays a major role.

RELATIONSHIP WITH SYNDACTYLY

As described above, the development of cleft hand requires the presence of polydactyly in the middle finger and at the same time digital ray fusion caused by progression of abnormal distribution of the mesenchymal component. It has been explained that this ray fusion is different from the so-called syndactyly and syndactylous mechanism, but then if asked is it totally unrelated to the generally referred to syndac-

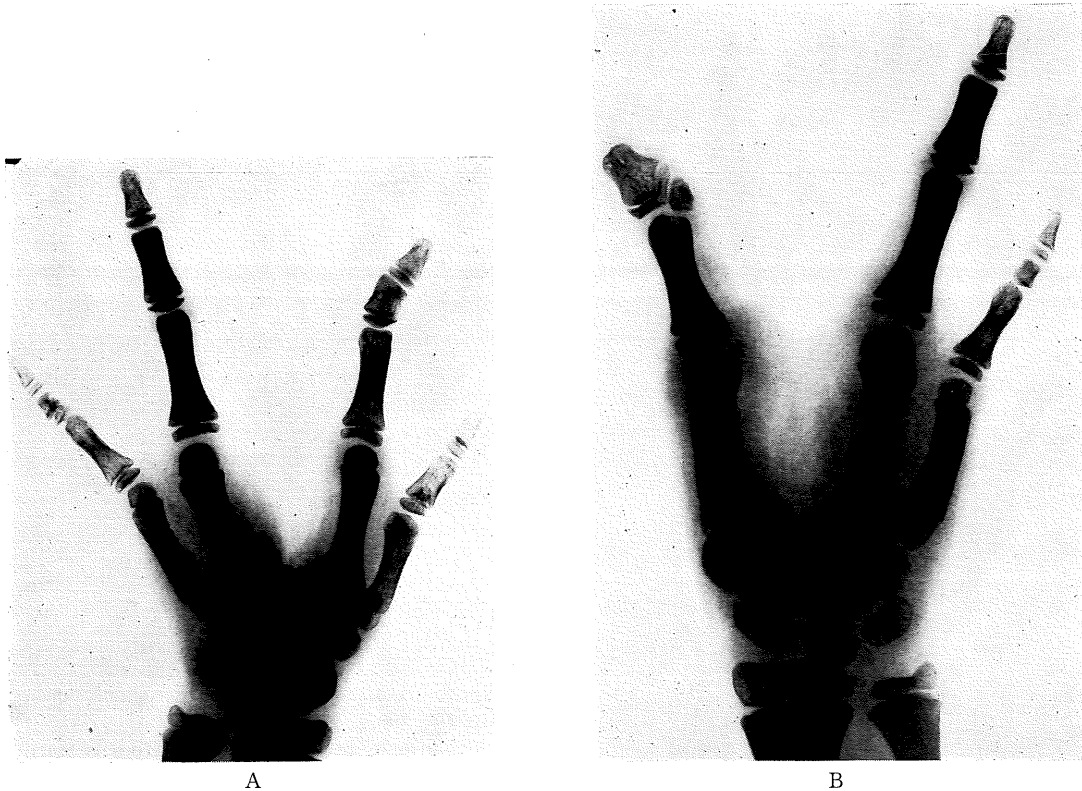


Fig. 9. Bilateral cleft hand case which demonstrates direct progression of symptoms to single ray proximal defect type.

A: Left hand is of single ray proximal defect type.

B: Right hand is two ray defect type and evidence of ray fusion of the thumb and index finger is demonstrated by such signs as three phalanges and delta phalanx, and a duplication can be seen in the terminal phalanx.

tyly, the answer would be it is not totally unrelated, it has a very close relationship. That is, in bilaterally affected hands, it is often noted that in one hand there is cleft hand (single ray distal type), while the other has syndactyly. This syndactyly is different from the transitional type of ray fusion, but is the usual simple syndactyly or osseous syndactyly, and cannot be distinguished from syndactyly that develops unrelated to cleft hand (Fig. 11).

There are various theories as to the developmental mechanism of this syndactyly, but author feels that it is not unrelated to the development of cleft hand, and plays some in the developmental mechanism. The reasoning behind this thinking is that as shown in Fig. 12, in the contralateral hand of a case with the balanced form of single ray distal defect, bifid terminal phalanx was found in the distal phalanx of the ring finger. That is, it is beyond doubt that

at the basis there is ray fusion of the polydactylous partner of the middle finger. It was considered that the polydactyly of the middle finger on one hand was retained as the original middle finger, while the other was lost following ray fusion with the ring or index finger, and syndactyly was formed in the meantime. This process begins from A-1, A-2, or A-3, A-4 and proceeds on to syndactyly. This syndactyly was caused by abnormal separation and distribution of digital rays which take place at the same time as development of polydactyly. If the separation is accurately executed, it should result in a normal hand, and the abnormal distribution would inhibit the development of polydactyly. In other words, it can be said that it is the energy to revert the abnormal to normal, which makes it most interesting.



Fig. 10. Bilateral cleft hand case which progresses from two ray defect type.

The right hand is a two ray defect type, while the left hand is a three ray defect type. Fusion of the metacarpus of the ring and little finger has begun, and upon completion it is felt that it will progress to a three ray defect type as in the left hand. The thumb has become triphalangeal.

DIAGRAM OF CLEFT HAND

As described above, there is a set flow pattern in the development of cleft hand, and by pursuing this flow the overall scope of the entity can be ascertained. Fig. 1 begins with the developmental mechanism of cleft hand and shows the process on the basic type via the various transitional types. The gradual aggravation of symptoms is illustrated in the schematic drawing. The infinite intermediate types which fall between the starting point and the end point are all represent types of cleft hand. Therefore, when attempting to establish a definition or describing the morphology, it cannot be helped if prose-like expressions are used. This also serves to help understand the difficulties encountered.

The most interesting point is the involvement of polydactyly of the middle finger in the developmental mechanism. However, it is generally acceptable that polydactyly which is a congenital defect of the hand, predominantly involves to the thumb, followed by the little finger, and is rare in the middle three fingers, particularly the middle finger. In the cases handled by us, the number of middle finger polydactyly is few in comparison to the number of cases with cleft hand. Generally, the index and ring fingers form syndactyly as shown in Fig. 13. It is extremely rare that the polydactylous partner of the middle is separate and independent. This is considered due to the fact although supernumerary fingers develop in the middle finger, they are not expressed as such, but are concealed by cleft hand within the index

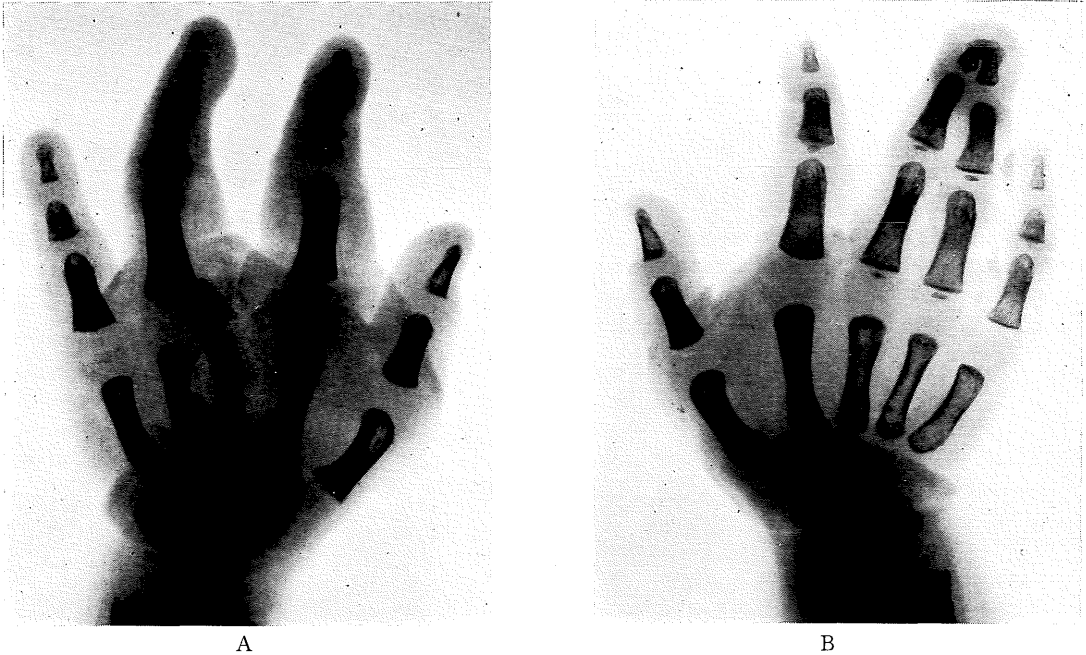


Fig. 11. Syndactyly combined with cleft hand

This is a bilaterally affected case with single ray distal defect in the left hand and osseous syndactyly of the distal planax in the right. There are many similar cases with simple syndactyly.

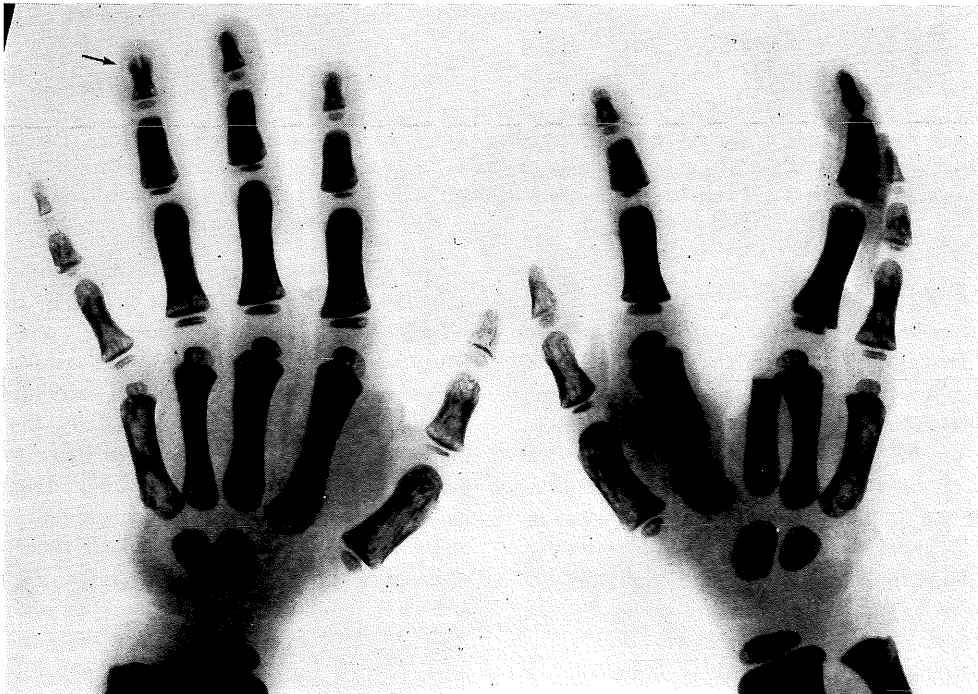


Fig. 12. Syndactyly combined with cleft

The right hand has single ray distal defect type, cut the left hand shows simple incomplete syndactyly. Hypertrophy is seen in the distal phalanx of the left ring finger with bifid terminal phalanx which suggests the strong involvement of digital ray fusion in such cases of syndactyly.

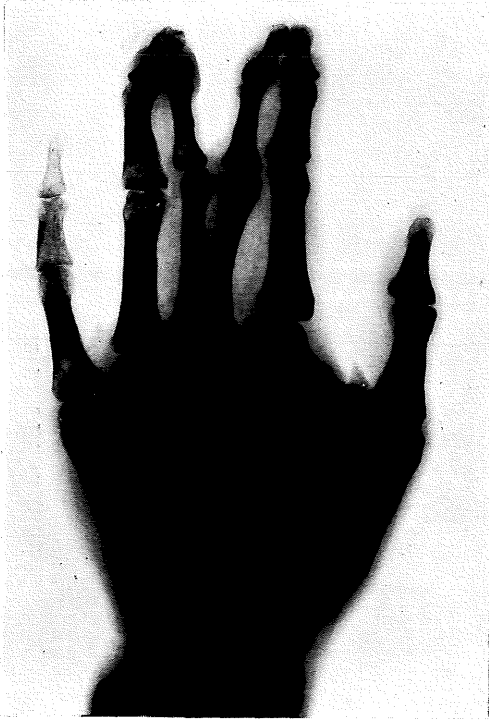


Fig. 13. A case with polydactyly of the middle finger

Generally, polydactyly of the middle finger is rare, in the most case the polydactylous partner unite with the index and ring fingers. There is a problem in deciding whether cases such as this can be called syndactyly, but the external appearance is that of deficit of the middle finger.

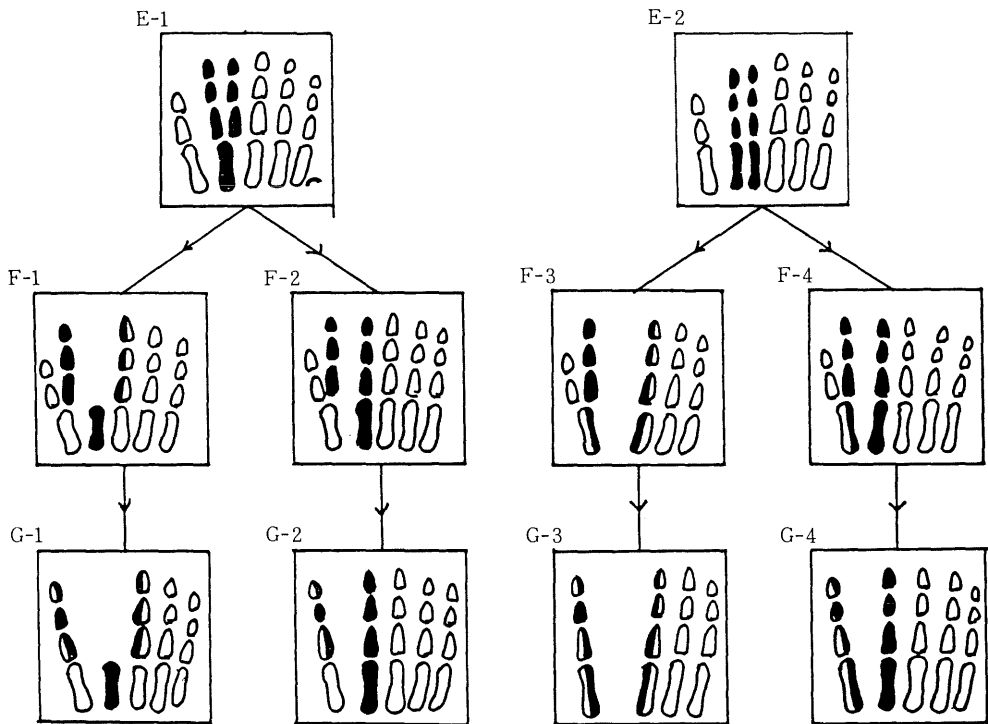


Fig. 14. Cleft hand changes in the index finger ray

This schematic diagram is an assumption of the outcome if the same cleft hand phenomenon as in the middle finger were to develop in the index finger.

The E-row shows the original changes, the F-row the intermediate transitional form and the G-row the terminal form,

and middle fingers, and are expressed as an anomaly with a completely different external appearance. It may be said this is a major characteristic of congenital abnormality of the hand which occurs during the period of formation of the hand plate.

Then how would the polydactylous phenomenon be explained when it developed in the index or ring fingers which are also central fingers and it is of interest to find out clinical cases which have same appearances as the theoretical cases.

CLEFT HAND PHENOMENON IN THE INDEX FINGER

We would like to describe the types of changes that would occur if polydactylous phenomenon similar to that of middle finger were to occur in the index finger using schematic diagrams as shown in Fig. 14.

There is a slight morphological difference between proximal phalangeal type (E-1) and metacarpal type (E-2) polydactyly which develop the index finger, two pathways can be considered one is that the radial side partner and ulnar side partner fuse with the digital ray of the thumb and index finger respectively and as a result distal defect (G-1) and proximal defect (G-3) develop, and the other is the radial partner alone fuses with the digital rays of the thumb while the ulnar partner remains as the index finger, thus pursuing the pathways of G-2 and G-4. In reviewing these end types, G-1 and G-3 can be considered cleft hand which developed in the index finger ray, but the greatest characteristic is the formation of a triphalangeal thumb. G-2 and G-4 also have triphalangeal thumbs which are considered not to have any relationship whatsoever with cleft hand. It is a surprise that F-2 and F-4 which are intermediate types polydactyly of the thumb.

Next, although these phenotypes are acceptable from the theoretical point of view, the question is do they actually exist? As the cases handled by us, a case that corresponds to G-1 is that shown as Fig. 15. As growth of the second metacarpus was poor, it was considered to be an intermediate type on the pathway to G-3, but the thumb definitely was triphalangeal, and cleft hand at the index finger definitely existed. Further, F-2 and F-4 have polydactyly of the thumb, and the ulnar partner

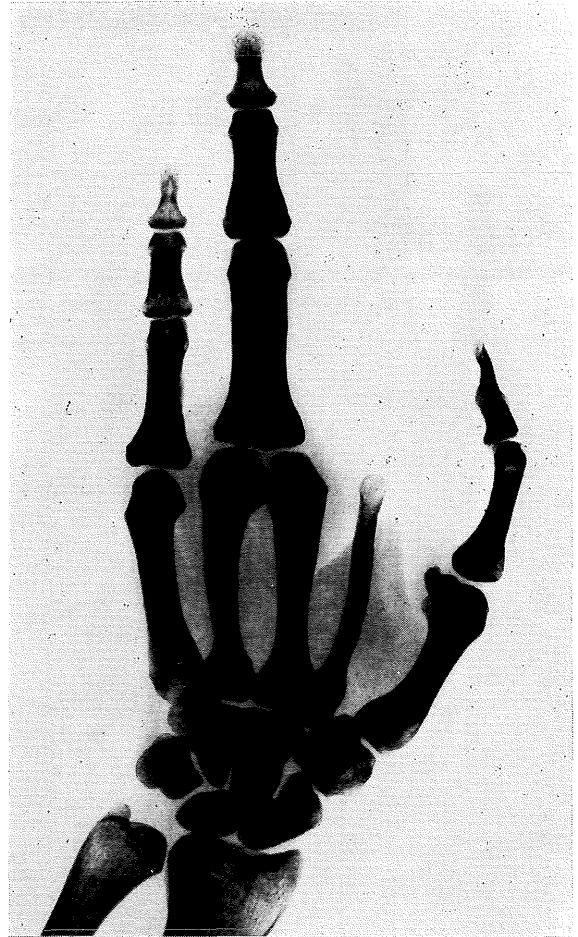
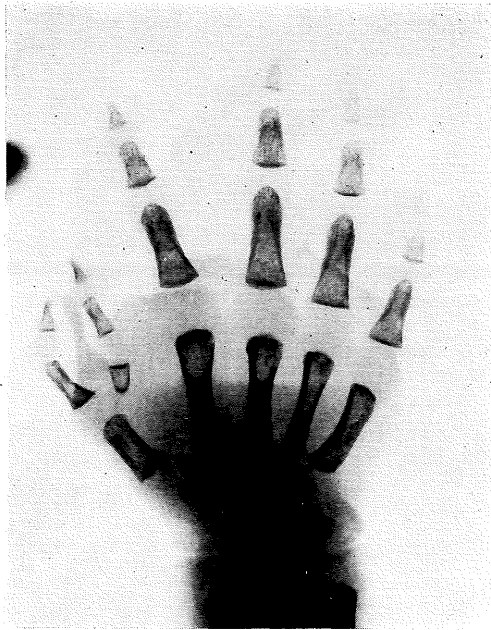
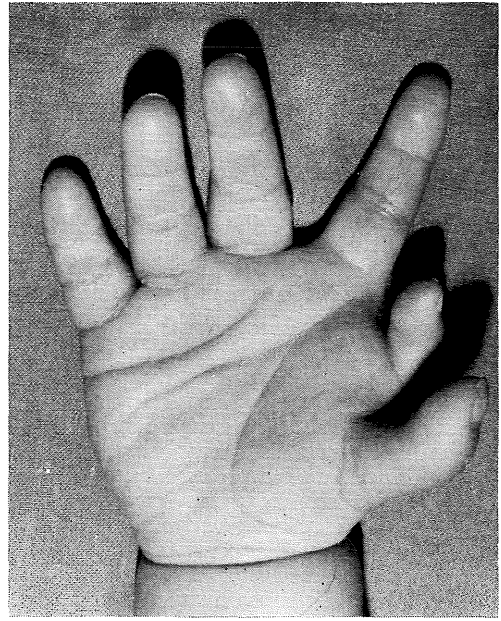
Fig. 15. A cleft hand case considered to have developed in the index finger ray

The metacarpus of the index finger shows hypoplasia and there is a defect beyond the proximal phalanx. There is triphalangeal thumb and marked hypertrophy of the ring finger ray. The image is the same as that of cleft hand of the index finger shown in Fig. 14.

has three phalanges which corresponds to type VII of Wassel's classification⁷⁾. Cases such as shown in Fig. 16 are numerous. There are also cases such as shown in Fig. 17 which present interesting findings. This is a case of polydactyly of the index finger with incomplete transition of the radial component to the thumb, and is thus a type intermediate between F-1 and F-2. G-2 and G-4 are usually referred to as single type triphalangeal thumb, and their developmental mechanism and position within the classification had been unknown, but it is considered a very good clue has been obtained



A



B

Fig. 16. Case with thumb polydactyly in which the ulnar partner has three phalanges

Thumb polydactyly in which the components on one side have three phalanges is called type VII in Wassel's classification, and there are three types, radial or ulnar three phalanges and both three phalanges. Cleft hand of the index finger comes under ulner three phalangeal type.

A: X-ray findings

In many cases, there is hypoplasia of the radial and ulnar partner.

B: External appearance

The ulnar partner with three phalanges is gener-ally attached to the index finger side, which sug-gests that it is the index component.

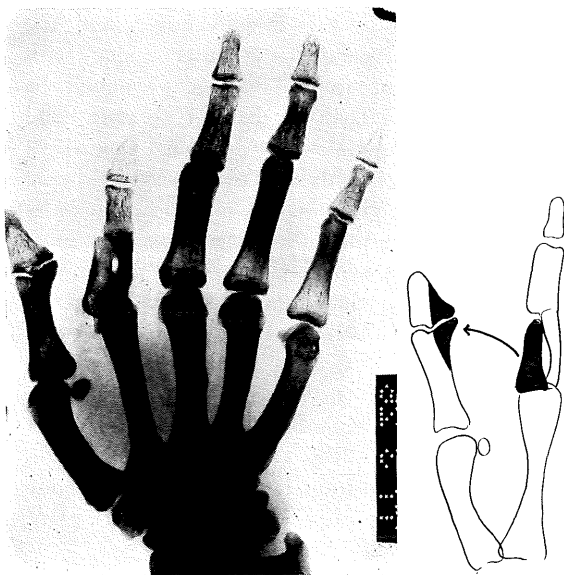


Fig. 17. A case of intermediate transitional type which shows transposition of the polydactylous component of the index finger to the thumb

Incomplete polydactyly of the index finger and bone deformity in the IP joint of the thumb can be seen. This is considered an incomplete transposition of the polydactylous component of the index finger,

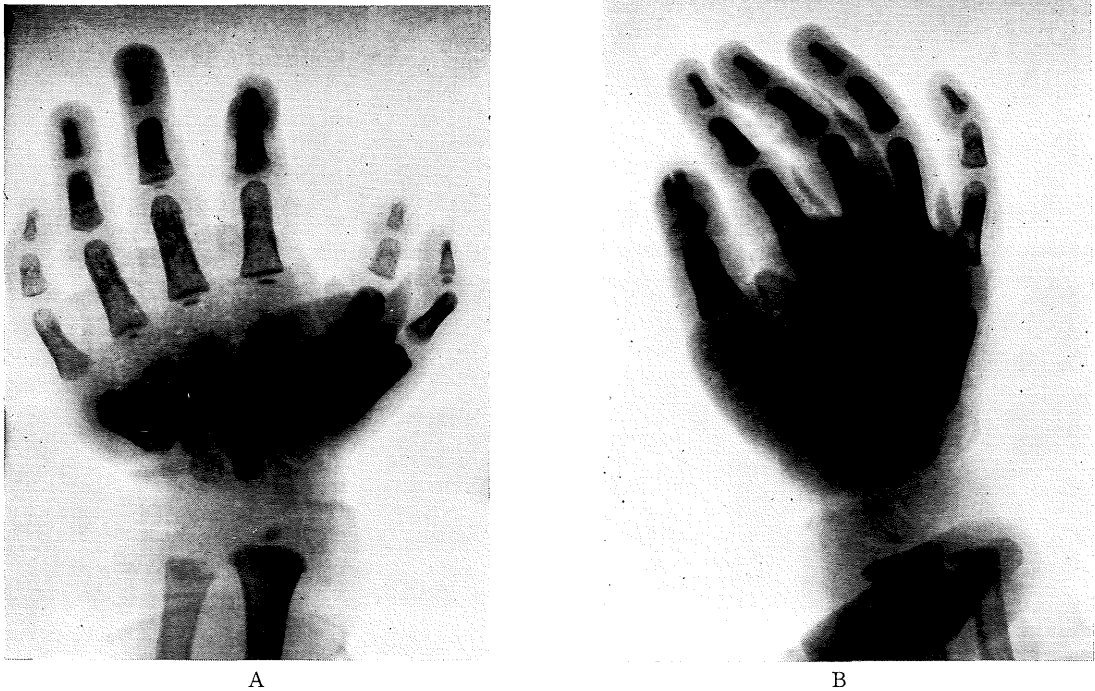


Fig. 18. A case with ulnar three phalangeal type thumb polydactyly and triphalangeal thumb
 A: The left hand has ulnar three phalangeal thumb polydactyly. The morphology of the ulnar partner indicates that it was derived from the index finger.
 B: The right hand shows ray fusion of both components with duplication of the terminal phalanx and triphalangeal thumb.

through this study. If the intermediate type to G-2 and G-4 is polydactyly of the thumb, then single type triphalangeal thumb and thumb polydactyly should coexist in both hands when the bilateral hands are affected. A case such as shown in Fig. 18 was found among our patient.

As mentioned above it was assumed that cleft hand changes which developed in the middle finger occurred in the index fingers, and in not a few cases did the clinical findings agree, thus the possibility of the existence of such courses as indicated in Fig. 14 is very high. However it is rare that they are presented morphologically as cleft hand, the frequency being higher in the form of polydactyly of the thumb. It appears that there is bias in the selection of the pathway.

CLEFT HAND PHENOMENON IN THE RING FINGER

As in the case of the previous item, schematic diagrams as shown in Fig. 19 was prepared assuming the various forms of polydactylous

changes in the ring finger. The changes which are the starting point are proximal phalangeal type of polydactyly (J-1) or metacarpal type polydactyly (J-2), the radial side polydactylous partner going to the middle finger and the ulnar side polydactylous partner fusing with the little finger ray. Two pathways can be considered, one is distal defect type cleft hand of the ring finger (L-1) or proximal type (L-3) and the other is only the radial partner being retained as the ring finger while the ulnar partner fuses with the little finger ray and most likely forms a syndactylous ring—little finger.

Formation of cleft hand in the ring finger is not commonly known, but it is occasionally experienced in the clinic. One such example is Fig. 20. That is, Fig. 20-A is a distal defect type cleft hand, while 20-B is a proximal defect type showing a deep cleft. Fig. 20-C is an intermediate transitional type and a cross bone can be observed. It also has characteristics of middle finger cleft hand.

Further, although K-1 and K-2 which are

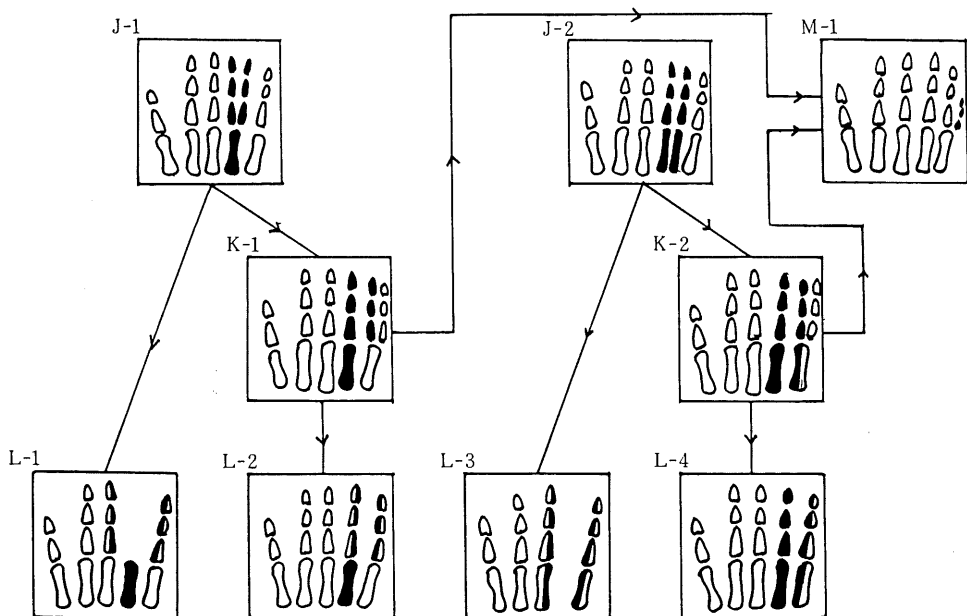
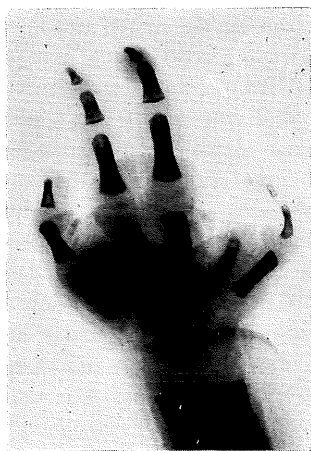

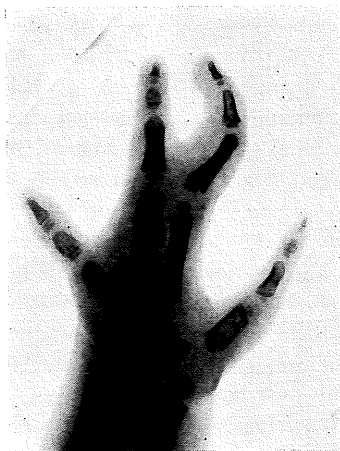Fig. 19. Cleft hand changes in the ring finger ray

This schematic diagram is an assumption of the outcome of the same cleft hand changes as in the middle finger were to develop in the ring finger.

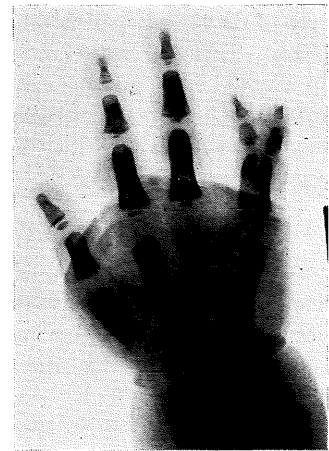The J-row shows the original polydactylous changes, the K-row the intermediate form, and the L-row the terminal form. The changes from K-1 and K-2 to M-1 were suspected from findings in clinical cases.



A



B



C

Fig. 20. X-rays of cleft hand of the ring finger

A: Single ray distal defect type

B: Single ray proximal defect type with deep cleft

C: Intermediate type with cross bone

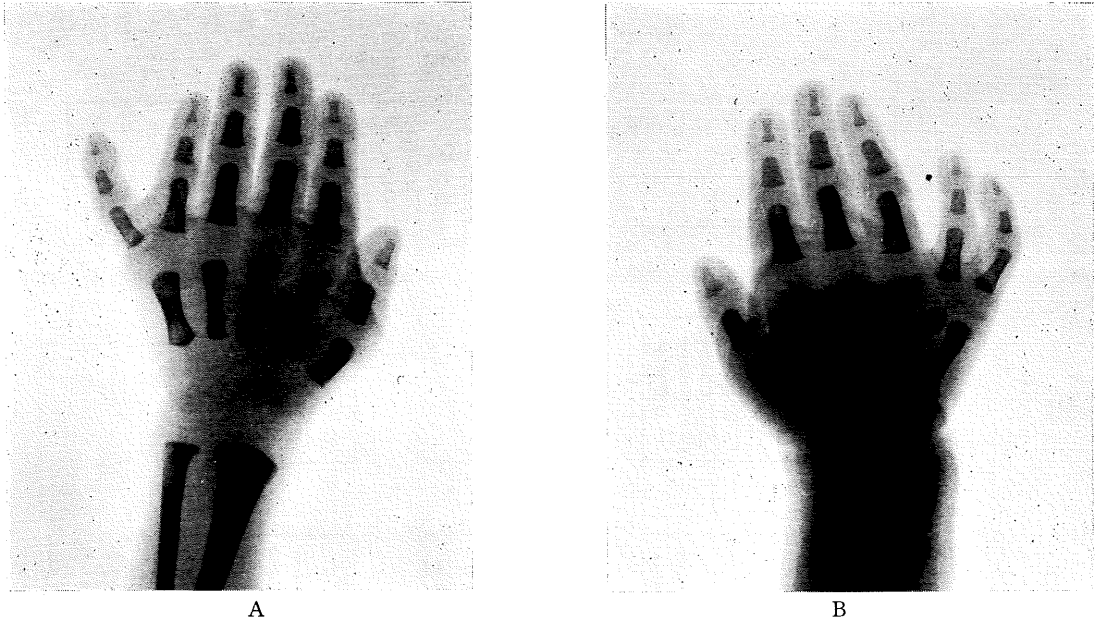


Fig. 21. X-rays of polydactyly of the little finger in cases with bilateral affection

A: The left hand has the generally known polydactyly of the little finger.

B: The morphology of the phalanges and site suggests this to be polydactyly of the ring finger.

It is considered that there are many cases in whom transposition of the finger ray in polydactyly of the ring finger is ultimately expressed as polydactyly of the little finger.

intermediate transitional types from J-1 to L-2 and J-2 to L-4 respectively, they are presented as polydactyly of the little finger but in many cases are felt to eventually become a floating supernumerary finger characteristic of polydactyly of the little finger (M-1) which finally disappears. This is based on our experience in frequently encountering cases with a supernumerary finger present between the ring and little finger on one hand, while the other hand shows a perfect polydactyly of the little finger. (Fig. 21)

RESULTS

A series of animal experiment and clinical analyses have been performed to elucidate the developmental mechanism of cleft hand, in an effort to ascertain the true state of congenital anomalies of the hand. As a result, we have emphasized that the developmental mechanism of the commonly encountered cleft hand is based on polydactyly of the middle finger. Further, as there are a large variety of morphological variations and there are many ambiguous point in the diagnosis and diagnostic criteria, erroneous information is frequently transmitted through clinical statistics and genetic counseling.

Therefore, with the purpose of presenting a comprehensive scope for cleft hand, an attempt has been made to briefly report on its developmental mechanism.

The comprehensive scope of cleft hand, begins with polydactyly of the middle finger as shown in Fig. 1, but at the stage where each component of polydactyly forms simple syndactyly between the index and ring fingers as shown in Fig. 13, it is polydactyly of the middle finger, but at the stage of finger ray fusion, the condition falls within the diagnostic scope of cleft hand. Therefore, the right hand in Fig. 2, and the left hand in Fig. 3, should be classified as cleft hand. From this stage, various types of cleft hand with varying finger ray defects develop, but the two forms of single ray distal defect type originally were one, and it is definitely wrong to classify as osseous syndactyly ring or index finger rays with markedly hypertrophic phalanges, there should be diagnosed as cleft hand. Syndactyly which appears in conjunction with cleft hand, is a secondary occurrence which develops concomitant with cleft hand changes of the mesenchymal component, and is definitely different from digital ray fusion

which is the main cleft hand change. However, as the syndactyly which develops does not have specific morphology, the possibility that cleft hand changes may have occurred during the course of development cannot be negated, thus care must be exercised.

Such cleft hand originates in polydactyly of the middle finger as shown in Fig. 1 and covers all of the various type of transitional forms up to the terminal transverse arrest, and is not a name given to any specific morphological type. From this point of view, the expression "cleft hand complex"³⁾ is a very meaningful description.

As stated above, cleft hand has as its origin changes in the middle finger, but generally the term central fingers implies not only the middle finger, but in many instances the index, middle and ring fingers. Thus, it is of interest to ascertain as to whether there is a possibility that such changes occur in the index and ring fingers. Thus, changes such as those shown in the schematic diagram of Fig. 1 were prepared for the index and ring fingers. The diagram for the index finger is shown in Fig. 14, but rather than developing cleft hand as in the case of the middle finger, it was surprising to note that such anomalies as polydactyly of the thumb, and its terminal type, single type triphalangeal thumb, which are generally totally unrelated to cleft hand had developed. Further, in our subsequent review of clinical cases, it became obvious that there were many cases with findings that agreed with the diagram. Thus, the presence of such changes can be said to be almost confirmed. However, it is usually very rare for one to encounter a person with polydactyly or cleft hand, which is probably due to the fact that in almost all cases, the condition has assumed the form of Wassel VII type polydactyly of the thumb.

The diagram for the ring finger is shown as Fig. 19. The presence of cleft hand changes shown here have been confirmed in clinical cases. However, such cases are not numerous and practically all are expressed as syndactyly of the ring and little fingers and polydactyly of the little finger, and not a few are felt to assume a normalization process.

As stated above, cleft hand does not develop solely in the middle finger, but exactly the same phenomenon can be found in the index and

ring fingers. However, another characteristic is that there are some which assume an entirely different morphology, and to include these under cleft hand complex would rather run the risk of creating confusion. For cases such as shown in Fig. 15, 17 and 20, it would be appropriate to assign them the diagnosis index and ring cleft hand. It is felt necessary to bear in mind that cleft hand changes lie in the background of cases with Wassel VII type polydactyly of the thumb, single type triphalangeal thumb and polydactyly of the little finger.

There have been strong theories which suspect the involvement of genetics in cleft hand, but the involvement of genetics does not lie in the middle finger, but lies in the mechanism, thus consideration must also be given to changes in the index and ring fingers which apparently appear to be unrelated to the above mentioned cleft hand.

Whether it be the middle, index or ring finger, why does such a phenomenon, i.e., combination of development of polydactyly and digital ray fusion take place? Fundamentally, it is a quantitative and distributional anomaly of the mesenchymal cells within the hand plate. As both progress at about the same time, it is only that it is generally rare to observe the presence of polydactyly. Digital ray fusion does not mean that finger rays once separated are re-fused again, but that the digital rays fail to separate due to anomaly in distribution, thus, it would probably be more appropriate to term the state non-separation. Such phenomenon occurs within the hand plate and as it is based on abnormality in ectodermal-mesenchymal interaction, it is considered a special anomaly which appears late in the polydactylous stage.

On the other hand, it is felt that the developmental mechanism of cleft hand is a so-called normalization process which involves the correction of course as a result of the ectoderm changing its distribution pattern after having sensed an abnormality of the mesenchym. The concept that the propelling power towards abnormalization is, in fact, energy for its normalization is very interesting from the viewpoint that the development of congenital anomaly is considered an *in vitro* phenomenon.

Study is presently being carried out on the thumb anomaly caused by cleft hand mechanism and its relation to other thumb anomaly.

REFERENCES

1. **Barsky, A. J.** 1964. Cleft hand: classification, incidence and treatment. *J. Bone and Joint Surg.* **46-A** : 1707-1720.
2. **Birch-Jensen, A.** 1949. Congenital deformities of the upper extremities. *Ejnar Munksgaard, Copenhagen* 46-67.
3. **Kelikian, H.** 1974. Congenital deformities of the hand and forearm. *W.B. Saunders*, 467-495.
4. **Lange, M.** 1936. Grundsatzliches uber die Beurteilung der Entstehung in Bewertung atypischer Hand und Fussmisbildungen. *Verhandl. Deutsh. Orthop. Gesellsch.* **31** : 80-87.
5. **Miura, T.** 1976. Syndactyly and split hand. *The Hand* **8** : 125-130.
6. **Pokorny, L.** 1924. Zur Klinik und Atiology der Spalthand. *Fortschr. Rontgenstr.* **32** : 274-280.
7. **Wassel, H. D.** 1969. The result of surgery for polydactyly of the thumb. *Clin. Orthop.* **64** : 175-193.
8. **Watari, S.** 1977. Clinical and experimental studies on cleft hand. *Med. J. of Hiroshima Univ.* **26** : 245-287.
9. **Watari, S. and Tsuge, K.** 1979. A classification of cleft hands, based on clinical findings. *Plast. Reconstr. Surg.* **64** : 381-389.