

Intraarterial Digital Subtraction Angiography for Evaluating Hepatic Tumors

Akira NAITO, Katsuhide ITO, Haruhito FUKUOKA, Shoko ITO,
Kumiko NAITO and Shizutomo KATSUTA

Department of Radiology, Hiroshima University School of Medicine, 1-2-3 Kasumi, Minami-ku,
Hiroshima 734, Japan

ABSTRACT

The intraarterial digital subtraction angiography (DSA) of 52 patients with hepatic tumors was retrospectively reviewed. In 18 patients, intraarterial DSA was compared with conventional angiography. With DSA, the displacement of arteries, arterial encasement and tumor vessels were equally well identified on comparison with conventional angiography. DSA was superior to conventional angiography in demonstrating tumor stains. The diagnostic imaging capability of DSA was studied in 52 patients. In the majority of cases, DSA imaging was diagnostic for visualizing the tumors and determining their extent. The differential diagnosis of hepatic tumors was made without difficulty. Demonstration of the portal venous system was excellent using smaller quantities of contrast material and slower injection rates than by the conventional angiography. The major advantage of DSA is excellent contrast resolution and ability of the real-time information. DSA was therefore useful for evaluating hepatic tumors.

Key words: DSA, Hepatic tumors

Development of the use of digital subtraction angiography (DSA) facilitated visualizing vascular images following the intravenous injection of contrast material^{1,10}. Originally, with this method, only large arteries such as the thoracic aorta, the carotid arteries and abdominal aorta could be evaluated. Intraarterial injections using Seldinger's method had been used mainly for evaluating small arteries¹⁵.

Previously the conventional film-screen method has been used for evaluating hepatic tumors. Here, we present our experience of intraarterial selective DSA compared with conventional angiography in the examination of hepatic tumors and an diagnostic ability of DSA was reviewed.

MATERIALS AND METHODS

Fifty-two patients with hepatic tumors; 38 hepatomas, 9 metastatic tumors, and 5 hemangiomas were studied. The differential diagnosis of hepatic tumors was established by clinical evidence, and it is not difficult to make the definitive diagnosis in all patients. In 18 of the 52 patients, both conven-

tional angiography and intraarterial DSA were used. In 34 patients, only intraarterial DSA was performed. Conventional celiac arteriography was performed using 40 ml Iopamidol (370 mgI/ml) injected at a rate of 8 ml/second. Smaller volumes and slower injection rates were used for selective injection than celiac arteriography.

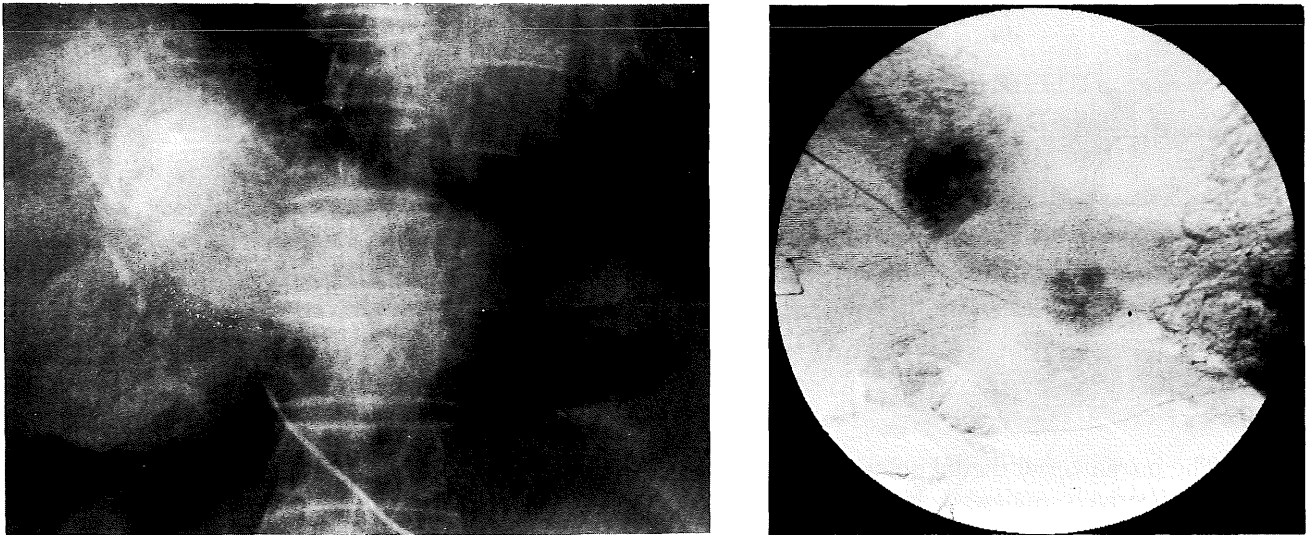
For a DSA study, celiac arteriography was performed using Iopamidol (370 mgI/ml) diluted with 1 part saline solution. The injection rate was 5-6 ml/sec, for a 20-30 ml injection. To demonstrate the portal venous system, venous-phase arteriography was performed after a superior mesenteric artery injection using 20 ml undiluted contrast material at a rate of 7 ml/sec. Prostaglandin E₁ was injected via the catheter 30 sec before the superior mesenteric artery injection.

A TOSHIBA DFP-50A commercially-available X-ray apparatus having a 1.0 mm focal spot X-ray tube, a 7 and 9 inch image intensifier with continuous mode, and a 1024 × 1024 × 12 matrix, was used.

Table 1. Comparison of DSA and Conventional Angiography (AG) according to Arteriographic Findings

	DSA > AG	DSA = AG	DSA < AG	Total
Arterial displacement	3	9	2	14
Arterial encasement	1	2	6	9
Tumor vessels	3	5	0	8
Tumor stains	11	5	2	18

(N=18)

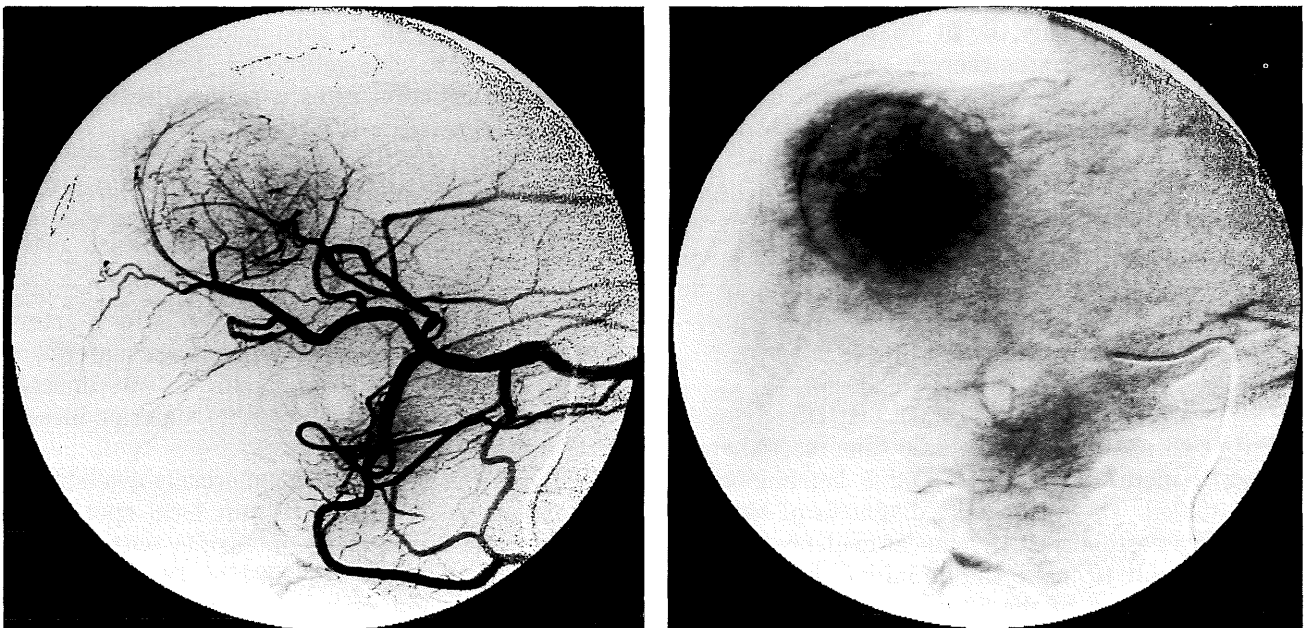


a. **Fig. 1.** Hepatoma. Superselective arteriography on conventional angiography (a) and celiac arteriography on DSA (b). Tumor stain in the left lobe is not identified on conventional arteriography, but DSA clearly reveals the tumor stain.

Table 2. Diagnostic Capability of DSA

	Excellent	Diagnostic	Non-diagnostic	Total
Hepatomas	22	14	2	38
Metastatic liver tumors	4	4	1	9
Hepatic hemangiomas	1	2	2	5

(N=52)

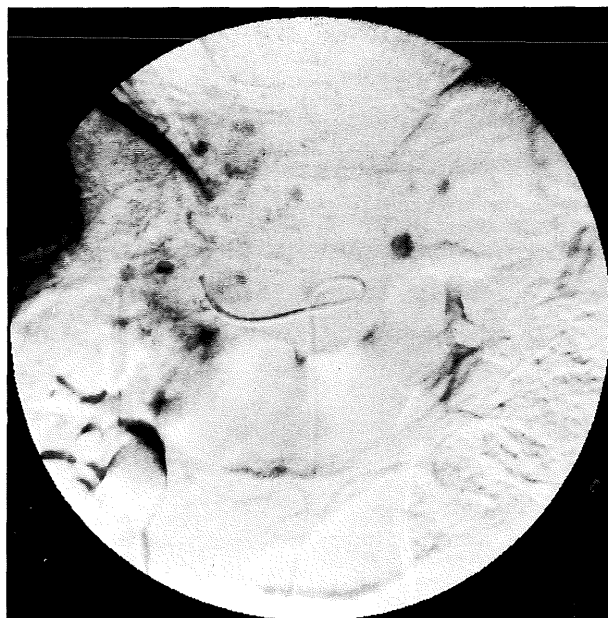
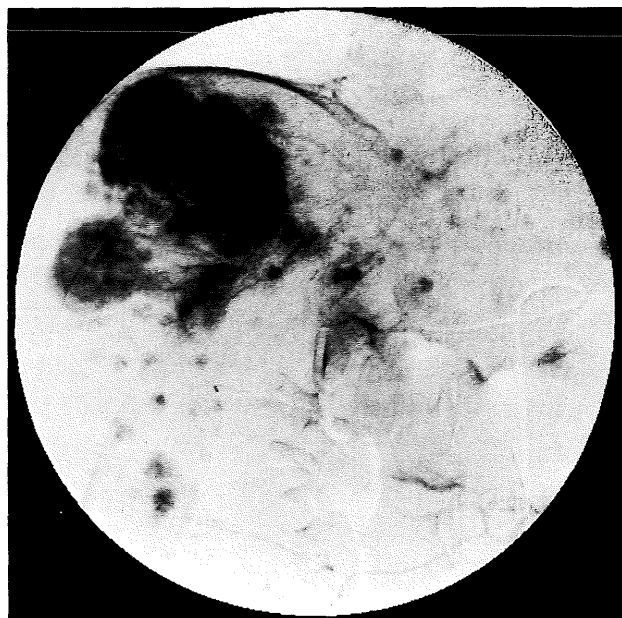


a. **Fig. 2.** Hepatoma of the right hepatic lobe. DSA clearly reveals the displacement of the artery and tumor vessels in the arterial phase (a). In the parenchymal phase, the tumor stain is well-defined and the draining vein is also seen (b).

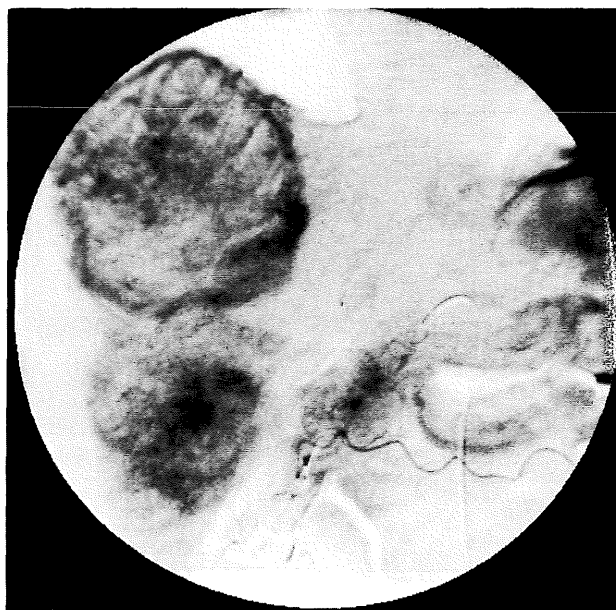
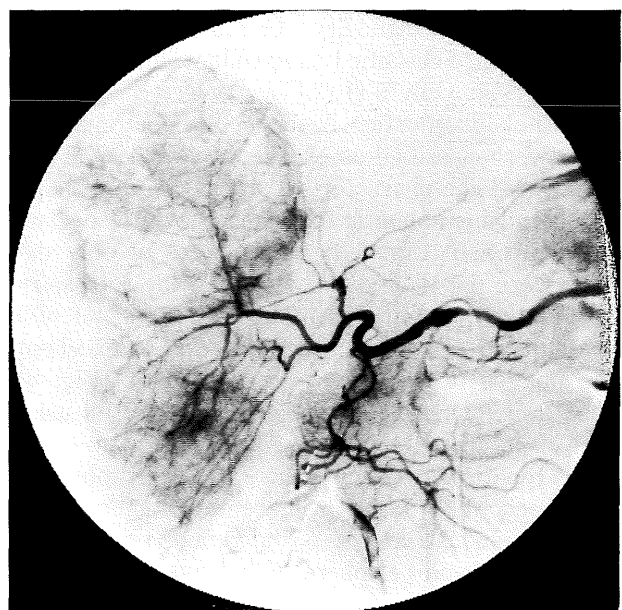
RESULTS

The quality of the DSA images was compared with that of conventional arteriography, and evaluated for the 18 patients. Visualization of displaced

arteries, arterial encasement, tumor vessels and tumor stains was reviewed. To assess these angiographic findings, conventional arteriography and DSA studies were compared directly for the 18 pa-



a. **Fig. 3.** Hepatoma. Superselective hepatic arteriography in the parenchymal phase. Hypervascular tumors are seen in the right hepatic lobe. Small tumor stains in the right and left lobes are clearly demonstrated on DSA (a,b).



a. **Fig. 4.** Metastatic hepatic tumor. Superselective hepatic arteriography demonstrates neovascularity and multiple hypervascular tumors within a central lucency (a,b).

tients, and the modalities were compared to determine which of the two procedures was better accomplish the visualization (Table 1). DSA demonstrated displacement of arteries better than conventional arteriography in 3 (21%) of 14 cases and they were equally effective in 9 (64%) of 14 cases. Arterial encasement was better demonstrated by conventional arteriography in 6 (67%) of 9 patients, and was equally well imaged in 2 (22%) of 9. Tumor vessels were better delineated by DSA in 3 (38%) of 8 patients and equally well in 5 (63%)

of 8. In 11 (61%) of 18 patients, tumor stains were better demonstrated by DSA and equally well in 5 (28%) of 18.

Tumor stains in the left lobe of the liver and stains of small diameter, which were not clearly visualized on the conventional arteriography, were clearly visualized by DSA (Fig.1).

For all 52 patients, the capability of diagnosing hepatic tumors was studied using DSA alone. The DSA images were classified for overall diagnostic capability as follows : excellent = excellent contrast

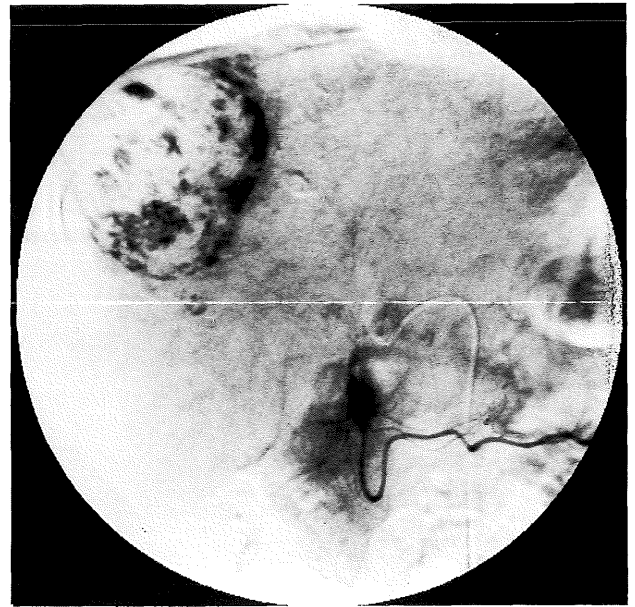
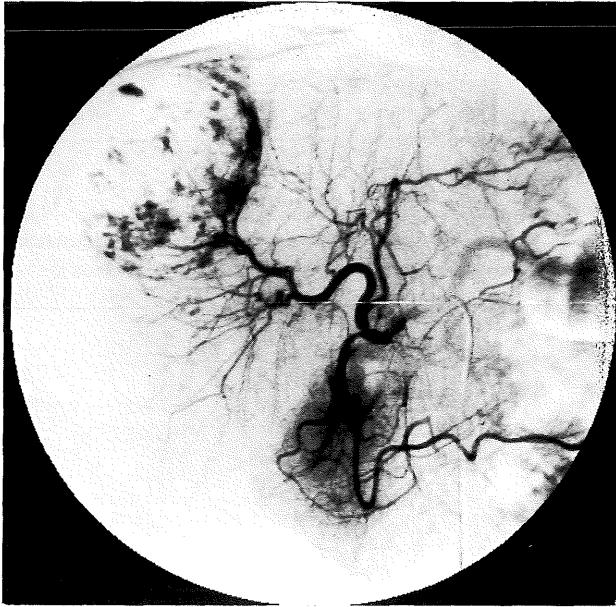


Fig. 5. Hepatic hemangioma. A peripheral vascular stain with pooling of contrast material is seen in the right lobe.

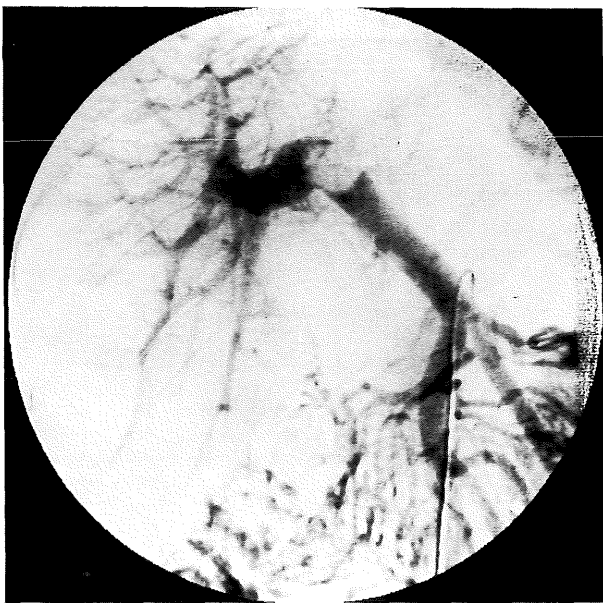


Fig. 6. Hepatoma with a portal vein thrombus. Venous phase of a superior mesenteric arteriogram demonstrates the filling defect in the portal vein, and the left branch of the portal vein is not seen.

and spatial resolution; diagnostic = acceptable for diagnosis; and non-diagnostic = poor demonstration; not acceptable for diagnosis (Table 2). Hepatomas were imaged as hypervascular tumors but were partially hypovascular. Intrahepatic metastases were imaged as small homogeneous hypervascular tumors. Metastatic hepatic tumors were imaged as hypervascular tumors with central lucencies or as hypovascular tumors. Hepatic hemangiomas were identified as a spherical vascular stains associated with pooling of contrast

material of long duration, into the venous phase. The differential diagnosis of hepatic tumors was possible without difficulty. Among all the patients, 27 (52%) were classified as excellent; and 20 (38%) as diagnostic. Only 5 (10%) cases were classified as being not diagnostic. Among 38 hepatomas, 22 (58%) were classified as excellent; and 14 (37%), as diagnostic. The characteristic appearances of hepatomas and intrahepatic metastases were especially well identified (Fig. 2,3). The images of only two cases were not diagnostic. This was due to respiratory and cardiac motion. Those of 4 (44%) of 9 metastatic liver tumors were classified as excellent. The images of 4 (44%) were diagnostic (Fig. 4). Hepatic hemangiomas were easily diagnosed using DSA (Fig. 5).

In 41 patients, venous-phase arteriography was performed after superior mesenteric artery injections to demonstrate the portal venous system. The extrahepatic and peripheral intrahepatic portal systems were clearly identified. The images of 13 (32%) cases were classified as excellent; those of 20 (49%), as diagnostic; and those of 8 (19%), as not diagnostic. Tumor thrombi in the portal vein, and retrograde flow in the left coronary vein, short gastric veins, and esophageal veins, were well identified (Fig. 6).

DISCUSSION

The major advantage of intraarterial DSA is its excellent contrast resolution compared to that of conventional angiography. The contrast sensitivity of DSA is approximately 1 percent of the contrast material by phantom study¹²). Acceptable images can be obtained using diluted contrast material, and small volumes, and catheters of small dia-

meters^{2,3,9,11}). By these means, patients feel less discomfort. Furthermore, intraarterial DSA is used as a definitive angiographic procedure which can be performed on an outpatient basis. An additional advantage of DSA is an availability of the real-time information. Real-time DSA facilitates critical decisions without appreciable delays reducing the time necessary for the examination. DSA has proved extremely useful in interventional angiography. Real-time information permits frequent, accurate evaluations of the extent of interventional procedure. DSA is also helpful for follow-up examinations.

Intraarterial DSA has several limitations⁸). DSA images have less spatial resolution than do those of the conventional angiography. Evaluations of small vessels, arterial encasement and tumor vessels is difficult using a 512×512 matrix. However, improved spatial resolution and relatively fine angioarchitectural detail have been achieved with a 1024×1024 matrix⁶). Respiratory and bowel motion may degrade images considerably^{7,8}).

Selective celiac arteriography is commonly performed for hepatic angiography as vascular mapping for a subsequent superselective arteriography. Superselective arteriography is then performed to evaluate the angiographic findings in the liver. In the arterial phase of arteriography, normal hepatic arteries, displacement of arteries and tumor vessels were satisfactorily evaluated using DSA. Arterial encasement was not so clearly demonstrated because of inferior spatial resolution. In the parenchymal phase, tumor stains were better demonstrated by DSA than by conventional angiography because of superior contrast resolution^{5,14}). Tumor stains in the left lobe and small stains were clearly identified even on selective celiac arteriography. Angiographic images of hypervascular tumors were easily evaluated, so the differential diagnosis of hepatomas, hemangiomas and metastatic hepatic tumors was easily made. However, if the differential diagnosis of hepatic tumors proves difficult by using DSA, the examination using a conventional film-screen method is recommended. Fine vessels, slight changes of arteries and the extents of tumor stains can be thus evaluated precisely.

Evaluation of the patency of the portal vein and the extents of tumors especially hepatomas, are important. DSA demonstrated the superior mesenteric vein and portal vein clearly when smaller volumes of contrast material and lower injection rates were used than by the conventional methods^{4,13}). Intrahepatic portal veins are satisfactorily imaged for evaluating portal thrombi, obviating the necessity of the conventional angiography.

In conclusion, DSA is a useful means of evaluating hepatic tumors.

ACKNOWLEDGMENT

The assistance of Dr. Walter J. Russell, Radia-

tion Effect Research Foundation, Hiroshima, in editing the manuscript is gratefully acknowledged.

(Received August 12, 1988)

(Accepted November 15, 1988)

REFERENCES

1. **Crummy, A. B., Strother, C. M., Sackett, J. F., Ergun, D. L., Shaw, C. G., Kruger, R. A., Mistretta, C. A., Turnipseed, W. D., Lieberman, R. P., Myerowitz, P. D. and Ruzicka, F. F.** 1980. Computerized fluoroscopy : Digital subtraction for intravenous angiocardiology and arteriography. *A. J. R.* **135**: 1131-1140.
2. **Davis, P. C. and Hoffman, J. C.** 1983. Work in progress. Intra-arterial digital subtraction angiography : Evaluation in 150 patients. *Radiology* **148**: 9-15.
3. **Flannigan, B. D., Gomes, A. S., Stambuk, E. C., Lois, J. F. and Paris, S. O.** 1983. Intra-arterial digital subtraction angiography : Comparison with conventional hepatic arteriography. *Radiology* **148**: 17-21.
4. **Foley, W. D., Stewart, E. T., Milbrath, J. R., SanDretto, M. and Milde, M.** 1982. Digital subtraction angiography of the portal venous system. *A. J. R.* **140**: 497-499.
5. **Foley, W. D. and Milde, M. W.** 1985. Intra-arterial digital subtraction angiography. *Radiol. Clin. North. Am.* **23**: 293-319.
6. **Gomes, A. S., Papin, P. J., Mankovich, N. J. and Lois, J. F.** 1985. Digital subtraction angiography : A comparison of 512 and 1024 imaging. *A. J. R.* **146**: 835-838.
7. **Goodman, P. C. and Brant-Zawadzki, M.** 1982. Digital subtraction pulmonary angiography. *A. J. R.* **139**: 305-309.
8. **Katzen, B. T.** 1985. Peripheral, abdominal, and interventional application of DSA. *Radiol. Clin. North. Am.* **23**: 227-241.
9. **Kaufman, S. L., Chang, R., Kadir, S., Mitchell, S. E. and White, R. I.** 1984. Intraarterial digital subtraction angiography in diagnostic arteriography. *Radiology* **151**: 323-327.
10. **Kruger, R. A., Mistretta, C. A., Houk, T. L., Riederer, S. J., Shaw, C. G., Goodsitt, M. M., Crummy, A. B., Zwiebel, W., Lancaster, J. C., Rowe, G. G. and Flemming, D.** 1979. Computerized fluoroscopy in real time for noninvasive visualization of the cardiovascular system. *Radiology* **130**: 49-57.
11. **Lee, K. R., Cox, G. G., Price, H. I., Johnson, J. A. and Neff, J. R.** 1986. Intraarterial digital subtraction arteriographic evaluation of extremity tumors : Comparison with conventional arteriography. *Radiology* **158**: 255-258.
12. **Ovitt, T. W. and Newell, J. D.** 1985. Digital subtraction angiography : Technology, equipment and techniques. *Radiol. Clin. North. Am.* **23**: 177-184.
13. **Rossi, P., Simonetti, G., Passariello, R., Tempesta, P., Pesce, B., Pavone, P. and Castrucci, M.** 1985. Digital celiac arteriography. *Radiology* **154**: 229-231.

14. **Stadnik, T. W., Kersschot, E. A. and DeSchepper, A. M.** 1985. Intracranial tumors examined by intraarterial DSA : A comparative angiography study. *Radiology* **154**: 671–675.
15. **Weinstein, M. A., Pavlicek, W. A., Modic, M. T. and Duchesneau, P. M.** 1983. Intra-arterial digital subtraction angiography of the head and neck. *Radiology* **147**: 717–724.