

Some Advantages of Transesophageal Echocardiography during Mitral Valve Replacement

Kazumasa ORIHASHI, Yuichiro MATSUURA, Hiroshi ISHIHARA, Yoshiharu HAMANAKA, Yasushi KAWAUE, Taijiro SUEDA, Keiichi KANEHIRO and Takayuki NOMIMURA

The First Department of Surgery, Hiroshima University School of Medicine, 1-2-3, Kasumi, Minami-ku, Hiroshima 734, Japan

ABSTRACT

Transesophageal echocardiography (TEE) was conducted during mitral valve replacement (MVR) in six cases. Two-dimensional echocardiography demonstrated the prosthetic valve as an oval-shaped, echogenic ring and highly echogenic disc which showed rhythmical to-and-fro movement. Using two-dimensional color Doppler echocardiography (2D-CD-TEE), the regurgitant flow was demonstrated as the toward flow looked like a flame. 2D-CD-TEE made it possible to determine the regurgitant site from the origin of the flame. In most cases the regurgitant site was located just inside of the ring, thus suggesting intentionally designed transvalvular leak. In one case, however, the regurgitant site was just outside of the ring which suggested pathological paravalvular leak. But we could not find any evidence of mitral regurgitation on the left atrial pressure tracing or necropsy 20 days after the operation. 2D-CD-TEE is considered sensitive in detecting mitral regurgitation and can provide much information during the operation without interrupting the surgical procedures or interference by the operation. Additionally it can determine the pathological paravalvular leak from functional transvalvular leak.

Key words: *Transesophageal echocardiography (TEE), Mitral valve replacement (MVR), Mitral regurgitation (MR)*

Mitral regurgitation (MR) of prosthetic valve is one of the significant complication of mitral valve replacement (MVR). It may occur as early as at the operation.

Conventional echocardiography, especially Doppler echocardiography from the transcatheter approach, is well understood valuable for the evaluation of prosthetic valves⁴, but its use is limited during heart surgery.

On the other hand, transesophageal echocardiography (TEE) has been proved to be useful for intraoperative monitoring of cardiac function without

interruption by the lung and ribs or interference to the operation^{6,7}.

The purpose of this report is to present our experience of TEE during the operation in six cases with mitral valve disease, who underwent MVR.

MATERIAL AND METHODS

The subject of this study were six patients with mitral valve stenosis and/or regurgitation. Profiles of the patients are summarized in Table 1. They were admitted to the Hiroshima University Hospital from July to October in 1987. Only case 1

Table 1. Profiles of six patients

Case	Age	Sex	Disease	Date of op.	Op.	Valve	grade of MR		
							pre-op. UCG	LVG	post-op. UCG
1 SK	65	F	MSR	July 1	MVR	SJM	I	II	nd
2 KY	54	M	MR(IE)	July 8	MVR	BS	III	—	nd
3 SY	68	M	MR,TR	July 27	MVR,TAP	BS	III	II	nd
4 NF	66	F	MS	Sep. 9	MVR	BS	I	nd	—
5 IT	53	F	MS,TR	Sep.16	MVR,TAP	BS	nd	I	nd
6 YO	54	M	AR,MSR	Oct.14	AVR,MVR	BS	III	II	nd

F:female, M:male, MSR:mitral stenosis and regurgitation, MR:mitral regurgitation, IE:infective endocarditis, TR:tricuspid regurgitation, MS:mitral stenosis, AR:aortic regurgitation, MVR:mitral valve replacement, TAP:tricuspid annuloplasty, AVR:aortic valve replacement, SJM:St.Jude Medical valve, BS:Bjork-Shiley valve. op.:operation, UCG:echocardiography, nd:not detected, —:not performed, LVG:left ventriculography (The grade of mitral regurgitation was determined according to the Sellers' criteria⁸.)

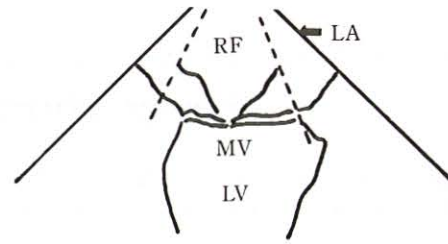
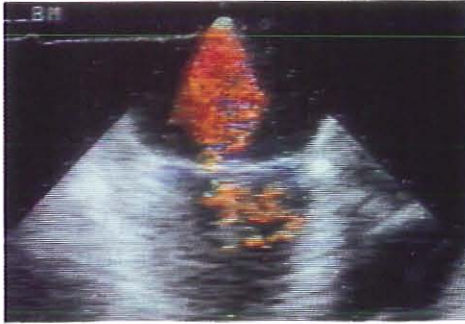

Fig. 1. Transthoracic two-dimensional color Doppler echocardiogram showing mitral regurgitation before valve replacement (case 3). It looks like a flame from the mitral valve orifice and reaches the posterior wall of the left atrium. RF: regurgitant flow, MV: mitral valve, LA: left atrium, LV: left ventricle.

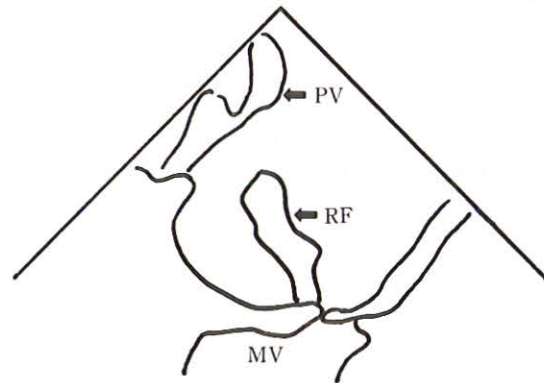
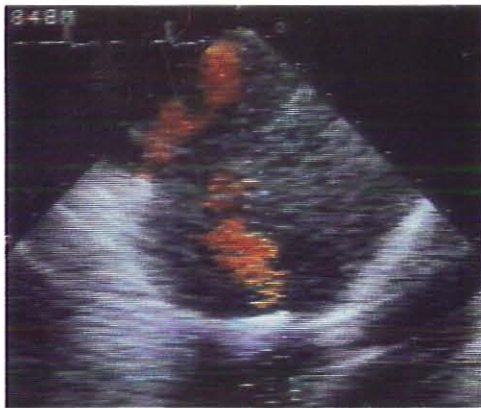

Fig. 2. Transthoracic two-dimensional color Doppler echocardiogram showing drainage flow from the left pulmonary vein (case 5). The flow is recognized near the left auricle and over the mitral valve. It is essential not to take the flow for the regurgitant valvular flow. PV: drainage flow from the left pulmonary vein, RF: regurgitant flow, MV: mitral valve.

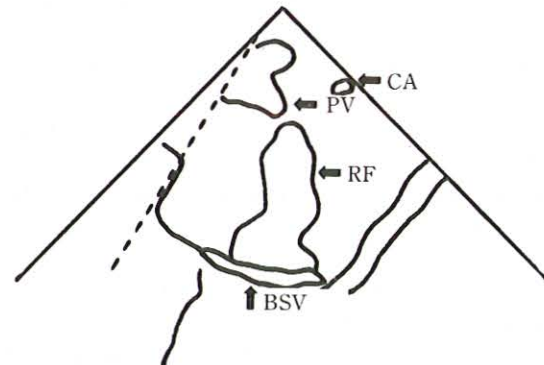
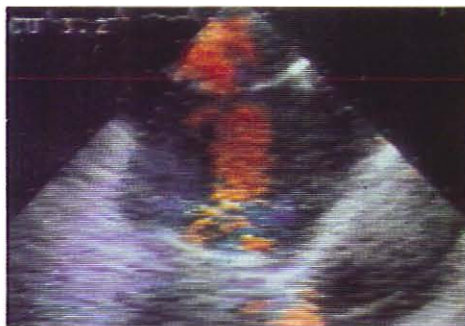

Fig. 5. Transthoracic two-dimensional color Doppler echocardiogram demonstrating regurgitant flow through a Bjork-Shiley prosthetic valve (case 5). RF: regurgitant flow, BSV: Bjork-Shiley valve, PV: drainage flow from the pulmonary vein, CA: catheter for left atrial pressure monitoring.

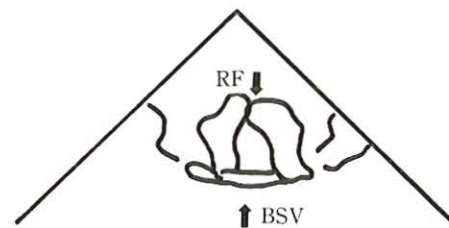
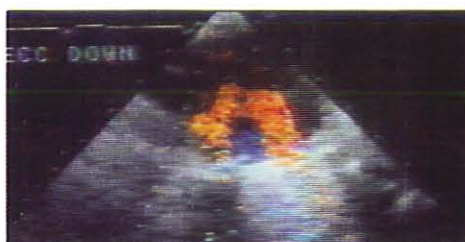

Fig. 6. Transthoracic two-dimensional color Doppler echocardiogram demonstrating paravalvular leak around a Bjork-Shiley prosthetic valve (case 4). Note that regurgitant flow originates from just outside of the ring, and the white image of the ring is slightly stained red due to the overlying regurgitant flow. RF: regurgitant flow, BSV: Bjork-Shiley valve.

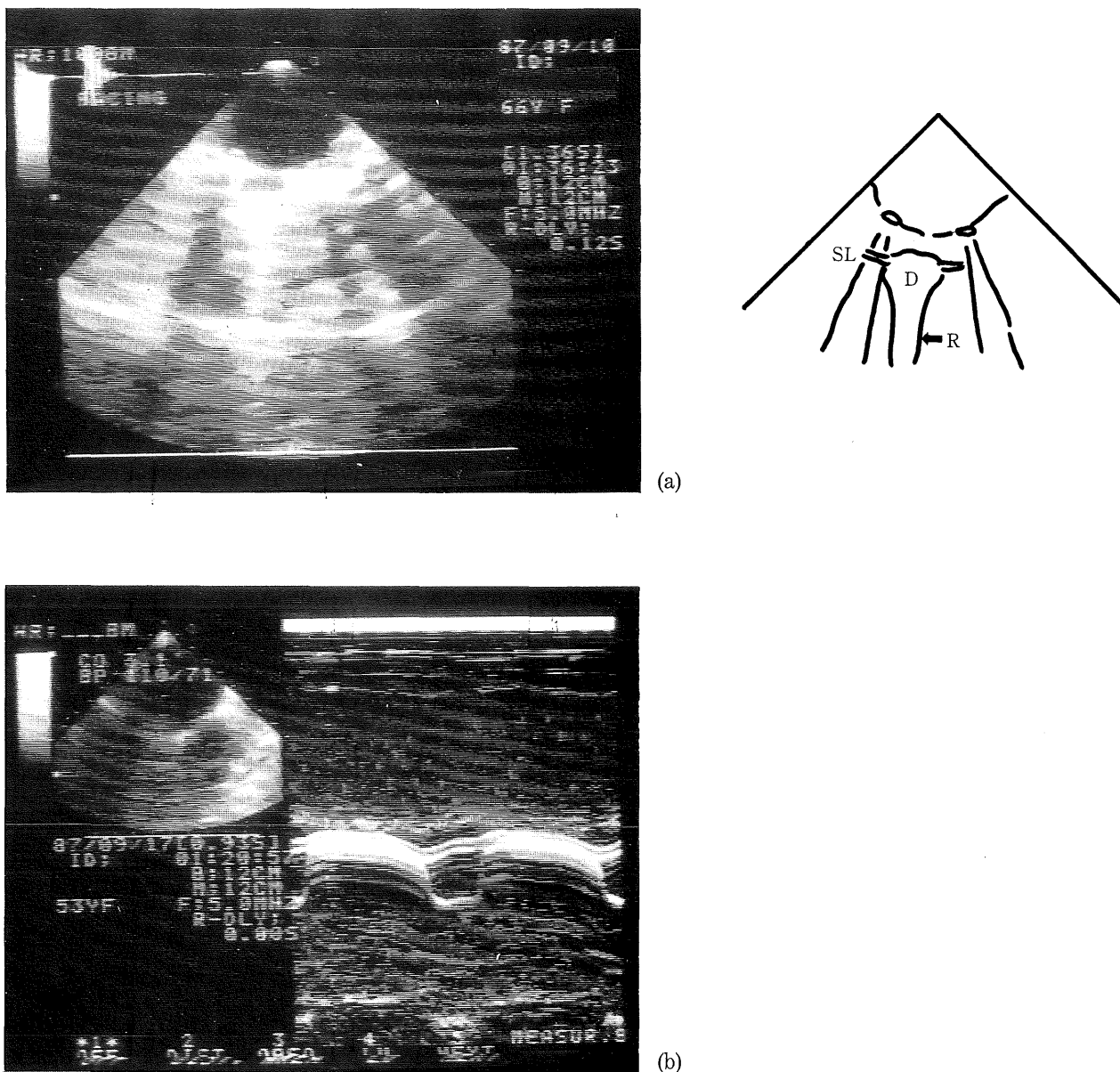


Fig. 4. Transesophageal echocardiogram showing the disc of a Bjork-Shiley prosthetic valve in the mitral position. (a) A two-dimensional echocardiogram of the disc with strong echo, side lobe, and reverberations (case 4). (b) An M-mode echocardiogram of the disc (case 5). D: disc, SL: side lobe, R: reverberations.

3b). The disc was recognized as a highly echogenic arched structure with side lobe and reverberations which showed rhythmical to-and-fro movement (Fig. 4a). M-mode scan of the disc showed various patterns according to the location and direction of the transducer (Fig. 4b).

Mitral regurgitant flow was demonstrated just after MVR in all cases with 2D-CD-TEE, although large v wave was not noted on the left atrial pressure tracing in any case. In most cases, the regurgitant image was modest and originated from just inside of the ring (Fig. 5), which was considered to be transvalvular leak. In case 4, the distribution of the regurgitant flow was large and originated from just outside of the ring (Fig. 6), which suggested paravalvular leak. In cases 1 and 5, very small paravalvular leak was noted.

On the other hand, conventional echocardiogra-

phy performed postoperatively could not detect paravalvular or transvalvular leakage in any case.

DISCUSSION

Patients with mitral valve prosthesis have pathological and functional mitral regurgitation (MR). Pathological MR is one of the most significant malfunctions of prosthetic valve. Although it is usually a later complication, it may occur earlier, even at operation, and it occurs at the valve itself (valvular leak) or around the sewing ring (paravalvular leak). Conventional echocardiography is now considered to be an essential technique for the evaluation of replaced valve⁴. M-mode echocardiography of the prosthetic valve in the mitral position shows various patterns in the Bjork-Shiley valve³ or the St. Jude valve². Two-dimensional echocardiography is not informative due to high

echogenicity of the valve, while Doppler echocardiography is recently proving to be a valuable examination⁴), especially in detecting MR⁵). However, conventional echocardiography from the transcutaneous approach can tell the abnormality only postoperatively and its intraoperative use is limited because it can interrupt the operative procedures.

In contrast, transesophageal echocardiography (TEE) can provide information continuously during the operation without interference on or interruption by surgery, thus is used now for monitoring of cardiac function or detecting intracardiac air^{6,7}). Two-dimensional (2D) TEE can provide clear views of the mitral valve and prosthetic valve through the left atrium. Using transesophageal 2D color Doppler echocardiography (2D-CD-TEE), regurgitant flow is also visualized just like a flame which flares up from around the sewing ring toward the echocardiographic probe. In this series, some advantages of TEE in observing mitral valve replacement (MVR) have been presented.

First, clear images of the prosthetic valves were obtained. Both outer and inner borders of the valvular ring were clearly noted, thus the origin of the regurgitant flow was detected. In most cases the origin of a flame was recognized just inside of the ring, thus the flame was considered to be leak of the permitted quantity due to mechanical construction of artificial valve. Prosthetic valve is originally designed to allow minor leak so that thrombus might be washed out from the surface of the valve. In case 4, however, the flame originated just outside of the ring that indicated paravalvular leak. In this case, two trials of replacement failed because the annular ring was so narrow and rigid that prosthetic valve could not be settled to the annulus. The third trial was successful, but the paravalvular leak was found with 2D-CD-TEE. It was likely due to organic damage of the annular ring after repeated sutures. The patient died of postoperative ischemic enterocolitis 20 days after the operation. However, there was not found any macroscopic valve dehiscence at necropsy. We have no idea other than that TEE could detect a very small regurgitation. In all other cases, TEE could visualize transvalvular leak, while it was not detected by postoperative evaluation of MR with conventional transthoracic echocardiography. This high sensitivity may be the second advantage of TEE. We think this is because the regurgitant flow is directed almost toward the transducer.

Thirdly, the greatest merit of TEE compared with conventional echocardiography is that it can provide much information during the operation. In case 4, we could not find any other data which indicated significant MR and finished the operation without further treatment.

In some cases the regurgitant flow reached the posterior wall of the left atrium (grade 4 by the

conventional grading with transthoracic echocardiography¹). Attention should be paid not to take the drainage flow of the pulmonary vein for the regurgitant flow because they are found closely. Origin of the flame should be clarified in estimating MR.

CONCLUSION

The mitral prosthetic valve and regurgitant flow was clearly visualized, using two-dimensional transesophageal echocardiography (2D-TEE) during the operation. We consider that the TEE may be a useful technique for detecting mitral regurgitation and differentiating paravalvular leak from valvular leak intraoperatively in patients undergoing mitral valve replacement.

(Received May 23, 1988)

REFERENCES

1. Adhar, G.C., Abbasi, A.S. and Nanda, N.C. 1985. Doppler echocardiography in the Assessment of Mitral Regurgitation and Mitral Valve Prolapse, p.42—50. *In* N.C.Nanda (ed.), Doppler echocardiography. Igaku-Shoin, New York.
2. Amann, F.W., Burckhardt, D., Hasse, J. and Graedel, E. 1981. Echocardiographic features of the correctly functioning St. Jude Medical valve prosthesis. *Am. Heart J.* 101: 45—51.
3. Douglas, J.E. and Williams, G.D. 1974. Echocardiographic evaluation of the Bjork-Shiley prosthetic valve. *Circulation* 50: 52—57.
4. Feigenbaum, H. 1986. Acquired valvular heart disease; Prosthetic valves, p. 319—345. *In* Echocardiography 4th edition. Lea & Febiger, Philadelphia.
5. Ferrara, R.P., Labovitz, A.J., Wiens, R.D., Kennedy, H.L. and Williams, G.A. 1985. Prosthetic mitral regurgitation detected by Doppler echocardiography. *Am. J. Cardiol.* 55: 229—230.
6. Konstadt, S.N., Thys, D., Mindich, B.P., Kaplan, J.A. and Goldman, M. 1986. Validation of quantitative intraoperative transesophageal echocardiography. *Anesthesiology* 65: 418—421.
7. Matsumoto, M., Oka, Y., Strom, J., Frishman, W., Kadish, A., Becker, R.M., Frater, R.W.M. and Sonnenblick, E.H. 1980. Application of transesophageal echocardiography to continuous intraoperative monitoring of left ventricular performance. *Am. J. Cardiol.* 46: 95—105.
8. Sellers, R.D., Levy, M.J., Amplatz, K. and Lellehei, C.W. 1964. Retrograde cardioangiography in acquired cardiac disease: technique, indications and interpretation of 700 cases. *Am. J. Cardiol.* 14: 437—447.