

## Prevention of Limb Ischemia in Surgical Patients by Intra-aortic Balloon Pumping

Taijiro SUEDA<sup>1)</sup>, Yuichiro MATSUURA<sup>1)</sup>, Hiroshi ISHIHARA<sup>1)</sup>, Yoshiharu HAMANAKA<sup>1)</sup>,  
Keiichi KANEHIRO<sup>1)</sup>, Saiho HAYASHI<sup>1)</sup>, Yoshiyuki MAEDA<sup>2)</sup> and Yoshio OHNO<sup>2)</sup>

1) *The First Department of Surgery, Hiroshima University School of Medicine, 1-2-3, Kasumi, Minami-ku, Hiroshima 734, Japan*

2) *Department of Cardiovascular Surgery, Chugoku Rosai Hospital, Hiro, Kure 737, Japan*

### ABSTRACT

Intra-aortic balloon pumping (IABP) was recently performed during the perioperative period in seven patients in whom balloon insertion was difficult because of vascular complication. Prophylactic measures for the prevention of limb ischemia were taken when the balloon was inserted. These measures included (1) balloon insertion through the femoral artery and continuous infusion of heparin into the femoral artery in three patients, (2) balloon insertion through the left femoral artery and femoro-femoral arterial crossover bypass in two patients, and (3) balloon insertion through the left common iliac artery and axillo-femoral bypass on the same side in two patients. Most patients recovered satisfactorily without any evidence of ischemia of the limbs either clinically or in serum biochemistry examination. One patient died of prolonged cardiac failure.

**Key words:** *Intra-aortic balloon pumping, Arteriosclerosis, Limb salvage*

Intra-aortic balloon pumping (IABP) is the most powerful method of circulatory assistance in acute myocardial infarction and cardiac failure following open heart surgery. However insertion of the balloon for pumping is often difficult in elderly patients with complicating arteriosclerotic obstruction (hereinafter "ASO"). Even when IABP balloon is successfully inserted, myonecrosis and other disorders of the lower limbs are occasionally experienced due either to arterial dissection or perforation at the time of balloon insertion or to thrombotic obstruction. Salvage of the limb through which IABP balloon is inserted is thus an important problem in the management of IABP patients. IABP balloon was inserted in seven patients with severe ASO of extremities over a 15-month period. None of the cases had experienced ischemic disorder in the limb. Measures taken for limb salvage are described.

### PATIENTS AND METHODS

The seven patients in whom IABP balloon insertion proved difficult are shown in Table 1. Their age ranged from 57 to 78 years with a mean of 67.1 years. The primary disorders were ischemic heart disease in five patients, dissecting aneurysm in one patient and aortic valvular disease in one patient. Aorto-coronary bypass surgery (CABG) was performed on all patients with ischemic heart disease and CABG with resection of left ventricular aneurysm in one patient and aortic valve replacement in one patient. Low cardiac output syndrome

(LOS) in three patients was the most frequent reason for IABP insertion. Arrhythmia and hypotension attributable to coronary spasm during and after the operation was the set of conditions in two patients and postoperative arrhythmia in another. One of these patients died of prolonged cardiac failure, even though IABP was functioning. Limb ischemia and other new vascular complications attributable to IABP balloon insertion were absent in six survivors.

The following prophylactic measures for prevention of limb ischemia were taken at the time of IABP balloon insertion.

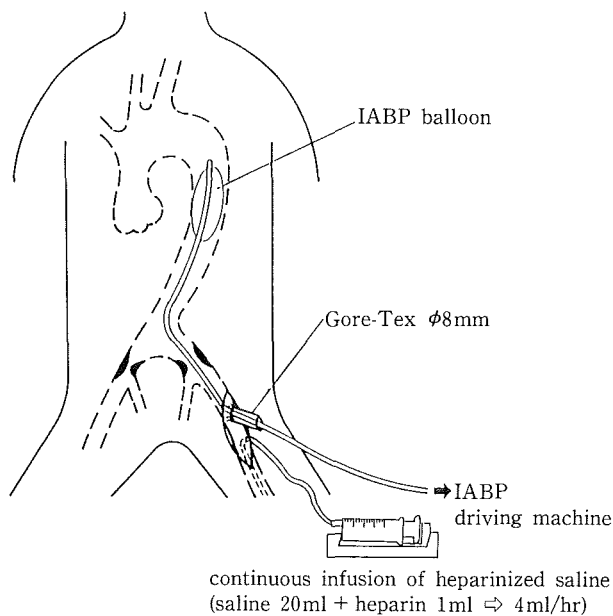
(1) Balloon insertion through the femoral artery and continuous infusion of heparin into the femoral artery (Fig. 1). This method was applied to patients with mild ASO disorders in the femoral artery used for balloon insertion, in whom thrombus formation could be expected even though blood flow in the lower extremity was preserved. This was performed in three patients.

(2) Balloon insertion through the femoral artery and femoro-femoral arterial crossover bypass (Fig. 2). This method was indicated for patients with marked ASO disorders in the femoral artery used for IABP balloon, in whom blood flow in the peripheral femoral artery was completely suspended after insertion of the balloon, but blood flow in the peripheral femoral artery of the other limb was preserved. This was performed on two patients, one of whom was lost immediately after the operation.

**Table 1.** Cases with IABP balloon insertion after cardiovascular surgery

case	sex	age	primary disease	operation	reasons for IABP insertion	method of IABP insertion	result
1. H.T.	M	62	OMI, angina	CABG	perioperative coronary spasm	left femoral arteriotomy + heparin infusion	alive
2. K.K.	M	63	OMI, angina	CABG	perioperative myocardial infarction	left femoral arteriotomy + heparin infusion	alive
3. J.K.	M	57	dissecting aneurysm (De Bakey IV)	prosthetic replacement	arrhythmia	left femoral arteriotomy + heparin infusion	alive
4. K.K.	M	67	AMI (post PTCA)	CABG	LOS	right femoral puncture + F-F bypass	alive
5. N.M.	F	72	aortic valve stenosis, angina	AVR + CABG	LOS	left femoral arteriotomy + F-F bypass	dead (LOS)
6. I.T.	M	71	left ventricular aneurysm, angina	LV aneurysmectomy + CABG	perioperative coronary spasm	left iliac arteriotomy + Ax-F bypass	alive
7. M.S.	M	78	aortic valve stenosis and regurgitation	AVR	LOS	left iliac arteriotomy + Ax-F bypass	alive

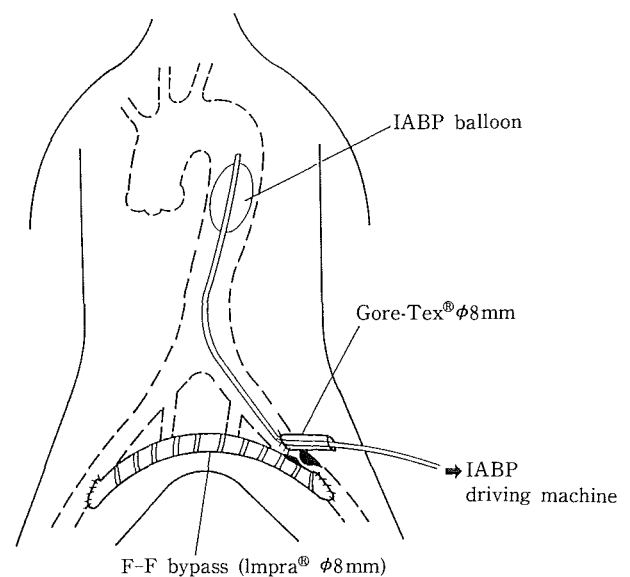
M: male F: female CABG: coronary artery bypass grafting OMI: old myocardial infarction AMI: acute myocardial infarction AVR: aortic valve replacement LOS: low cardiac infarction F-F: femoro-femoral Ax-F: axillo-femoral



**Fig. 1.** Balloon insertion method through the femoral artery.

Balloon is inserted through left femoral artery and heparin is infused continuously into the peripheral femoral artery.

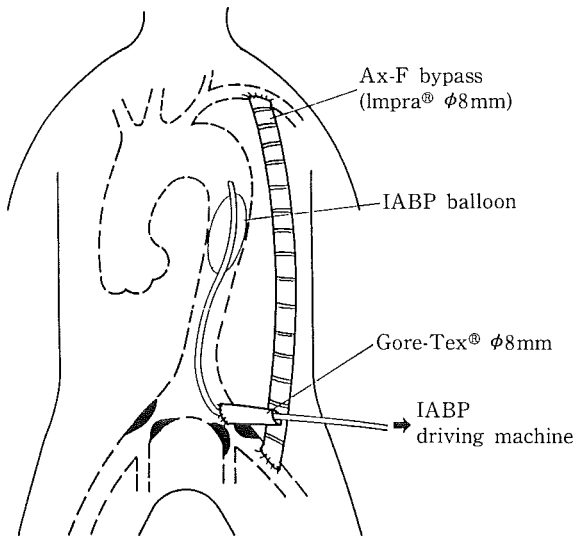
(3) Balloon insertion through the left common iliac artery and axillo-femoral arterial bypass on the same side (Fig. 3). This method was indicated for patients in whom balloon insertion through either femoral artery was impossible and who also had se-



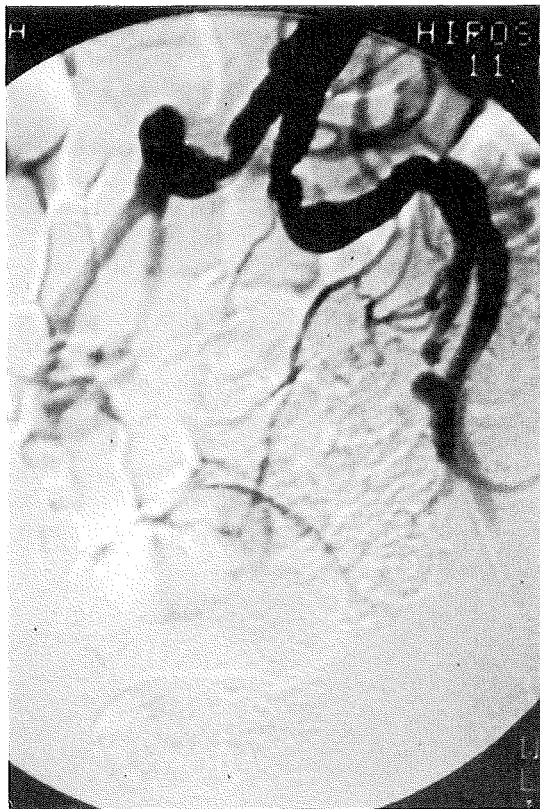**Fig. 2.** Balloon insertion method through the femoral artery and femoro-femoral crossover bypass.

Balloon is inserted through left femoral artery and femoro-femoral crossover bypass is made from right femoral artery to left femoral artery.

vere ASO at a high locus in the iliac artery, and for patients with stenosis and tortuosity of both common iliac arteries as shown in Fig. 4. This method was applied to two patients, with satisfactory results.



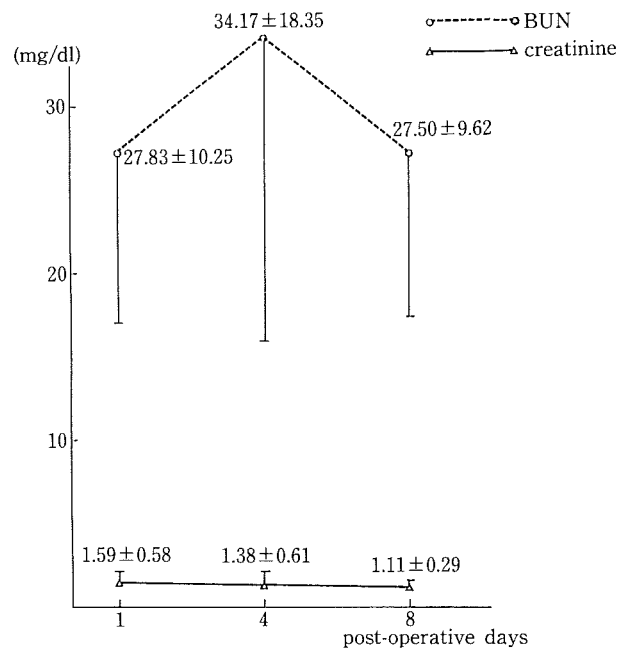
**Fig. 3.** Balloon insertion method through left common iliac artery and axillo-femoral bypass on the same side. Balloon is inserted through left common iliac artery and axillo-femoral grafting with Impra® is bypassed on the same side to maintain peripheral blood flow of left femoral artery.



**Fig. 4.** Arteriography of severe iliac arterial sclerosis. Stenosis and tortuosity of both common iliac arteries are observed. Balloon was inserted through left common iliac artery and axillo-femoral bypass was made on the same side in this case.

## RESULTS

The duration of balloon insertion in the above six patients was 24-168 hours with a mean of 92 hours.



**Fig. 5.** BUN and creatinine values after insertion of IABP.

BUN value increased slightly on the 4th. postoperative day but returned to the initial value on the 8th. Creatinine value did not change noticeably during the postoperative course.

Balloon insertion time was longer in those who had serious disorders of ASO and required arterial reconstruction of the lower limbs.

Limb ischemia such as finger necrosis and skin colour change in lower extremities was absent. Six patients survived without serious complications. One patient died resulting from severe cardiac failure, but limb ischemia due to balloon insertion was not encountered and arterial pulsation of the left limb was palpable until her death.

Serum biochemistry in the six survivors revealed that GOT level which was elevated on the first day after the operation returned to normal on the 8th day. CPK value which had risen remarkably immediately after the operation also decreased 4-8 days later. This increase of enzymes seemed to suggest normal ischemic damage to myocardium during operation. No significant elevation of BUN or creatinine level was observed postoperatively, nor was there any case of renal failure (Fig. 5). There were no laboratory findings suggesting prolonged myonecrosis of the lower limbs.

The author had experienced 2 cases of myonecrosis in the lower extremities with IABP balloon prior to these prophylactic procedures. These patients had died of renal failure and serious infection. In addition to these fetal complications, vascular accidents, such as thrombus formation and intimal injury, were experienced also. Limb salvage after insertion of IABP balloon seems to be crucial in the management of IABP.

### DISCUSSION

Since Kantrowitz first reported on the clinical application of IABP<sup>4)</sup>, this procedure has been used as a powerful method of circulatory assistance in acute myocardial infarction and severe cardiac failure following open heart surgery. The frequency of IABP use further increased, especially after development of a balloon catheter that could be inserted percutaneously. It became possible even for the cardiologist to undertake IABP insertion in CCU.

The increased indications for IABP have heightened the need for its use in elderly patients with severe atherosclerosis. Consequently, it is no longer uncommon for reports to be made on vascular complications at the time of IABP balloon insertion or on necrosis of the lower extremities due to arterial thrombosis in the limbs. IABP balloon insertion itself is difficult when the atherosclerosis is severe. According to McGabe et al<sup>6)</sup>, IABP balloon insertion was found to be difficult in as many as 27% of 100 patients, and in 21% of these patients IABP insertion was impossible though all possible measures were taken. According to the report of Goldberger et al<sup>2)</sup>, the frequency of complications in IABP insertion was 34% after percutaneous insertion and 9.6% after surgical insertion, indicating that complications develop far more frequently after percutaneous insertion. Isner et al<sup>4)</sup> reported that in 45 autopsied cases of death following IABP insertion, vascular complications were observed in 36%. This is a considerably higher frequency than in other reports<sup>3,4)</sup>. Among such complications, the most frequent was myonecrosis of the limbs due to arterial thrombosis. We should recognize anew the need for preservation of blood flow to the limb through which the balloon is inserted. Therefore, we carried out continuous infusion of heparin and bypass surgery with a prosthesis as prophylactic measures for the prevention of thrombus formation in the peripheral femoral artery.

Retrograde insertion through the ascending aorta<sup>5)</sup> and retrograde insertion through the left

axillary artery<sup>6)</sup> have been reported as methods of choice when IABP balloon insertion through the arteries in the lower extremities is impossible, but these methods cannot be recommended because the former, when complicated by infection, causes serious mediastinitis. Moreover, fixation of the balloon is difficult in the latter.

IABP balloon insertion may be more easily performed and the complications less frequent if improvements are made in the future to reduce the size of the balloon and the diameter of the catheter. Until such time, it will be necessary to take various measures to salvage the limb in which the IABP balloon is inserted.

(Received February 28, 1989)

(Accepted May 29, 1989)

### REFERENCES

1. **Bregmann, D. and Casarella, W.J.** 1978. Percutaneous intra-aortic balloon pumping: Initial clinical experience. *Ann. Thorac. Surg.* **29**: 153-156.
2. **Goldberger, M., Tabak, S.W. and Shah, P.K.** 1986. Clinical experience with intra-aortic balloon counterpulsation in 112 consecutive patients. *Am. Heart J.* **111**: 497-503.
3. **Isner, J.M., Steven, F., Virmani, R., Lawrinson, W. and Roberts, W.C.** 1980. Complication of the intra-aortic balloon counterpulsation device. Clinical and morphological observation in 45 necropsy patients. *Am. J. Cardiology* **45**: 260-265.
4. **Kantrowitz, A., Tjonnelland, S., Freed, P.S., Phillips, S.J., Butner, A.N. and Sherman, J.L.** 1968. Initial clinical experience with intraaortic balloon pumping in cardiogenic shock. *JAMA* **203**: 135-140.
5. **Lefemine, A.A., Kosowsky, F.B., Modoff, I., Black, H. and Lewis, M.** 1977. Results and complications of intra-aortic balloon pumping in surgical and medical patients. *Am. J. Cardiology* **40**: 416-419.
6. **McCabe, J.C., Abel, R.M. Subramanian, V.A. and Gay, W.A.** 1978. Complication of intra-aortic balloon insertion and counterpulsation. *Circulation* **57**: 769-774.