

Intracavitary Drainage Procedure for Giant Bullae in Compromised Patients

Rakesh Kumar VERMA, Masayuki NISHIKI, Masaki MUKAI, Tatsuyoshi FUJII,
Fumito KURANISHI, Shinkichiro YOSHIOKA, Minako OHTANI* and Kiyohiko DOHI

*The Second Department of Surgery, Hiroshima University, School of Medicine, Kasumi 1-2-3,
Minami-ku, Hiroshima 734, JAPAN*

* *Division of Emergency Medicine and Intensive Care Medicine, Hiroshima University, School of Medicine*

ABSTRACT

Two cases of giant bullae were treated by intracavitary suction and drainage procedure under local anesthesia because of the poor pulmonary function. After staged bullectomy, the patients returned to normal life.

The first case was admitted to our intensive care unit (ICU). Tube drainage was performed in the giant bulla of the left lung immediately after admission. One month after recovery from right heart failure and mediastinal shift to the right side, bullectomy was performed using linear stapler. The patient was discharged 20 days later.

The second case was admitted with severe dyspnea and bilateral giant bullae were noticed. We performed tube drainage for larger bulla of the left lung under local anesthesia. Two months later, bullectomy was performed on the right side, because the bulla on the left side became smaller and the general condition of the patient improved. The patient was discharged three months later on foot and has since been asymptomatic.

Giant bulla is a well-established clinical entity which includes abnormal dilatation of various parts of the tracheo-bronchial tree and other discrete sacs originating from the interstitial portion of the lung. Giant bullae are frequently associated with marked dyspnea and emphysematous symptoms. However, these symptoms depend upon various factors: size, location, valvular mechanism, condition of the contiguous lung parenchyma and the changes that may take place in the intrathoracic pressure.

Key words: *Tube drainage, Giant bulla, Poor pulmonary function*

CASE REPORT

A wide variety of surgical procedures have been advocated in an attempt to excise the bulla in order to allow any underlying compressed and potentially lung tissue to reexpand. The plication-excision method, originated by Naclerio and Langer⁴⁾ or intracavitary suction and drainage by Monaldi³⁾. These are currently the most popular operation.

We reported the successful treatment of two cases of giant bullae by drainage procedure on an emergency basis followed by staged operation of bullectomy.

Case 1.

A 69-year-old salaried man with a smoking history of 60—80p/day for 30 years was brought to our hospital by ambulance in a stuporous state. History revealed that he had slight dyspnea on exertion for the last years. On November 17, 1990 he noticed edema of the eyelid, and the dyspnea suddenly increased. On November 27th morning, he

had a bout of severe dyspnea with cyanosis and the consciousness level deteriorated. On admission, an emergency endotracheal intubation had to be performed to revive the patient. Chest X-ray showed a giant bulla (23 × 10 cm) in the left lung with remarkable shift of mediastinum to the right side (Fig. 1).

The vital parameters at the time of admission were as follows: BP was 140—70 mmHg, PR 80/m, RR 26/m, BT 36.3°C. PaO₂ level, however, showed only 29.2 torr (normal = 80 ± 5 torr) and PaCO₂ 68.4 torr (normal = 40 ± 5 torr). Under local anesthesia, a 5 cm-long skin incision was made and the chest wall was opened through the 4th intercostal space at the anterior axillary line. A 3-way balloon catheter (20 Fr) was inserted into the giant bulla using purse-string suture for the fixation of the tube. With this treatment, the patient recovered progressively and the giant bulla became smaller (Fig. 2). On 25th December, bullectomy was

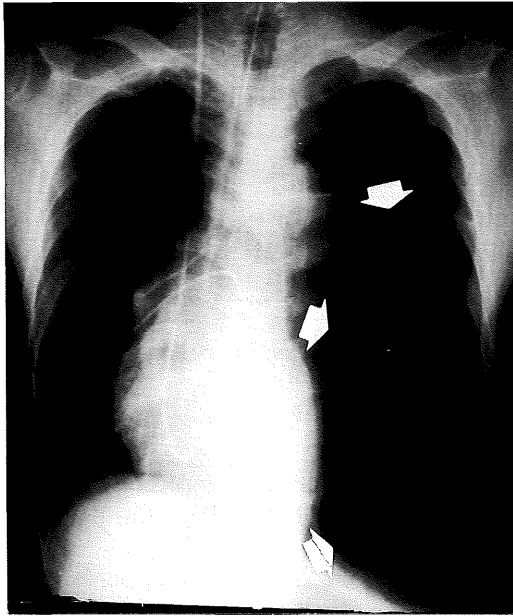


Fig. 1. Case 1. Left lung occupied with giant bulla just above the diaphragma (white arrows) and mediastinum shadow shift to right.

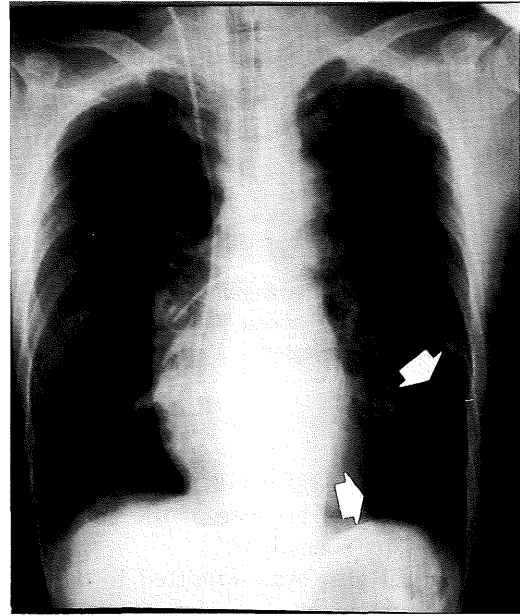


Fig. 2. Case 1. After drainage, bulla became smaller (white arrows) and mediastinal shift recovered to normal position.

Table 1. Respiratory function and arterial gas analysis of case 1

	PaO ₂	PaCO ₂	pH	SAT	VC(ml)	%VC	%FEV _{1.0}
on admission (Nov-27)	29.2	68.4	7.308	—	—	—	—
before 2nd OP (Dec-13)	58.4	39.0	7.453	91.3%	—	—	—
after 2nd OP (Jan-11)	70.0	42.5	7.420	95.5%	1870ml	54%	43%
recent data (Mar-01)	91.9	34.9	7.431	96.5%	2240ml	68%	47%

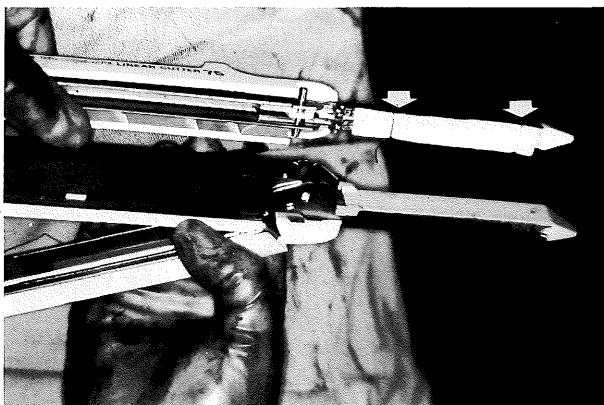


Fig. 3. Case 1. Stapler is covered with tailored Vicryl mesh and fixed with silk thread tie (white arrows).

performed using linear stapler. The bullectory line was covered with Vicryl mesh in order to prevent any air leakage (Fig. 3). Pre- and post-operative lung function data are showed in Table 1. The patient was discharged on January 15, 1991 and has since returned to normal life.

Case 2.

A 67-year-old retired public official employee, with a smoking history of 20p/day for 50 years, was in a good health with no significant family or past history. Three years ago he began to notice short-

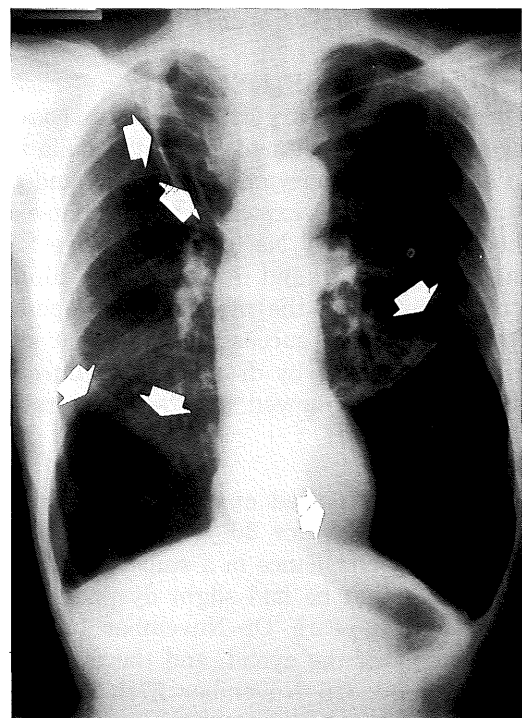


Fig. 4. Case 2. Three giant bullae in bilateral lungs. Largest is located above the left diaphragm. Other two are seen in right lung (white arrows).

Table 2. Respiratory function and arterial gas analysis of case 2

	PaO ₂	PaCO ₂	pH	SAT	VC(ml)	%VC	%FEV _{1.0}
before 1st OP (Nov-20)	74.0	39.4	7.398	93.7%	1890ml	54%	38%
after 1st OP (Dec-14)	64.5	44.0	7.404	92.2%	2040ml	59%	52%
before 2nd OP (Jan-21)	85.7	35.4	7.401	95.2%	2610ml	75%	48%
after 2nd OP (Feb-19)	82.6	36.0	7.411	96.2%	2260ml	65%	46%
recent data (Mar-22)	93.9	34.5	7.431	96.5%	2470ml	73%	49%

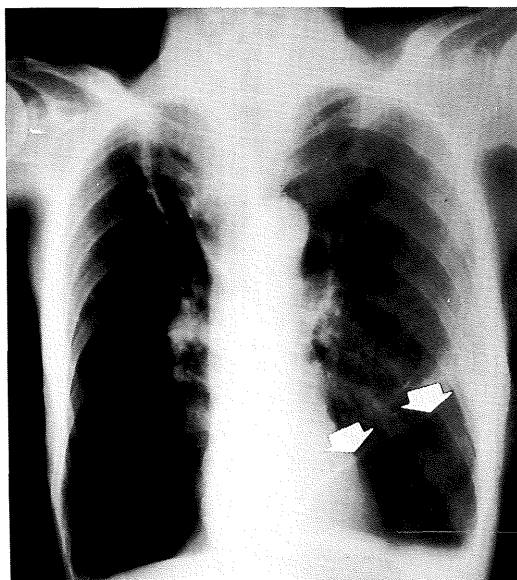


Fig. 5. Case 2. Left lung bulla almost disappeared with a small space of pneumothorax still remaining

ness of breath on climbing the stairs. In September 1989, he had a cold and since then his breathing has progressively worsened. In October 1990, he was unable to walk more than ten meters at a normal speed. He visited our outpatient department and was admitted on November 19, 1990. Chest X-ray showed giant bullae in both lungs in the lower segment and one in the right apical region (Fig. 4).

PaO₂ was 74.0 torr and PaCO₂ 39.4 torr. Vital capacity, % vital capacity and % FEV_{1.0} were 1890 ml, 54% and 38% respectively (Table 2). Considering his age and poor lung function, we chose intracavitary drainage procedure (as described in case 1) for the largest bulla (10 × 13 cm), located in the left pulmonary base. A small amount of air leakage persisted for ten days but after injection of 3 ml of fibrin glue through the catheter, air leakage stopped and the largest bulla at the base of left lung almost disappeared (Fig. 5). His lung function and daily activity rapidly improved (Table 2). On January 29, 1991, bullectomy of the right lung was performed on an elective basis under general anesthesia. He was discharged from hospital on February 24 and since then the patient has led a normal life.

DISCUSSION

The surgical treatment of bullous disease was uncommon until the middle of this century due to the

high risk of operative treatment. In 1947, Naclerio and Langer described the standard method of bullectomy and plication without lobectomy⁴. At the same time (1947), Monaldi demonstrated that the intracavitary suction and drainage method relieves tension in a tuberculous cavity³. Many researchers have followed and subsequently modified this method for the management of the patients with severely impaired lung function, coupled with the advantage of non-removal of the lung tissue². Recently, additional technical ideas have emerged. Kuwabara checked the point of air leakage by fiber-optic bronchoscope through the thoracic tube and biopsy could be done through the channel of the scope, if necessary¹. Uyama applied the drainage procedure to a giant bulla in a patient with severe emphysema and pneumoconiosis, using fibrin glue and irritant fluid such as OK-432 in the cyst. This led to a subsequent diminution in the size of the giant bulla with a progressive improvement in lung function and recovery from dyspnea⁶. Oizumi presented the staged operation for lung cancer associated case. First, drainage operation was performed for the left pulmonary bulla followed by occlusion method, using fibrin glue and OK-432 through the drainage tube. The injection of occlusion materials was also given simultaneously through the endotracheal tube using fiber-optic bronchoscope for selective sites. After improvement in the lung function, resection of the right lung cancer and pneumorrhaphy were performed successfully without a recurrence for ten months⁵.

In these circumstances, our staged planning for surgical treatment would be initially recommended for the compromised patient as an emergency rescue to improve lung function followed by elective operation.

(Received May 1, 1991)

(Accepted July 22, 1991)

REFERENCES

1. Kuwabara, M., Taki, T., Hatakenaka, R. and Ikeda, S. 1980. The surgical treatment of bullous emphysema. A new method for management of giant bulla. *Bronchopneumologie* 30: 202-211.
2. Macarthur, A.M. and Fountain, S.W. 1977. Intracavitary suction and drainage in the treatment of emphysematous bullae. *Thorax* 32: 668-672.
3. Monaldi, V. 1947. Endocavity aspiration: Its practical application. *Tubercle*. 28: 223-228.
4. Naclerio, E.A. and Langer, L. 1947. Pulmonary

- cysts: Special reference to surgical treatment of emphysematous blebs and bullae. *Surgery* **22**: 516-524.
5. **Oizumi, H., Hoshi, E., Aoyama, K., Yuki, K., Murai, K., Fujishima, T. and Washi, M.** 1990. Surgery of giant bulla with tube drainage and bronchofiber-optic bronchial occlusion. *Ann. Thorac. Surg.* **49**: 824-825.
 6. **Uyama, T., Monden, Y., Harada, K., Kimura, S. and Taniki, T.** 1988. Drainage of giant bulla with balloon catheter using chemical irritant and fibrin glue. *Chest* **94**: 1289-1290.