

Superficial Sylvian Veins as Landmarks for Operation of Middle Cerebral Artery Aneurysms

Tetsuji INAGAWA

Department of Neurosurgery, Shimane Prefectural Central Hospital, Izumo, Japan

ABSTRACT

A retrograde approach to aneurysms located at the middle cerebral artery bifurcation which uses the superficial Sylvian veins as landmarks is described. Fifty patients with 51 aneurysms were operated on using this technique. This method made it easier for surgeons to decide where to enter the Sylvian fissure for dissection of the middle cerebral artery branches and to secure the parent artery.

Key words: *Middle cerebral artery aneurysm, Cerebral angiography, Superficial Sylvian vein, Neurosurgical technique*

We can broadly classify two approaches to aneurysms of the middle cerebral artery (MCA): following either the M1 segment of the MCA distally to the aneurysm^{3,5,6,8,9)} or one of its branches proximally to the aneurysm^{2,4,9)}. In the first approach, it is almost always possible to secure the afferent artery prior to aneurysm exposure. However, this has the disadvantage that it is frequently necessary to retract the frontal lobe firmly for an extended period. In the second approach, potentially dangerous retraction can be avoided, but has a shortcoming in that the tip of the aneurysm is encountered first before proximal control of the afferent vessel can be secured.

Usually, the superficial Sylvian veins run along the surface of the Sylvian fissure; i.e., they run in close vicinity to the aneurysms located at the MCA bifurcation. There is, however, no report describing the relationship of the superficial Sylvian veins to the MCA bifurcation aneurysms. This paper discusses an approach to the MCA bifurcation aneurysms by using the superficial Sylvian veins as landmarks in order to dissect the Sylvian fissure distally at the same time securing the parent artery.

TECHNIQUE

Patients with MCA bifurcation aneurysms underwent stereoscopic, magnification, and serial cerebral angiography with their heads placed in the operating position; that is, with the head turned about 30 degrees away from the side of the aneurysm and tilted slightly backward. By tracing the superficial Sylvian veins of the venous phase on the arteriogram, a three dimensional picture of the surgical

field including the superficial Sylvian veins as well as the entire aneurysmal complex could be investigated. Patients with MCA bifurcation aneurysms were classified into three types according to the relationship between their superficial Sylvian veins and the projection of the MCA aneurysms (Fig. 1). The directions in which the overlying arachnoid is cut and the arteries to be dissected are shown in Fig. 1.

1) Type I

In Type I, the arachnoid of the Sylvian cistern is opened on the frontal lobe side of the superficial Sylvian veins, and dissection to expose the superior trunk of the MCA is commenced. The superior trunk is then followed proximally toward the M1 segment.

This type is subdivided into Type I-A and Type I-B. In Type I-A, the aneurysms project to the temporal side at the operating position. In Type I-B, the aneurysms do not project distally to either the temporal or to the frontal sides, and the superficial Sylvian veins cover the frontal side of the aneurysms. The parent artery is not usually difficult to secure in Type I.

2) Type II

In Type II, the arachnoid incision is commenced on the temporal lobe side of the superficial Sylvian veins. Dissection exposes the inferior trunk of the MCA which is then followed proximally toward the M1 segment.

This type is subdivided into Type II-A and Type II-B. In Type II-A, the aneurysms project to the frontal side. In Type II-B, the aneurysms do not project distally either to the temporal or to the frontal sides, and the superficial Sylvian veins cover

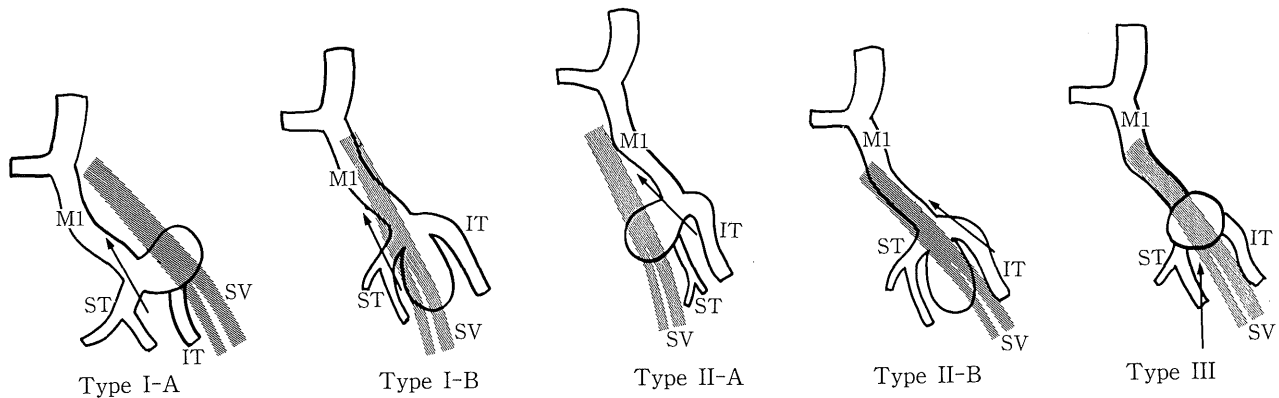


Fig. 1. Classification of middle cerebral artery (MCA) bifurcation aneurysms according to the relationship between the superficial Sylvian veins and the projection of the aneurysm seen in oblique serial angiography performed by the head turned about 30 degrees away from the lesion. Schematic representation is shown as the right sided aneurysm. The arrows indicate the directions of cutting the arachnoid overlying the Sylvian fissure and dissecting the arteries.

IT: inferior trunk of MCA, M1: M1 segment of MCA, ST: superior trunk of MCA, SV: superficial Sylvian vein.

the temporal side of the aneurysms. In Type II, if the arachnoid incision is started on the frontal lobe side, the inferior trunk under the superficial Sylvian veins should be inspected first.

3) Type III

In Type III, the fundus of the aneurysms projects directly toward the surface of the Sylvian fissure, i.e., the superficial Sylvian veins. In this type, the arachnoid incision can be carried out on either side of the superficial Sylvian veins. However, the arachnoid should not be incised beyond the aneurysms. Either the superior or inferior trunk is followed proximally toward the bifurcation, and the M1 segment of the MCA is inspected and secured beneath the aneurysm. If necessary, the head may be rotated further away from the side of the lesion.

In all types of aneurysms, dissection of the Sylvian fissure is begun approximately 2 centimeters distally to the aneurysm. Sometimes the superficial Sylvian veins may be spared apart to expose the Sylvian fissure. In most cases, the prechiasmatic and carotid cisterns are not opened initially. Once the M1 segment of the MCA and the aneurysm are clearly identified, cerebrospinal fluid at these cisterns may be evacuated, if necessary. Dissection of the entire aneurysmal complex and neck clipping are performed. The veins crossing the Sylvian fissure must be preserved as much as possible.

RESULTS

Our series included 146 cases with MCA aneurysms over a 10 year period. During the 5 year period from September 1983 to December 1988, surgery was performed on almost half of these MCA aneurysms by using stereoscopic, magnification, and serial cerebral angiography. The angiograms of 50 patients with a total of 51 MCA bifurcation aneurysms were studied to classify them into the types described above. Nine aneurysms

were unruptured, and the aneurysms originating from the M1 segment of MCA were excluded. Type I was found in 37 patients (73%) with 23 in Type I-A and 14 in Type I-B. Type II was found in 7 patients (14%) with 4 in Type II-A and 3 in Type II-B. Type III was found in 7 patients (14%). There was no case of premature rupture during surgery.

DISCUSSION

Since MCA bifurcation aneurysms are situated very close to the brain surface neck clipping of these aneurysms is generally not difficult for experienced surgeons. However, prior knowledge of the relationship of superficial Sylvian veins to aneurysms and to the main branches of the MCA, especially in patients with large or giant aneurysms, can be helpful to beginning surgeons. Actually, this technique was developed when the present author was just beginning in aneurysmal surgery as a guide to the surgical procedure.

In Type I aneurysms, if the surgeon is familiar with the pattern of division of the main trunk of the MCA, a venogram is not always necessary. In Type II aneurysms, a transtemporal approach^{1,7)} may also be preferred. The present technique is not, however, appropriate for small M1 segment aneurysms because the superficial Sylvian veins are somewhat distant from the M1 segment of MCA. Most neurosurgeons advocate the evacuation of cerebrospinal fluid to relax the brain at the beginning of the operation^{3,5,8,9)}. However, in this series, the basal cisterns have not usually been opened initially because it is easier to dissect the Sylvian fissure when it is filled with cerebrospinal fluid. The technique of using the superficial Sylvian veins as landmarks, a retrograde approach to the MCA bifurcation aneurysms facilitates the decision about where to enter the Sylvian fissure for dissection of MCA branches and to secure the parent artery.

Further, it offers the advantages of minimal brain retraction and minimal manipulation.

(Received December 5, 1990)

(Accepted May 2, 1991)

REFERENCES

1. **Heros, R.C., Ojemann, R.G. and Crowell, R.M.** 1982. Superior temporal gyrus approach to middle cerebral artery aneurysms: technique and results. *Neurosurgery* **10**: 308-313.
2. **Norlén, G. and Olivecrona, H.** 1953. The treatment of aneurysms of the circle of Willis. *J. Neurosurg.* **10**: 404-415.
3. **Peerless, S.J.** 1974. The surgical approach to middle cerebral and posterior communicating aneurysms. *Clin. Neurosurg.* **21**: 151-165.
4. **Rand, R.W.** 1978. Microneurosurgery in cerebral aneurysms, p.311-324. *In* R.W. Rand (ed.), *Microneurosurgery*, 2nd ed. C.V. Mosby, St. Louis.
5. **Rhoton, A.L. Jr., Saeki, N., Perlmutter, D. and Zeal, A.** 1979. Microsurgical anatomy of common aneurysm sites. *Clin. Neurosurg.* **26**: 248-306.
6. **Robinson, R.G.** 1971. Ruptured aneurysms of the middle cerebral artery. *J. Neurosurg.* **35**: 25-33.
7. **Shephard, R.H.** 1979. Operation for aneurysms of the middle cerebral artery, p.252-257. *In* L. Symon (ed.), *Operative surgery. Fundamental international techniques*, 3rd ed. Butterworths, London/Boston.
8. **Suzuki, J., Yoshimoto, T. and Kayama, T.** 1984. Surgical treatment of middle cerebral artery aneurysms. *J. Neurosurg.* **61**: 17-23.
9. **Yasargil, M.G.** 1984. p.124-164. *Microneurosurgery*. vol 2, George Thieme Verlag, Stuttgart.