

## WPW Syndrome Complicated by Another Cardiac Disorder

Taijiro SUEDA, Yuichiro MATSUURA, Hiroshi ISHIHARA, Yoshiharu HAMANAKA,  
Hiroo SHIKATA, Yasushi NAKASHIMA, Saiho HAYASHI, Hiroshi NAKAGAWA\*,  
Takuji KAWAGOE\*, Yukiko TSUCHIOKA\* and Mitsushi OKAMOTO\*

*The First Department of Surgery, Hiroshima University School of Medicine,*

*\* The First Department of Internal Medicine, Hiroshima University School of Medicine;  
Kasumi 1-2-3, Minami-ku, Hiroshima 734, Japan*

### ABSTRACT

During the past 28 months, 16 cases of WPW syndrome were operated on at Hiroshima University Hospital. Two cases were complicated by other cardiac disorders which accelerated tachycardia, making diagnosis difficult. One of these cases showed serious mitral regurgitation, due to infective endocarditis and the patient suffered cardiac failure accompanied by paroxysmal tachycardia not responsive to medical therapy or cardioversion. A complex rhythm with atrial fibrillation and antegrade conduction rhythm through the accessory pathway made diagnosis and therapy quite difficult. The condition of the other patient was associated with myocardial bridging which caused angina pectoris during paroxysmal tachycardia. Myocardial scintigraphy showed myocardial ischemia in the antero-lateral area of the left ventricle. In the former case, mitral valve replacement and interruption of the accessory pathway were undergone simultaneously. In the latter case, myotomy of the muscle on segment 7 was conducted, following interruption of the accessory pathway.

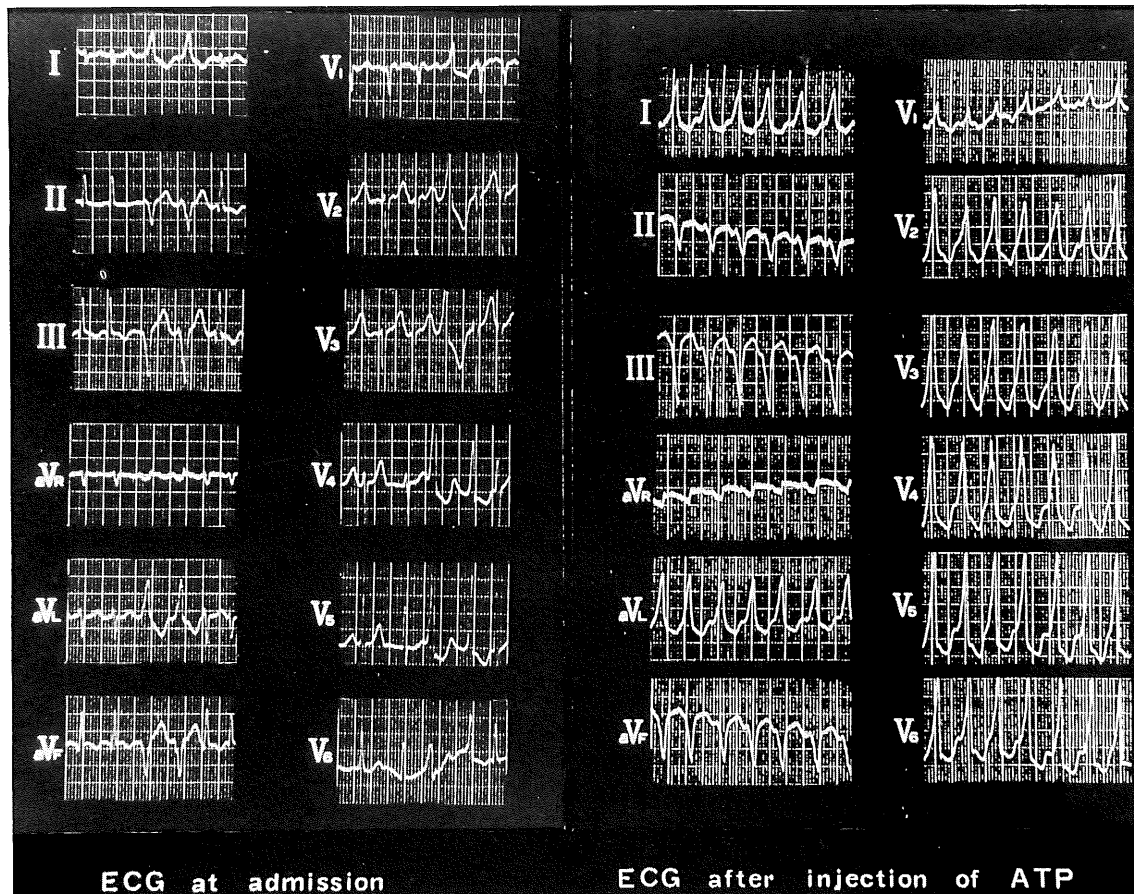
**Key words:** *WPW syndrome, Infective endocarditis, Myocardial bridging*

Surgical treatment for WPW syndrome was introduced by Sealy<sup>6)</sup> and Iwa<sup>3)</sup>. Progress in electrophysiological study and technical improvement of open heart surgery, including cardioplegia, have made easier the surgical treatment of WPW syndrome. A recent report describes surgery for a case of multiple WPW syndrome and a case accompanied by another cardiac disease. Misaki<sup>3)</sup> found cases of WPW syndrome accompanied by Ebstein anomaly and tricuspid atresia, but other cardiac disorders, such as valvular disease and ischemic heart disease, are rarely associated with WPW syndrome. This report describes surgery for WPW syndrome, particularly in cases complicated by another rare cardiac disorder. During the recent 28 months, 16 cases of WPW syndrome were operated on at Hiroshima University Hospital. Two of these cases were accompanied by another rare cardiac disorder which accelerated tachycardia and masked clinical symptoms. The electrophysiological and angiographic findings were shown to warrant examination.

### CASE 1

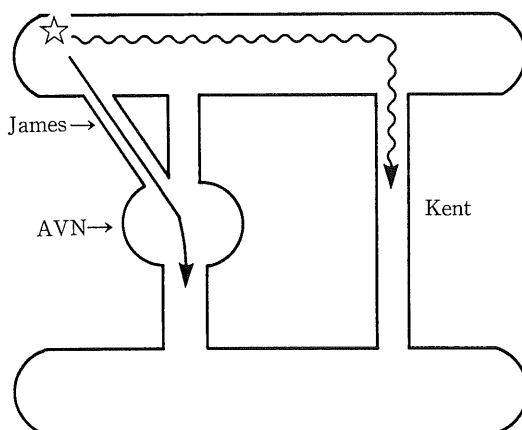
A 56-year-old woman, a housewife, collapsed at work on December 5 1988. Atrial fibrillation and cardiomegaly were indicated by ECG and chest X-P. She was given anti-arrhythmic drugs and cardioversion, but these were not effective. Retrospec-

tively, she had had an episode of high fever and cardiac failure 10 years ago and had complained sometimes of tachycardia in spite of taking medication for this condition. She was admitted to our hospital on December 13 owing to intractable atrial fibrillation and cardiac failure. ECG on admission showed atrial fibrillation and arrhythmia with a wide QRS wave (Fig. 1a).  $\Delta$  wave could not be found by ECG at the sinus rhythm and thus arrhythmia with wide QRS waves at atrial fibrillation was diagnosed as aberrant conduction. However, digitalis and anti-arrhythmic drugs failed to improve the tachycardia. ECG after injection of adenosine triphosphate (ATP) showed ventricular tachycardia owing to antegrade conduction of the accessory pathway, thus indicating WPW syndrome (Fig. 1b). Electrophysiological study showed normal sinus node function, a fasciculated conduction pathway as in the case of a James bundle (AH conduction time 50 msec, HV conduction time 50 msec) in the AV node, and an accessory conduction pathway (Kent bundle) through the antegrade pathway only in the left-posterior portion. The refractory times of the Kent and James bundle were the same. We thought the pattern of atrio-ventricular conduction of this case to be in as Fig. 2. Echocardiogram and left ventriculography showed massive mitral regurgitation (IV grade) and prolapse of the anterior mitral leaflet, while vegetation was not clear. Intraopera-



**Fig. 1.** Electrocardiogram of case 1

ECG on admission (Fig. 1a) showed atrial fibrillation and arrhythmia with wide QRS wave. After injection of adenosine triphosphate (ATP), ECG showed ventricular tachycardia owing to antegrade conduction of the accessory pathway (Fig. 1b).



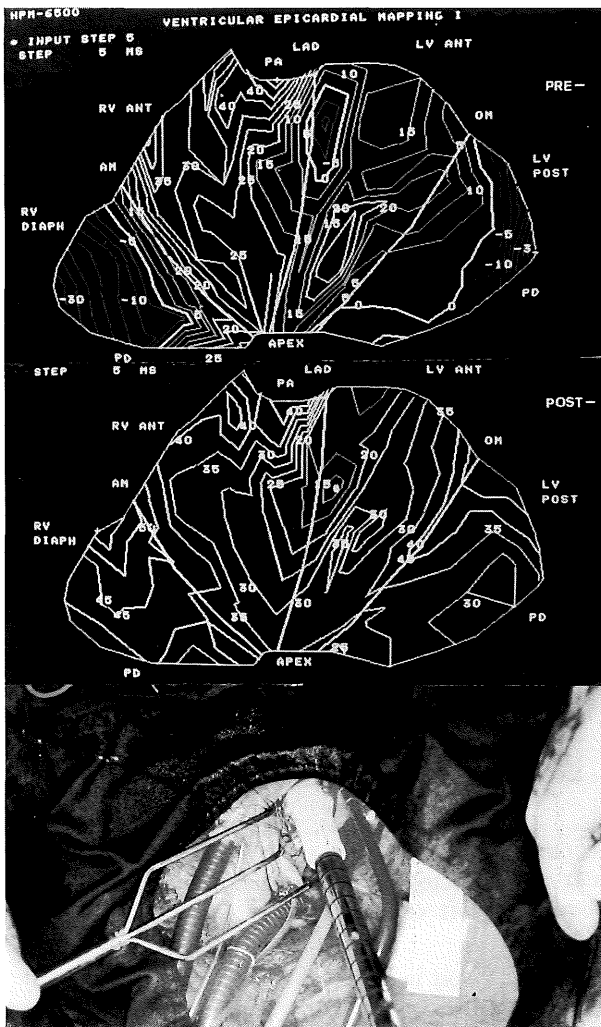
**Fig. 2.** The pattern of atrio-ventricular conduction. The conduction time of AV node is short owing to the fasciculated conduction pathway (James bundle) and the accessory conduction pathway is in the left posterior portion of the AV groove.

tive epicardial mapping indicated an accessory pathway in the left-posterior portion of the posterior descending groove. Following interruption of the Kent bundle, the conduction pattern became normal (Fig. 3). The mitral valve was thickened, the

chordae elongated, and part of the anterior leaflet was perforated. These findings indicated that the etiology of the damage to the mitral valve was possibly infective endocarditis. Mitral valve replacement preserving the posterior mitral leaflet was conducted. The postoperative course was uneventful and the patient is well without the need for arrhythmic drugs.

## CASE 2

A 31-year-old male, an engineer, had complained of tachycardia and chest discomfort since 1972. An electrocardiogram indicated WPW syndrome (type A). He suffered from paroxysmal tachycardia for 40 min and experienced chest pain in September 1989. He consulted our hospital due to tachycardia and chest discomfort. Electrical mapping during PSVT showed an accessory conduction pathway in the left lateral portion. Both antegrade and retrograde conduction could pass through this pathway, and the refractory period was 300 msec in the former and 320 msec in the latter. Coronary cineangiography indicated that the left anterior descending artery was narrow (over 90%) in systole and that the caliber dilated in diastole during PSVT. Coronary stenosis was conducted for my-



**Fig. 3.** Intraoperative epicardial mapping and operative findings

Preoperative mapping showed the accessory conduction pathway located in the left-posterior position (Fig. 3-a). After interruption of the pathway, the conduction pattern became normal (Fig. 3-b). Mitral valve was prolapsed and partially perforated, thus indicating infective endocarditis as the etiology of mitral regurgitation (Fig. 3-c).

ocardial bridging during tachycardia. A myocardial scintigram during PSVT indicated myocardial ischemia in the antero-septal portion of the left ventricle, in which the left anterior descending artery was stenotic by myocardial bridging (Fig. 4). During operation, myotomy against the supraarterial muscle on LAD seg.7 was performed under extracorporeal circulation with core cooling, and after cardioplegic arrest, the accessory pathway in the postero-lateral wall of the left atrium was interrupted through an endocardial approach. Intraoperative epicardial mapping before interruption of Kent bundle showed an accessory pathway (Kent bundle) in the postero-lateral portion of the atrio-ventricular groove preoperatively. After interruption of the accessory conduction bundle, the conduction pattern was restored to normal conduction. Thallium scintigram taken during exercise showed

the distribution of Thallium uptake to be uniform, indicating no ischemia in the antero-lateral portion of the left ventricle. Postoperative coronary cineangiography at high frequent atrial pacing did not show coronary arterial stenosis in LAD seg.7 during systole and diastole (Fig. 5). This patient is well and shows no need for arrhythmic drugs postoperatively.

## DISCUSSION

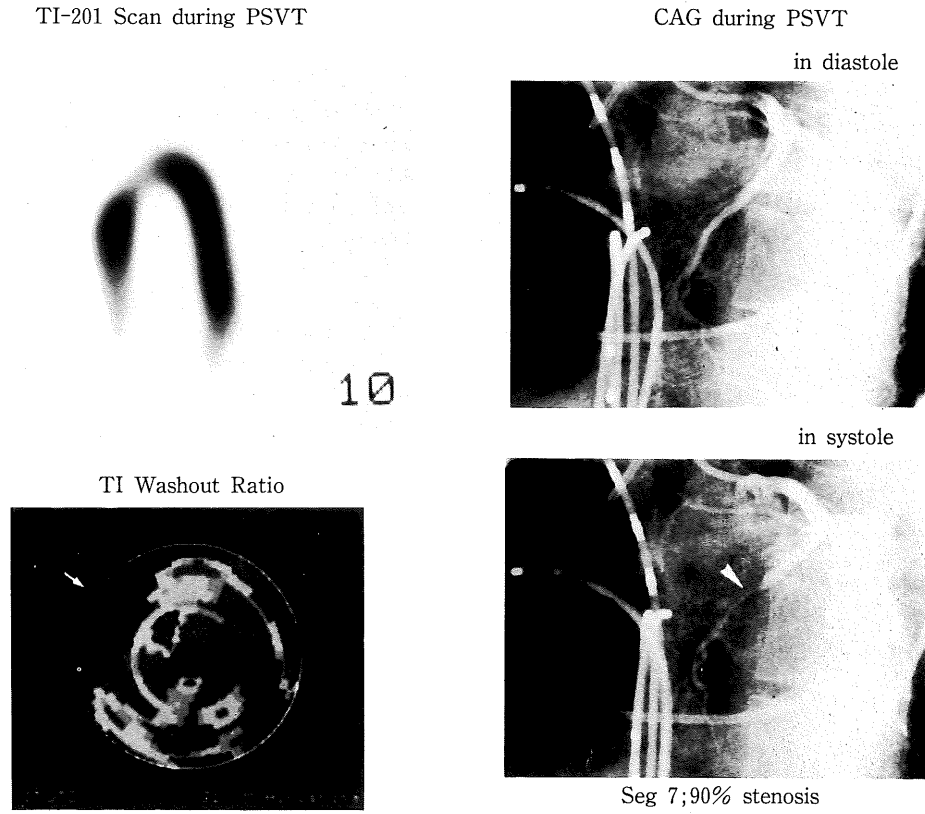
For the WPW syndrome associated with another cardiac disorder, other operation conducted at the same time for valvular disease is quite rare<sup>3</sup>. Most valvular diseases are associated with rheumatic heart disease, and valve replacement and/or commissurotomy are standard methods for the valvular region. Infective endocarditis with WPW syndrome is also very rare. Atrial fibrillation and flutter frequently occur together as a therapeutic problem of WPW syndrome accompanying valvular disease and atrial fibrillation involves antegrade conduction of an accessory pathway. Digitalis cannot stop such arrhythmia and other antiarrhythmic drugs impair cardiac function<sup>4</sup>. In the present case, the accessory pathway had a slow conduction time and there was also fasciculating pathway of AV node (suspected James bundle). Since preoperative ECG during sinus rhythm showed shortening of the PQ interval and narrow QRS waves without  $\Delta$  waves and changed to ECG with wide QRS as in the case of ventricular tachycardia during atrial fibrillation, the precise diagnosis of arrhythmia was difficult until intraoperative mapping was carried out.

Myocardial bridging causes constriction of the coronary artery during systole. The degree of narrowing of the left anterior descending artery during systole was severe (greater than 75%), moderate (50 to 75%), or mild (less than 50%)<sup>5</sup>. When tachycardia is greater than 120 beats/min, coronary blood flow during diastole decreases to 50%, and the systolic flow ratio increases. In severe myocardial bridging, tachycardia is associated with decreased systolic flow/total flow ratio, increased duration of systole, lag in diastolic flow, and functional deterioration<sup>2</sup>. Functional abnormalities by flow discrepancies in tachycardia at more than 150 beats per minute caused by WPW syndrome may possibly explain the symptoms in the present case.

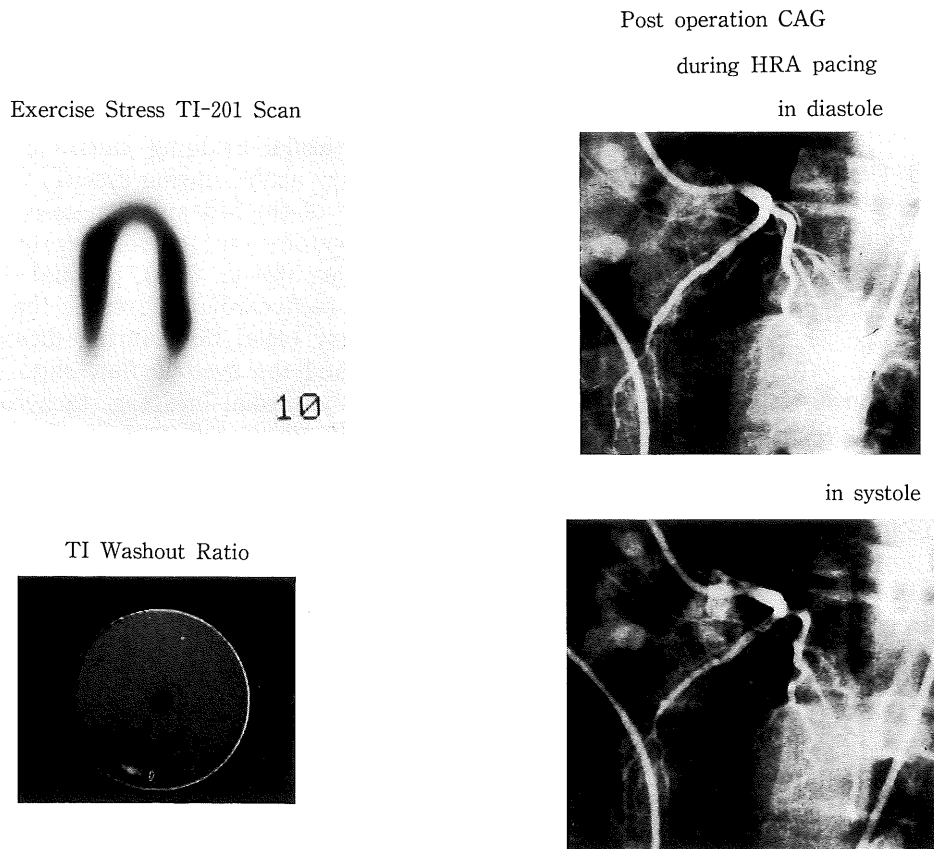
Faruqui et al<sup>1</sup> reported a case of WPW syndrome accompanied by myocardial bridging. They lysed the bridge partially after saphenous vein grafting to the left anterior descending artery, but treated the supraventricular tachycardia with propranolol, instead of surgical interruption of the accessory conduction pathway.

(Received November 5, 1990)

(Accepted January 24, 1991)



**Fig. 4.** Coronary arteriogram and myocardial scintigram during PSVT  
 Left anterior descending artery became narrow (over 90%) during systole. A myocardial scintigram also indicated myocardial ischemia in the antero-lateral portion of the left ventricle (⇒).



**Fig. 5.** Postoperative coronary cineangiogram and myocardial scintigram under high frequent atrial pacing.  
 Stenosis of the left anterior coronary artery disappeared during systole. Thallium scintigram during exercise showed normal distribution of Thallium uptake.

## REFERENCES

1. **Faruqui, A.M., Maloy, W.C., Felner, J.M., Schlant, R.C. and Logan, W.D.** 1978. Symptomatic myocardial bridging of the coronary artery. *Am. J. Cardiology* **41**: 1305-1310.
2. **Hill, R.C., Chitwood, W.R. and Bashore, T.M.** 1981. Coronary flow and regional function before and after supra-arterial myotomy for myocardial bridging. *Ann. Thorac. Surg.* **31**: 176-181.
3. **Iwa, T., Mitsui, T., Misaki, T., Mukai, K., Magara, T. and Kamata, E.** 1986. Radical surgical cure of Wolff-Parkinson-White syndrome : The Kanazawa experience. *J. Thorac. Cardiovasc. Surg.* **91**: 225-233.
4. **Misaki, T., Iwa, T., Kuzawa, Y., Murakami, S., Seki, M. and Miyazawa, K.** 1986. Simultaneous surgery for Wolff-Parkinson-White syndrome combined with tricuspid atresia. *Jap. J. Thorac. Surg.* **34**: 261-266.
5. **Nobel, J., Bourassa, M.G., Petitclerc, R. and Dyrda, I.** 1976. Myocardial bridging and milking effect of the left anterior descending coronary artery: normal variant or obstruction ?. *Am. J. Cardiol.* **37**: 993-999.
6. **Sealy, W.C., Hattler, B.G.Jr., Blumenschein, S.D. and Cobb, F.D.** 1969. Surgical treatment of Wolff-Parkinson-White syndrome. *Ann. Thorac. Surg.* **8**: 1-11.