

## Study of Portal Arterialization with Auxiliary Liver in Rats

He-Qun HONG, Toshimasa ASAHARA, Hisao ITO\*, Hiroshi WATANABE,  
Atsuo KIMURA, Takashi URUSHIHARA, Seiji MARUBAYASHI,  
Yasuhiko FUKUDA, Masayuki NISHIKI and Kiyohiko DOHI

*The Second Department of Surgery, \*The First Department of Pathology; Hiroshima University,  
School of Medicine, Kasumi 1-2-3, Minami-ku, Hiroshima 734, Japan*

### ABSTRACT

The effect of portal arterialization was examined in 20 heterotopic auxiliary rat livers. Portal blood was supplied from recipient iliac artery (0.58 mm in diameter) connected to the donor portal vein using the cuff technique. Portal hypertension caused by arterial blood pressure resulted in the immediate operative death by bleeding in four of the rats (20%) from the spontaneous rupture of the graft capsule. Severe graft congestion was noticed at autopsy 3-14 days after transplantation in 13 rats. Massive portal and sinusoidal congestion and focal hemorrhagic necrosis were confirmed by pathological examination. The results of our study demonstrate that the portal arterialization used in the auxiliary rat liver transplantation would not be applicable unless the optimal hemodynamic condition is warranted.

**Key words:** Rat liver, Portal arterialization, Heterotopic auxiliary transplantation

Since Lee et al<sup>4,5)</sup> reported the first auxiliary liver isografts in rats surviving for more than 14 months, this transplant procedure has successively provided a suitable model for several groups<sup>1-3,6,8,9)</sup>. However, the reconstruction of graft's portal vein still remains one of the most challenging procedures in this field. In the first experimental auxiliary liver transplantation, the donor's portal blood supply was from the recipient portal vein<sup>2,4)</sup>. The diversion of portal blood flow caused the damage to the native liver due to insufficient blood supply<sup>2,4)</sup>. An alternative technique for the reconstruction of the portal vein in auxiliary rat liver transplantation was described by Muller in 1983<sup>9)</sup>. The principal difference from previous methods is that the grafted liver was supplied with arterial blood from the recipient's left renal artery. A good survival rate (2-week-graft survival = 77%) has been reported.

The aim of our experimental study is to examine the technical feasibility of using recipient iliac artery anastomosed to the graft's portal vein by the cuff method, and to assess the influence of this proposed technique on graft survival.

### MATERIALS, TECHNIQUE AND METHODS

Adult male Wistar rats from closed-breeding (Charles River Japan, Inc.), weighing between 250 and 310 gm, were used as both donor and recipient. All operative procedures were carried out under sodium pentobarbital anesthesia and with clean, but

nonsterilized instruments.

#### Donor Operation

##### 1. 70% hepatectomy

In order to favor the replacement of graft in the recipient's abdomen, cephalad three lobes (70%) of the liver were resected. The remaining right lateral and caudal lobes, with an intact portal vein, common duct, as well as an infra-hepatic venous outflow, were used for transplantation.

##### 2. Liver harvesting

The common duct was cannulated with a 1.5cm-long 3FG polyethylene catheter (1.02 mm outer and 0.58 mm inner in diameter). After ligation of the common hepatic artery, the portal vein was skeletonized and its side branches (splenic vein and coronary tributary) were ligated and divided. The infra-hepatic inferior vena cava (IVC) was divided below the liver to the right renal vein and rounded by a 5-0 silk holding sling. Before the portal vein cannulation, 100 units of heparin sodium were injected into the vein of the penis. The liver was gently perfused via the portal vein and carefully resected to avoid any injury which might be the main cause of bleeding to death after revascularization.

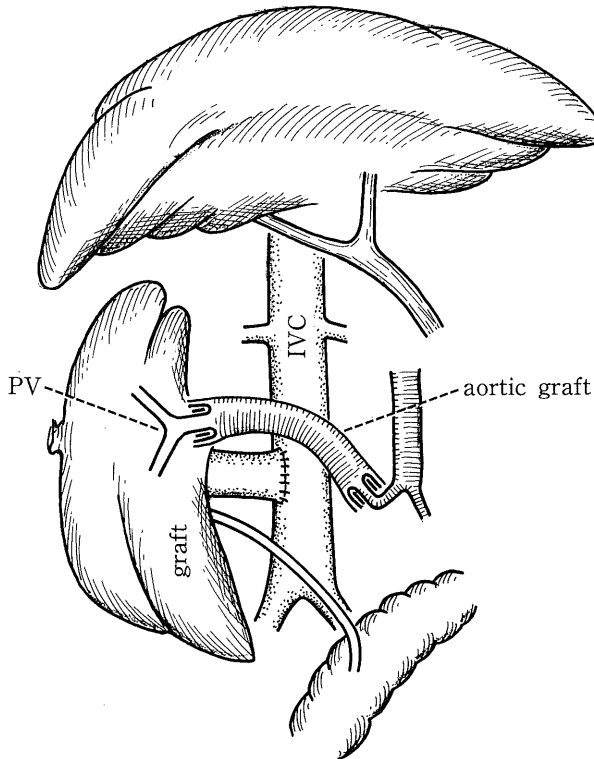
##### 3. Cuff preparation

After harvesting the liver, a 2.5cm-segment of donor thoracic aorta was prepared by ligation of all spinal branches. A 3mm-long 6FG cuff of polyethylene tube (2.1 mm outer and 1.5 mm inner in

Address correspondence to: Kiyohiko Dohi, M.D., Ph.D. The Second Department of Surgery, Hiroshima University, School of Medicine, Kasumi 1-2-3, Minami-ku, Hiroshima 734, Japan

diameter) was gently slipped over the graft's portal vein, and the cutting end of portal vein was everted over the cuff and secured in this position with a circumferential 7-0 silk ligation. The one end of the donor aortic segment was then telescoped over the cuffed portal vein and secured by circumferential 5-0 silk ligation.

Recipient Operation (Fig. 1)



**Fig. 1.** Schema of portal veno-iliac anastomosis in auxiliary liver transplantation.

1. The right iliac artery was dissected to prepare a 1.0cm-long free segment rounded by a holding sling.

2. The rat was heparinized by injection of 30 units of heparin sodium. Infra-hepatic IVC was detached from the aorta between the renal veins and the bifurcation. The animal's back was extended over a roll of sponge to exposure the IVC as superficial as possible. A Satinski-like curved vascular clamp was applied to the IVC below the renal veins at a longitudinal axis. An elliptical cut was made on the anterior wall of the IVC for future anastomosis.

3. The graft was displaced to the left side of the recipient's IVC to keep the posterior surface of graft up first. End-to-side anastomosis between the donor's and the recipient's infra-hepatic IVC was started from suturing the posterior wall of the short IVC cuff on the donor side and the right wall of the IVC on the recipient's side, using a continuous suture with 9-0 silk. After finishing this first half anastomosis, the graft was turned to the right loin of the recipient to complete the other half

anastomosis. By this technique the cloaca formed by the confluence of the hepatic veins and the IVC of the graft opened directly into the recipient's IVC. Partial reflow can be achieved after declamping Satinski.

4. The aortic graft on the cuffed portal vein of the graft was clamped by a clip to prevent blood reflux from the hepatic veins. The recipient's right iliac artery was clamped near the bifurcation with a clip and cut at 1.0 cm away from the aorta. After washing with heparin solution, the distal end of the iliac artery was everted over a 2.5mm-long 3FG polyethylene cuff (1.02 mm outer and 0.58 mm inner in diameter) ligated with a circumferential 7-0 silk. The free end of the donor's aortic segment connected to the graft portal vein was telescoped into the cuffed iliac artery of the recipient with a circular 5-0 silk ligation over the cuff. The clips on the aortic graft and the recipient's iliac artery were then removed to restore blood flow from the recipient's aorta to the graft's portal system.

5. The cannulated common duct of the graft was implanted directly into the jejunum and fixed by tightening the preset purse string (6-0 silk).

6. Postoperatively, the animals were allowed normal food and water ad libitum. Autopsy and macroscopic examination of all dead rats were performed as routine. Histological examinations were performed on 6 rats in which the cause of death could not be ascertained by macroscopic observation.

## RESULTS

A total of 20 heterotopic auxiliary liver grafts have been performed on Wistar rats. The grafts were supported with arterial blood from the portal veno-iliac anastomosis. The results are summarized in Table 1. Four rats died immediately after the operation. The main cause of death was uncontrollable bleeding from the spontaneous rupture of the graft surface. Soon after revascularization, the graft was quickly engorged with arterial blood. The capsule was highly tightened due to the progressive increase in the size of the graft. If this overdistension of the graft continued, small splits appeared on the graft surface and uncontrollable bleeding from these ruptures followed.

Three rats died between 3 and 6 days after operation—two from biliary leakage and massive graft congestion and necrosis, and one from graft necrosis caused by aortic graft kinking.

Twelve rats (60%) survived 8-14 days. Six died of diffuse intraabdominal infection with massive graft congestion. At autopsy of these rats, we found that the graft had doubled in size, and changed to a dark red-purple color and hard consistency in spite of the absence of infrahepatic IVC outflow blockage. The other 6 showed no clear cause of death at autopsy. But the same congestive changes were observed in 5 grafts. The

**Table 1.** The results of rats received auxiliary liver transplantation with portal arterialization.

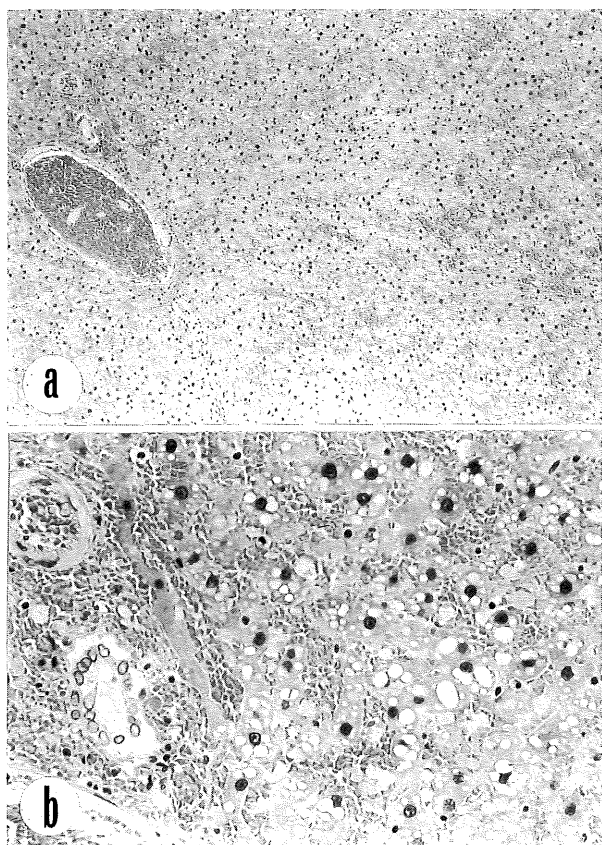
Survival (days)	n	Causes of death	n
3	5 (25%)	Bleeding from the rupture of graft's capsule	(4)
		Bleeding from cuffed iliac artery	(1)
3-6	3 (15%)	Biliary leakage and massive graft congestion	(2)
		Graft necrosis due to aortic graft kinking	(1)
8-14	12 (60%)	Suspected systemic infection	(5)
		Moderate to massive portal congestion and hemorrhage, and hepatocellular necrosis*	
		Diffuse abdominal infection accompanying massive graft congestion	
		Suspected systemic infection	
Total	20	Diffuse and moderate hepatocellular vacuolar degeneration and necrosis*	(1)
			20

\* Histopathological diagnosis.

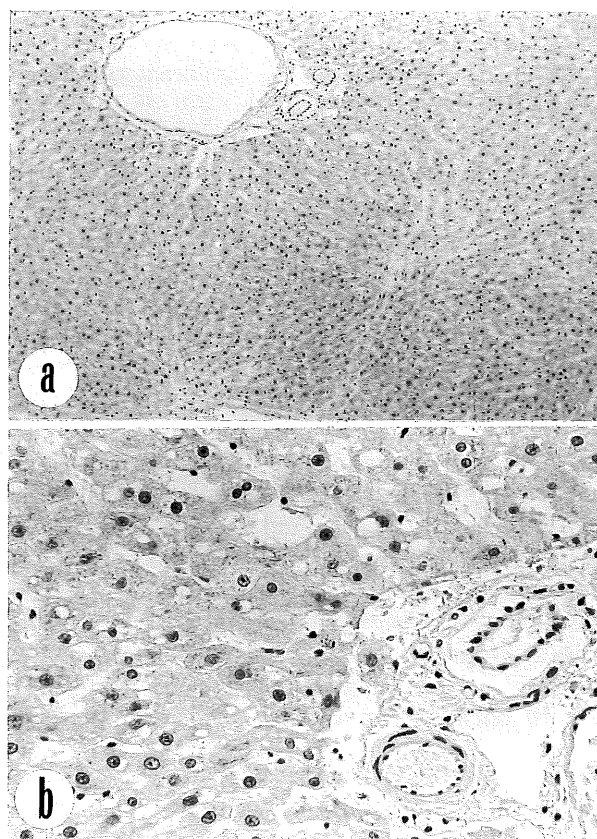
**Table 2.** Histopathological findings of auxiliary liver transplants.

Number of Case	Days after transplant	Histological Findings of Isografts			
		Congestion/Hemorrhage	Atrophy of Liver cells	Vacuolar Degeneration	Liver Cells Necrosis
AL-1	10	+++*	+	+++	+
AL-2	8	++	-	++	-
AL-3	14	-	+	++	+
AL-4	10	+++	+	+	+
AL-5	10	+++	++	-	+
AL-6	9	++	-	+	+

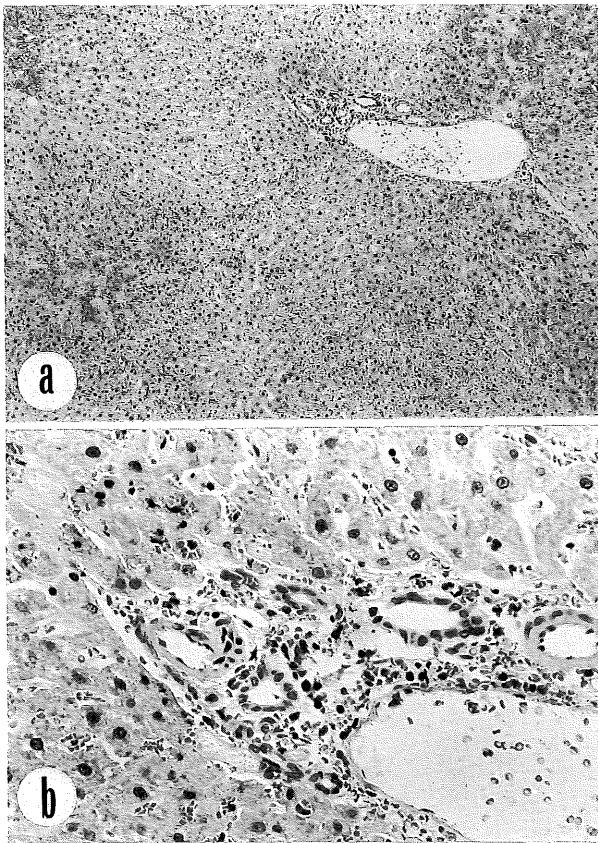
\*: The histological changes are graded as massive or severe (+++) moderate (++) and mild (+).



**Fig. 2.** Massive portal and sinusoidal congestion and hemorrhage is noted. Liver cells show vacuolar degeneration, necrosis and atrophic changes. AL-1, HE staining, a)  $\times 60$ , b)  $\times 250$



**Fig. 3.** Liver cells are slightly atrophic accompanying vacuolar degeneration. No congestion is seen. Portal vein is apparently dilated. AL-3, HE staining, a)  $\times 60$ , b)  $\times 250$



**Fig. 4.** Acute congestion is moderate and the liver cells are well preserved. A few lymphocytes infiltrated in portal area. Note dilated portal vein. Portal arteries and bile ducts show no significant changes. AL-6, HE staining, a)  $\times 60$ , b)  $\times 250$

histopathological findings (Table 2) showed that the grafts had moderate to massive portal and sinusoidal congestion with recent hemorrhage (Fig. 2 and 4) except for one (AL-3; Fig. 3). The severity depended upon the duration of the arterialization. Vacuolar degeneration of the liver cells was also observed to a variable degree, diffusely, not only in the centrilobular but also in the peripheral zone. In 5 out of 6 grafts, liver cell necrosis was found to a mild degree or in single cell manner scattered through the lobules, but zonal or massive necrosis was not present (Fig. 2 and 3). The intra-hepatic portal veins were obviously dilated and packed with red cells, while the portal arteries and the bile ducts showed no significant changes in all 6 grafts (Fig. 2, 3 and 4). There was no cholestasis. A few lymphoid cells infiltrated only in one case (AL-6) in both portal areas and sinusoids (Fig. 4)

### DISCUSSION

The problem of whether or not portal blood is essential for grafted liver survival in auxiliary liver transplantation is controversial<sup>1,10,13,14</sup>. The diversion of recipient portal vein to the graft's portal vein induced functional damage of the native liver, and neither total nor partial restoration of the por-

tal venous flow prevented the grafted liver from progressive atrophy<sup>2,7</sup>. Since Markowitz's first experiment in portal arterialization in 1949<sup>8</sup>, some experiments in auxiliary liver transplantation have demonstrated that after portal arterialization, the host liver was not damaged and that the auxiliary graft had a greater potential regeneration<sup>8,9</sup>. Muller<sup>9</sup> has used recipient left renal artery anastomosed with the graft's portal vein for re-establishing the blood supply of the auxiliary liver. The results were encouraging, with 77% of 2-week-graft survival and 6 months of long-term survival in isogeneic auxiliary liver transplantation. Because of the compensation of the normal recipient liver, the animals continued to survive after the episode of rejection. However, in our 20 experiments with portal venoarterialized grafts, 4 (20%) of the recipients died directly due to bleeding from the spontaneous rupture of the graft capsule immediately after the operation. Graft congestion was noticed in 13 out of 14 rats with 3-14 days survival. The main cause of death was severe intraabdominal infection associated with graft congestion and necrosis in 6 rats, and suspected systemic infection probably originating from damaged grafts in the other 6 rats. Microscopically, the remarkable distension and destruction of the portal veins and sinusoids, the massive portal congestion and hemorrhage, and the hepatocellular necrosis in the graft parenchyma indicated that the extremely high intravascular pressure to the portal venous system after arterialization is the single responsible cause of such complications. It has been shown by Mito et al<sup>8</sup>, Rather et al<sup>11</sup> and Schwartz et al<sup>12</sup> that the perfusion of portal vein with arterial blood in amounts exceeding normal portal venous flow caused high operative mortality due to uncontrollable bleeding from the rupture of the graft capsule and induced biochemical and histologic abnormalities including the elevation of alkaline phosphatase and acute necrotizing vasculitis of portal vein. Mito et al<sup>8</sup> also pointed out in a study of dogs that when using arterialization, reduction of arterial pressure is critical to the success of this technique. Greater pressure in the portal system can split the liver capsule to cause uncontrollable bleeding and destroy the lobecular architecture of the sinusoids, resulting in acute hepatic failure. Their study in auxiliary dog liver transplantation demonstrated that if the inflow pressure in the portal vein was reduced to 25 to 35 mmHg by fitting a Teflon cuff around the donor portal vein, in effect producing a stenosis of the portal vein, there was no rupture of the graft surface and no remarkable congestion of graft. The situation in auxiliary rat liver transplantation is similar to that in dogs. That we failed to obtain satisfactory results, in comparison with Muller's study, is probably due to the use of iliac artery which is larger in diameter than renal artery (0.58 mm : 0.28 mm). But the smaller the di-

iameter of artery, the higher the incidence of thrombosis. Thrombosis of the donor portal vein and graft infarction remained a major cause of death in Muller's group<sup>9</sup>.

In summary, the possible cause of failure of portal arterialization in auxiliary rat liver transplantation could be portal and sinusoidal hypertension induced by portal veno-arterial anastomosis. We defined that it is necessary to explore a suitable technique to establish portal veno-arterial anastomosis by which not only can the portal pressure be adjusted closer to the physiological level but also the patency of such small anastomosis be maintained for a longer period.

(Received November 19, 1990)

(Accepted January 24, 1991)

### REFERENCES

1. Coburn, R.J., Brown, H., Brown, M. and Kemeny, M.M. 1967. Studies with auxiliary liver isografts in rats, p. 643-645. *In* J. Dausset, J. Hamburger and J. Mathe (eds.), *Advance in transplantation*, Copenhagen, Ejnar Munksgaard.
2. Hess, F., Jerusalem, C. and Niels van der Heyde, M. 1972. Advantages of auxiliary liver homotransplantation in rats. *Arch. Surg.* **104**: 76-80.
3. Kort, W.J., Wolff, E.D. and Eastham, W.N. 1971. Heterotopic auxiliary liver transplantation in rats. *Transplantation* **12**: 415-420.
4. Lee, S. and Edgington, T.S. 1968. Heterotopic liver transplantation utilizing inbred rat strains: I. Characterization of allogeneic graft rejection and the effects of biliary obstruction and portal vein circulation on liver regeneration. *Am. J. Path.* **52**: 649-669.
5. Lee, S., Edgington, T.S. and Orloff, M.J. 1968. The role of afferent blood supply in regeneration of liver isografts in rats. *Surg. Forum* **19**: 360-362.
6. Marni, A. and Ferrero, M.E. 1985. Heterotopic liver grafting in the rat. *Transplantation* **39**: 329-330.
7. Marni, A., Ferrero, M.E., Forti, D. and Gaja, G.F. 1987. Advantages of cuff techniques versus standard microsurgical techniques in heterotopic nonauxiliary liver transplantation in rats. *Transplant. Proc.* **19**: 3854-3858.
8. Mito, M., Ackroyd, F.W., Covelli, V.H., Eyskens, E., Katayama, I. and McDermott, W.V. 1967. Partial heterotopic liver homograft in dogs utilizing portal arterialization. *Ann. Surg.* **165**: 20-32.
9. Muller, G. 1983. A simple technique for heterotopic auxiliary liver transplantation in the rat. *Transplantation* **36**: 221-222.
10. Ranson, J.H.C., Garcia-Moran, M., Becker, F.F. and Localio, S.A. 1972. Portal inflow and auxiliary hepatic allograft function. *Surg. Gynecol. Obstet.* **135**: 769-776.
11. Rather, L.J. and Cohn, R. 1953. Some effects upon the liver of complete arterialization of its blood supply. *Surg.* **34**: 207-210.
12. Schwartz, S.I., Morton, J.H. and McGovern, G.R. 1961. Experimental arterialization of the liver. *Surg.* **49**: 611-617.
13. Terpstra, O.T., Dekker, A. and Reuvers, C.B. 1988. Experimental auxiliary liver transplantation: lack of evidence for "functional competition". *Transplant. Proc.* **20** (Suppl. 1): 519-521.
14. Terpstra, O.T., Reuvers, C.B. and Schalm, S.W. 1959. Auxiliary heterotopic liver transplantation. *Transplantation* **45**: 1003-1007.