

A Case Report of Substernal Goiter

Kazuhiro KOCHI^{1)*}, Mitsuaki OKITA¹⁾, Motoaki ISONO¹⁾,
Shigenori SHIGEMOTO¹⁾, Kiminori WATANABE²⁾, Miho SHIGEMOTO²⁾,
Humio SHIMAMOTO³⁾, Takashi ITO⁴⁾ and Yuichiro MATSUURA⁴⁾

1) *The Division of Surgery, 2) The Division of Internal Medicine, Togouchicho National Healthy Insurance Hospital, Hiroshima, Japan*

3) *The Division of Pathology, Hiroshima University Hospital, Hiroshima, Japan*

4) *The First Department of Surgery, Hiroshima University School of Medicine, Hiroshima, Japan*

ABSTRACT

A case of substernal goiter is reported. A 78-year-old female was admitted to our hospital with no symptoms. Chest roentgenography on admission showed that a mass of 3 by 5 cm in size with calcification located in the substernal region. Computed tomography of the chest and aortography revealed that the mass was attached to the trachea, but the connection to the great vessels was not clear. Pathological findings of the incisional biopsy specimen showed thyroid tissue with no evidence of malignancy. Our clinical diagnosis was substernal goiter. Surgery was not carried out in this case, based on the literature. Surgery is indicated in case of malignancy or in cases with severe illness such as respiratory disorder and superior vena cava syndrome.

Key words: *Substernal goiter, Operative indication*

Substernal goiter is a rare condition. As few as 60 cases have been reported in Japan¹⁾. The indication of surgery is controversial because of varying frequencies of malignancy. In this report we present a case of substernal goiter, and discuss the definition, diagnosis, and operative indication.

CASE REPORT

A 78-year-old female was admitted to our hospital on October 16th, 1992 for the abnormal findings of the chest X-ray. She had no symptoms such as cough, hoarseness, and flushing. An abnormal shadow at the upper mediastinum had been noticed in the chest X-ray film of 1991 in the general health examination (Fig. 1).

Physical examination revealed a firm nodule 1 by 1 cm in size at the substernal notch with the neck extended position, but neither lymphnodes nor goiter was palpable. Laboratory examination showed euthyroid, but autoimmune thyroiditis was unable to be ruled as a result of a high level of antimicrosome antibody (Table 1).

On admission displacement of the trachea was found on the posterior to anterior view of chest X-ray film. This was caused by a mass with calcification (Fig. 2). The site of the mass was shown to be the upper mediastinum in the substernal cavity, using the lateral view.

Ultrasonography of the neck showed no mass

lesion. Computed tomography of the chest showed that the mass was attached to the trachea in the thorax. The invasion to the great vessels was not clear. The deviation of the trachea was apparent only at the level of cervical notch (Fig. 3).

Aortography revealed no hyper- nor hypovascularity from the internal thoracic artery and the inferior thyroid artery, and showed no deviation of the aorta (Fig. 4).

Incisional biopsy was carried out on October 29th, 1992. A transverse cervical incision was used under local anesthesia. The mass was easily exposed behind the sternohyoid muscle. The tumor was found to be larger at the substernal space. The adhesion to the trachea was rigid. The tumor had a pedicle attached to the thyroid gland. Wedge biopsy was made for the pathological examination.

Pathological findings showed the thyroid tissue with marked calcification. There were no findings of malignancy. It was diagnosed as mediastinal goiter (Fig. 5).

No additional surgery was performed because of the patient's rejection of any surgical treatment. She was discharged on November 6th, 1992. Follow up will be conducted based on the results of the laboratory data, X-ray, and computed tomography every 3 months.

* Reprint requests to: Togouchi-cho National Healthy Insurance Hospital, Togouchi-cho 800-1, Yamagata-gun, Hiroshima 731-38, Japan

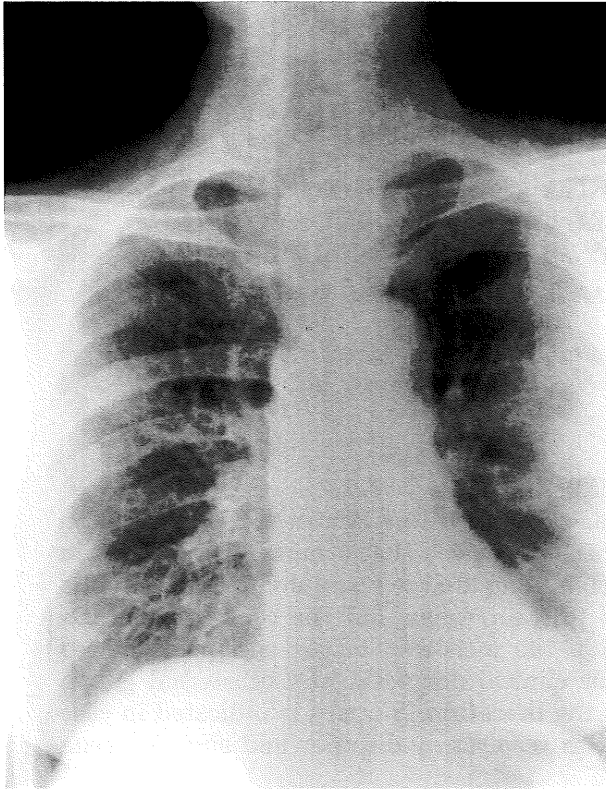


Fig. 1. Abnormal shadow was noted in Chest X-ray in 1991.

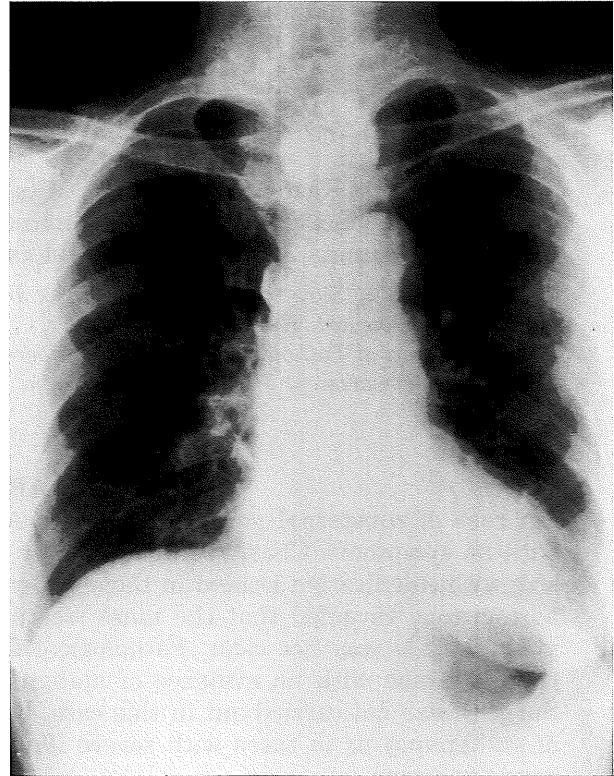


Fig. 2. Chest X-ray on admission revealed that the trachea was displaced by the the mass at the upper mediastinum. The tumor size had not changed in comparison with the findings of one year before.

Table 1. Laboratory data

TSH	0.2 μ U/ml	(0.6-4.9)
Free T3	3.9 pg/ml	(2.6-5.4)
Free T4	1.3 ng/dl	(0.8-1.9)
Thyroglobulin	13 ng/ml	(59>)
Microsome Ab.	800 \times	(100 \times >)

DISCUSSION

Regarding the definition of the substernal goiter, there are two major concepts. One is that of a solitary tumor, which maintains no connection to the thyroid gland⁷⁾, and the other is a tumor with possible connections to the thyroid gland⁵⁾. We prefer the latter concept because substernal goiter arises from the cervical thyroid tissue, grows inferiorly through the thoracic inlet, and maintains the pedicles to the thyroid gland for the blood supply in its development⁴⁻⁷⁾.

Symptoms of substernal goiter are caused by compression to the great vessels and trachea during its growth. One symptom is the hoarseness due to the tracheal compression. Another is the superior vena cava syndrome by compressing the major vessels^{4,6)}. Most patients are aware of their

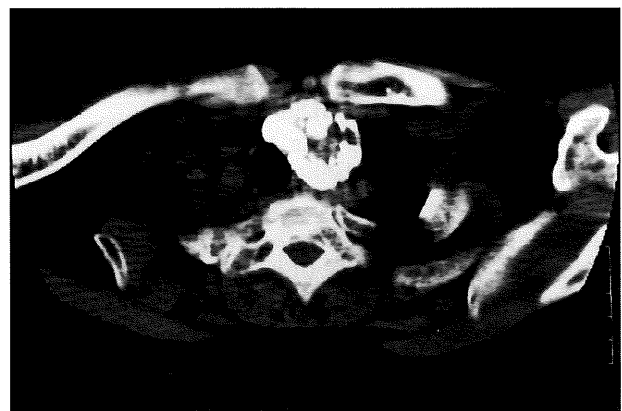

Fig. 3. Computed tomography of the chest showed that the mass was attached to the trachea.

symptoms for more than 10 years before seeking medical attention⁴⁾ because of the slow growth of the tumor. The history is useful for clinical diagnosis of substernal goiter, while imaging studies are useful for early diagnosis.

The plain X-ray is helpful for monitoring the recognition of the size, the location, and the tracheal compression in the mediastinum. Computed tomography of the chest is also useful in asses-

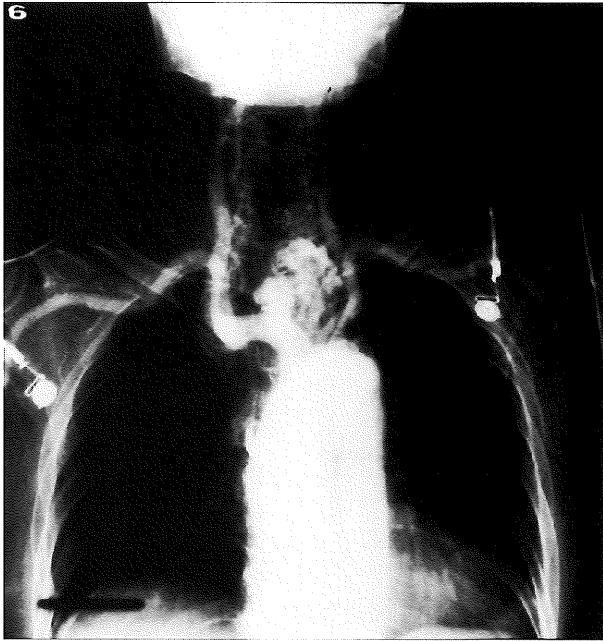


Fig. 4. The deformity of the great vessels and the tumor vessels was not clear in aortography.

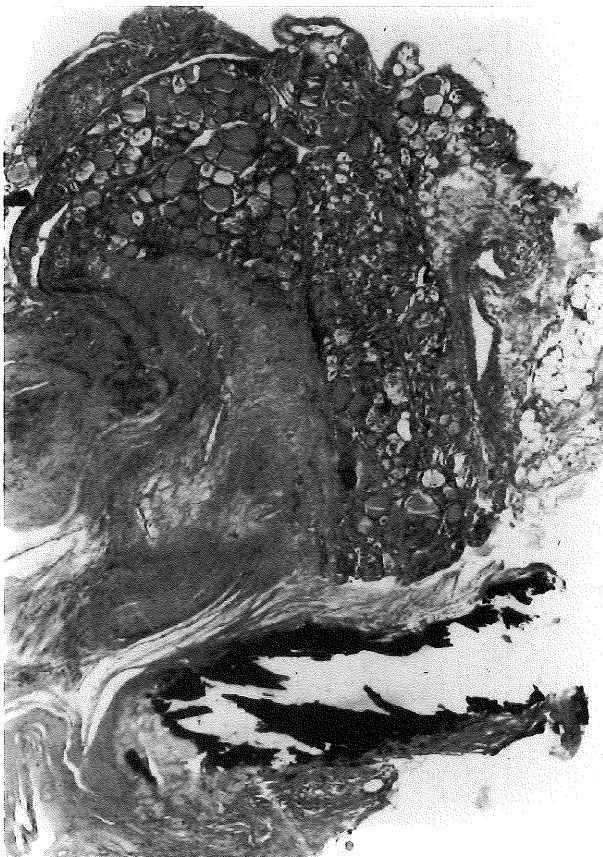

Fig. 5. Low-power view of the mediastinal goiter showing non-neoplastic thyroid gland with hyaline connective tissue and calcification (HE).

sing the compression to the trachea and great vessels. Thyroid scintigraphy with ^{131}I or ^{123}I is used to determine specifically whether the mass found at the anterior mediastinum is definitely of thyroid tissue³). Pathological examination of the specimen from the incisional or needle biopsy is the only method to identify the tissue as thyroid and to examine the presence of malignancy.

There is some difference in the operative indication described in the English literature and the Japanese literature. In the former^{1,4}), operative indication is applied to cases in which tracheal compression is so severe that it causes hoarseness and shortness of breath^{2,6,8}). In the latter^{2,6,8}), however all cases of substernal goiter have operative indication because of the frequent occurrence of occult papillary thyroid carcinoma. The incidence of malignancy in substernal goiter is estimated to be as high as 45.8 % in Japan by the nationwide statistical analysis of more than 244 patients⁸), while 2 to 5 % in western countries by the analysis of more than 300 cases¹). In our case, according to the former operative indication surgery should not have been carried out on the basis of the patient's clinical course. However according to the latter operative indication, surgery should have been carried out in order to prevent from developing malignant tumor. We await a follow up result.

(Received May 17, 1993)

(Accepted October 26, 1993)

REFERENCES

1. **Allo, M.D. and Thompson, N.W.** 1983. Rationale for the operative management of substernal goiters. *Surgery* **94**: 969-977.
2. **Hoshi, E. and Fukusawa, M.** 1986. A case of complete mediastinal goiter. *J.J.A.T.S.* **34**: 510-513.
3. **Irwin, R.S. and Good, C.A.** 1978. ^{131}I iodine thyroid scanning in preoperative diagnosis of mediastinal goiter. *Ann. Intern. Med.* **89**: 73-74.
4. **Katilic, M.R. and Grillo, H.C.** 1985. Substernal goiter. Analysis of 80 patients from Massachusetts General Hospital. *Am. J. Surg.* **149**: 283-287.
5. **Mora, J.M. and Issacs, H.J.** 1944. Posterior mediastinal goiter. *Surg. Gynecol. and Obstet.* **79**: 314.
6. **Okubo, T. and Okayasu, T.** 1991. A case of substernal goiter. *J.J.A.T.S.* **50**: 889-893.
7. **Rives, J.D.** 1947. Mediastinal aberrant goiter. *Ann. Surg.* **126**: 798.
8. **Wada, H. and Teramatsu, T.** 1981. Mediastinal tumors - A statistical nationwide report of 1,546 cases between July, 1975 and May, 1979 in Japan. *J.J.A.T.S.* **30**: 334-338.