

A Case Report of Epithelioid Leiomyosarcoma of Transverse Mesocolon: diagnosis and treatment

Kazuhiro KOCHI¹⁾, Shigenori SHIGEMOTO¹⁾, Motoaki ISONO¹⁾, Reiko MAEDA²⁾, Yasuo MAEDA²⁾, Miho SHIGEMOTO²⁾, Wataru YASUI³⁾ and Yuichiro MATSUURA⁴⁾

1) *The Department of Surgery, 2) The Department of Internal Medicine, Togouchi National Health Insurance Hospital, Hiroshima, Japan*

3) *The First Department of Pathology, Hiroshima University School of Medicine, Hiroshima, Japan*

4) *The First Department of Surgery, Hiroshima University School of Medicine, Hiroshima, Japan*

ABSTRACT

A case of epithelioid leiomyosarcoma of the transverse mesocolon in a 45-year-old man was reported. The patient had a rapidly growing mass in the left upper quadrant. Ultrasonography, gastrointestintography, and abdominal computed tomography showed that the mass was separated from the pancreas, the gastrointestinal tract, and the retroperitoneal organs. Preoperatively the primary origin of this tumor was related to the transverse mesocolon. On laparotomy the tumor of 5cm by 6cm by 3cm in size was found in the anterior leaf of the transverse mesocolon and the mass was resected entirely. The patient is well 18 months after surgical treatment with no evidence of recurrence.

Key words: *Epithelioid leiomyosarcoma of transverse mesocolon, Diagnosis, Treatment*

Malignant smooth muscle tumors of the transverse mesocolon is a rare condition. Only 10 cases have been reported since 1965 in Japan¹⁾. A five-year survival rate has been reported of 0-20%^{2,3)}. Complete excision affords the only real hope of long-term salvage. We report a case in which en bloc resection was possible, and discuss diagnosis and treatment.

CASE REPORT

45-year-old man was admitted to our hospital with an upper abdominal mass. He had no complaints other than a rapidly growing mass. Physical examination revealed a firm and smooth mass, 5 cm by 6 cm in size, located at the left upper quadrant of the abdomen. Laboratory investigations showed no abnormalities, and the values of CEA and CA19-9 were within normal limits.

Abdominal ultrasonography showed a mass of 6 cm by 7 cm in size, located above the pancreas which showed the "pseudo kidney sign", that is, hyperechoic area at the periphery and a hypoechoic area at the center (Fig. 1-a). Space occupying lesion of the liver and swelling lymphnodes around the aorta were not recognized.

Upper gastrointestintography showed the compression of the stomach and transverse colon to-

ward superior by the mass. Ba enema showed no mucosal and extra colonic lesion.

Computed tomography showed that the mass was separated from the transverse colon and that it had not invaded to the pancreas. There was no evidence of the invasion to the pancreas and other retroperitoneal organs, or of metastasis to the lymphnodes and liver (Fig. 1-b).

Celiac- and supramesenteric-arteriography showed an irregular tumor stain and revealed that the feeding artery of this tumor was the midcolic artery (Fig. 1-c). Thus, our diagnosis was of a primary tumor of the transverse mesocolon.

A laparotomy was performed on March 3rd, 1991. The tumor was 5 cm by 6 cm in size and arose from the anterior sheath of the transverse mesocolon. Invasion to the pancreas was not clear, and adhesion to the posterior sheath of the transverse mesocolon was not severe so that the bursectomy was easily performed. Obvious metastasis to the lymphnodes and other organs was not recognized except for inflammatory lymphadenopathy of the bursa omentalis (Fig. 2-a).

Macroscopically the tumor was 5 cm by 6cm by 3 cm in size and a well-capsuled solid tumor containing cystic necrosis (Fig. 2-b).

Microscopically, the tumor was composed of-

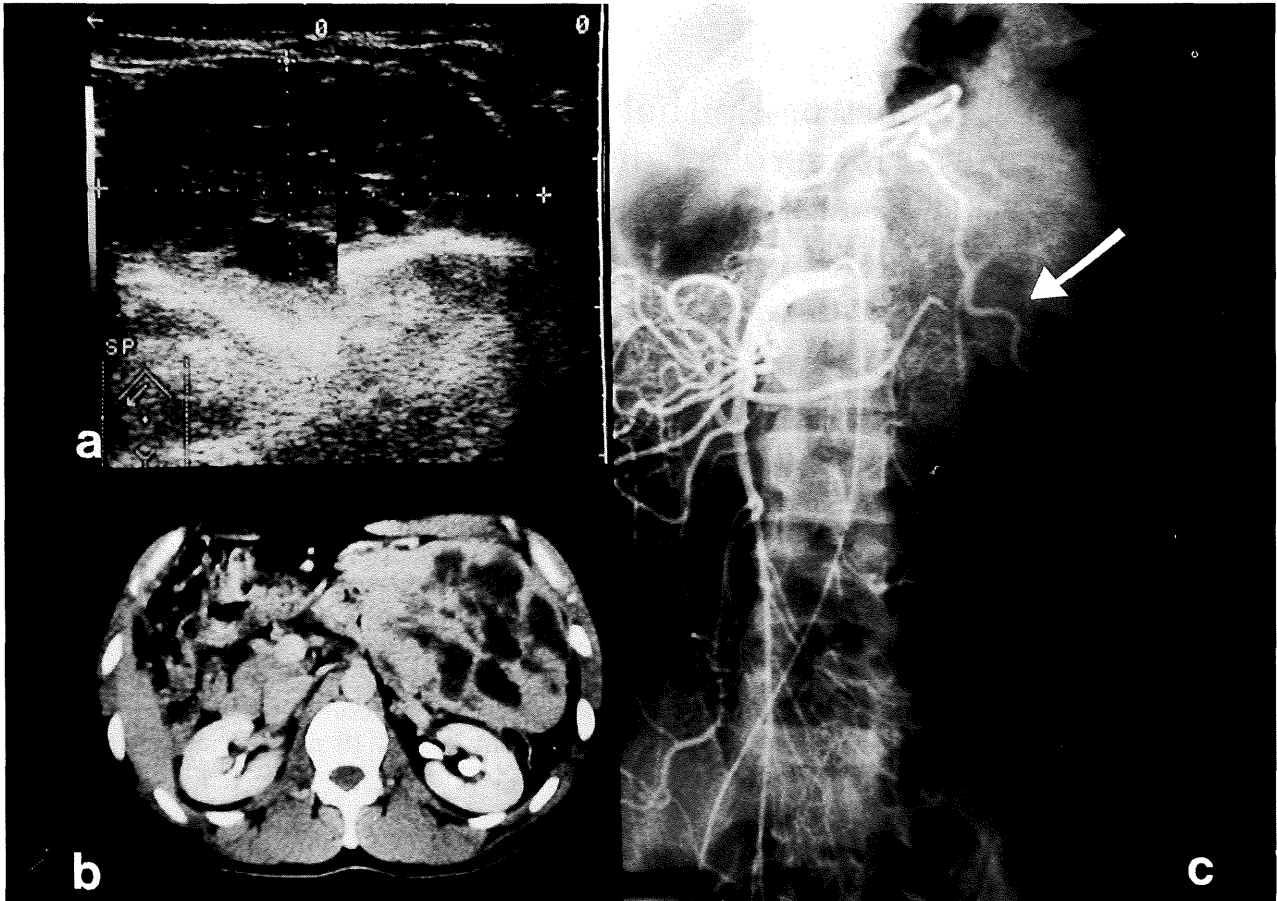


Fig. 1-a. Abdominal ultrasonography showed a mass of 6 cm by 7cm in size, located above the pancreas.

Fig. 1-b. Computed tomography showed the mass was separated from the transverse colon, pancreas, and retroperitoneal organs.

Fig. 1-c. Supramesenteric arteriography showed an irregular tumor stain and revealed that the feeding artery was the midcolic artery (arrow).

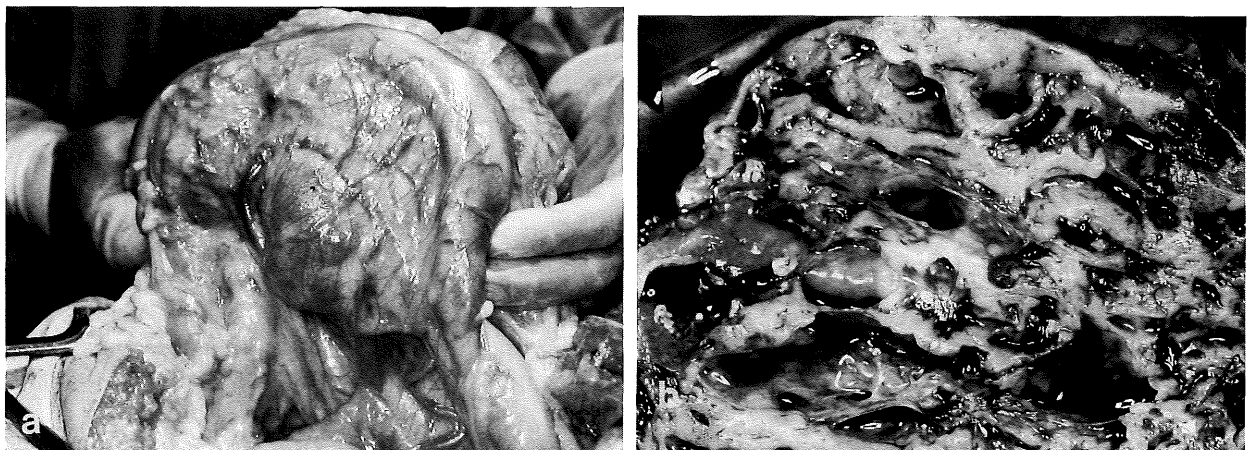

Fig. 2-a. On laparotomy, the tumor was located at the anterior sheath of the transverse mesocolon.

Fig. 2-b. Macroscopically the tumor was 5 cm by 6 cm by 3 cm in size, and was solid with cystic necrosis.

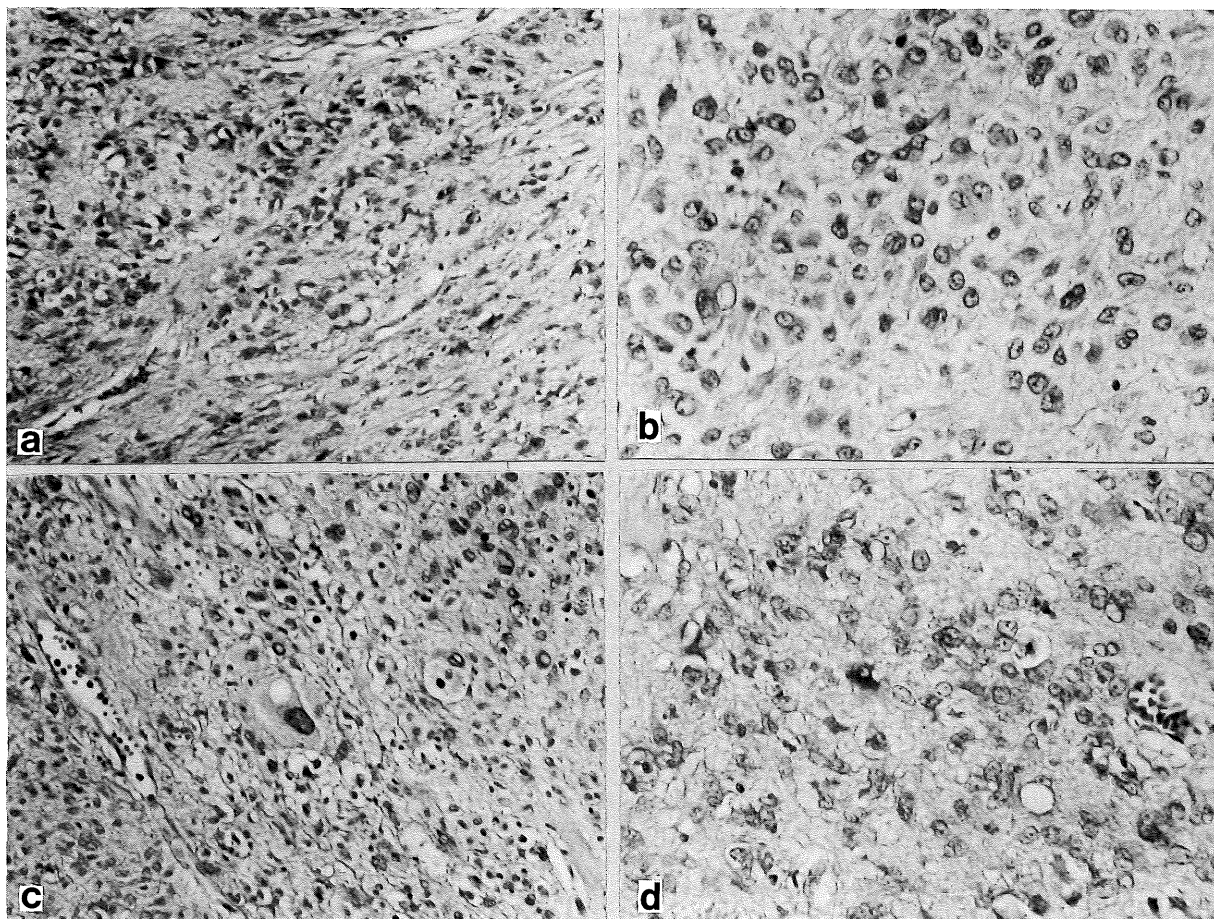


Fig. 3. Microscopic findings of the epithelioid leiomyosarcoma (HE staining).

Fig. 3-a. Short spindled cells proliferate in sheets rather than fascicles.

Fig. 3-b. The round or short spindled tumor cells have amphophilic cytoplasm, and a small number of multinucleated giant cells are seen.

Fig. 3-c. In some parts, tumor cells with clear cytoplasm and pleomorphic giant cells are found.

Fig. 3-d. Mitotic figure is not frequent.

short spindled and rounded cells that grew in sheets rather than fascicles (Fig. 3-a). The short spindled tumor cells had amphophilic cytoplasm, and multinucleated giant cells were present (Fig. 3-b). Some epithelioid tumor cells showed clear cytoplasm, and in part cellular pleomorphism was prominent (Fig. 3-c). The cellularity varied in areas, and mitoses were not frequently found (Fig. 3-d approximately 1/10 high-power field). In some parts, myxoid degeneration and cystic change were seen. Histochemically, the cytoplasm of the tumor cells was red in Masson's trichrome staining, and there was no positive oil red O staining in the tumor cells. Reticulin staining showed fine fibers around the tumor cells. Immunohistochemically, the short spindled tumor cells were positive for desmin but negative for S-100 protein, neuron-specific enolase, alpha-smooth muscle actin and myoglobin. The tumor was diagnosed as epithelioid leiomyosarcoma. There was no findings of metastasis in the resected lymph-

nodes.

Neither radiotherapy nor chemotherapy was applied, since the tumor had been excised completely and there were no metastatic lymphnodes. The patient is alive and well 27 months after surgical treatment and there is no evidence of recurrence.

DISCUSSION

Malignant smooth muscle tumors of the transverse mesocolon is an uncommon disease. Only 10 cases have been reported in Japan since 1965⁸⁾. Epithelioid leiomyosarcoma (malignant leiomyoblastoma) is rare.

Typical pathological features of epithelioid smooth muscle tumors are that they are composed of nodules of short spindle and rounded epithelioid cells with a clear cytoplasm. Their morphological character is different from leiomyosarcoma²⁾. Epithelioid leiomyoma is distinguished from epithelioid leiomyosarcoma principally on the basis of mitotic figures and size. More than

4 or 5 mitosis/50 HPF and greater than 6 cm in size is considered malignant²⁾.

Although accurate preoperative diagnosis for a abdominal rapidly growing mass in the abdomen is difficult preoperatively, it is possible to locate the tumor and it is important to determine its resectability. First ultrasonography is carried out in order to investigate the location and the characteristics of the mass, that is whether the mass comes from the pancreas or not⁵⁾. As the second step upper gastrointestinal radiography and barium enema predispose whether the primary origin of the mass is the digestive system or the extradigestive system. The findings of abdominal computed tomography are useful for determining communication to the retroperitoneal organs.

Angiography is helpful for showing unexpected anomalies of the celiac and mesenteric arteries. The most consistent feature of the angiography of mesenteric smooth muscle tumors is hypovascularity at the tumor site and displacement of major vessels by the tumor³⁾. Tumor staining and early venous filling are not frequently seen. In the present case, celiac- and supramesenteric arteriography showed hypervascularity and early filling from the feeding artery, although this is not frequently seen on the literature. Because the first branch of the supramesenteric artery which communicates to the gastropilic artery fed the tumor, the midcolic artery was suspected to be the feeding artery. Thus, an assessment of tumor characteristics is done preoperatively by integrating these findings of image studies.

The most reliable treatment is complete resection of the tumor. Surgical technique should essentially include en bloc excision of involved organs including the tumor capsule¹⁾. Blood loss can be reduced by ligating the feeding artery in the early stage, especially when abnormal adhesion to other organs is involved. As far as malignancy of the mesocolon is concerned, the

operative procedures should involve bursectomy, which is useful not only for resecting the tumor but also for evaluating the connection to the pancreas, stomach, and transverse colon. However many unresectable cases have been reported^{1,4,6-8)}, and neither chemotherapy nor radiotherapy is effective for malignant tumors associated with smooth muscle^{1,4,6-8)}. En bloc resection based on the results of an early diagnosis should be made to minimize the risk of residual disease.

(Received March 29, 1993)

(Accepted July 9, 1993)

REFERENCES

1. **Cody, H.S. and Turnbull, A.D.** 1981. The continuing challenge of retroperitoneal sarcoma. *Cancer* **47**: 2147-2152.
2. **Enzinger, F. and Weiss, S.** 1988. Epithelioid smooth muscle tumors, p. 422-432. In *Soft tissue tumor*, The C.V.Mosby Company, St.Louis.
3. **Granmayeh, M. and Jonsson, K.** 1978. Angiography of abdominal leiomyosarcoma. *Am. J. Roent.* **130**: 725-730.
4. **Hashimoto, H. and Tsuneyoshi, M.** 1985. Malignant smooth muscle tumors of the retroperitoneum and mesentery; a clinicopathologic analysis of 44 cases. *J. Surg. Onc.* **28**: 177-186.
5. **Hosi, S.** 1990. A case of primary epithelioid leiomyosarcoma of the mesocolon ascendens (In Japanese with English Abst.). *Jpn. J. Med. Ultrasonics.* **17**: 562-566.
6. **Mahendra, R. and Richard, L.K.** 1977. Smooth muscle tumors of the gastrointestinal tract and retroperitoneum. *Cancer* **39**: 255-262.
7. **Pedro, L. and Steven, I.H.** 1972. Gastric and extragastric leiomyoblastomas. *Cancer* **29**: 305-311.
8. **Sakata, M. and Ono, T.** 1991. Leiomyosarcoma of the transverse colon (In Japanese with English Abst.). *Jpn. Soc. Clin. Surg.* **52**: 1857-1861.