

## A Case of Isolated Acute DeBakey II Redissection Occurring in a Postoperative Survivor Who Underwent an Arch Replacement for Acute DeBakey IIIb Dissection

Kazuhiro KOCHI, Yoshio KANZAKI, Koutaro SHIRAGA, Satoshi KONO,  
Tatsuhiko KOMIYA and Katsuhiko IMAI

*The Heart Institute, Division of Cardiovascular Surgery, Kurashiki Central Hospital, Kurashiki, Japan*

### ABSTRACT

A case of isolated acute DeBakey II redissection which occurred in a postoperative survivor who underwent an arch replacement for acute DeBakey IIIb dissection is reported. The operative findings revealed that there was an intimal tear above the left coronary cusp, that there was a false lumen in the native ascending aorta, and that a residual false lumen caused by the initial operation had not been detected. Redissection caused mainly by the operative procedure, such as the failure to include the site of the intimal tear in the original repair and the formation of a new dissection as a result of anastomotic failure, is frequently seen.

However, isolated redissection is a rare condition. In this paper we discuss classification, diagnosis and treatment of redissection.

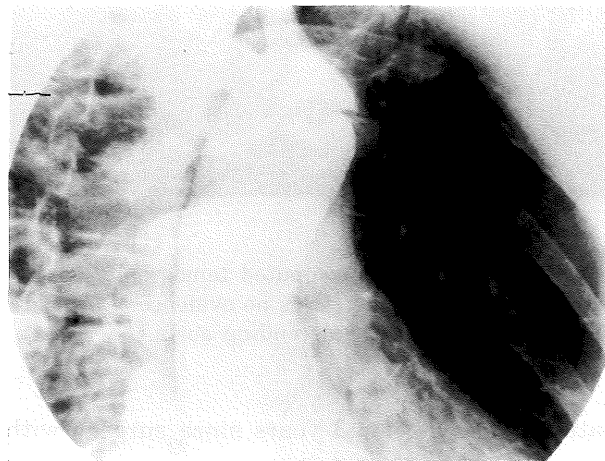
**Key words:** *Isolated Aortic Redissection*

Isolated redissection which actually consists of a new aortic dissection in a different part of the previously dissected aorta is extremely rare. However, aortic redissection after surgical treatment of an acute aortic dissection sometimes develops years after surgical treatment and is caused by the progression of a possible residual false lumen or the medial degeneration of Marfan's syndrome. We report a case of isolated acute DeBakey II redissection in a non-Marfan patient and discuss the classification and treatment of aortic redissection.

### CASE REPORT

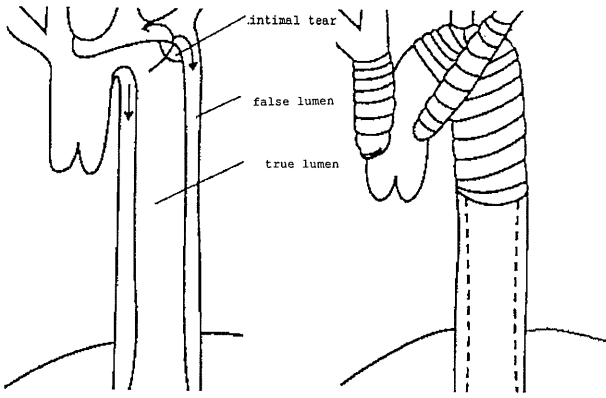
#### The first admission)

A 57-year-old male was admitted to our hospital as an emergency for sudden severe back pain on January 11th 1992. Aortic dissection was suspected because of symptoms such as sudden interscapular pain and the feeling of impending death, and because of the widening of the mediastinal shadow in chest roentgenography. Marfan's syndrome was not recognized in his appearance. The findings of aortography was of DeBakey III aortic dissection. An intimal tear was evident in the greater curve of the descending aorta beyond the left subclavian artery and a false lumen was enlarging and progressing toward the ascending aorta (Fig. 1). Arch replace-

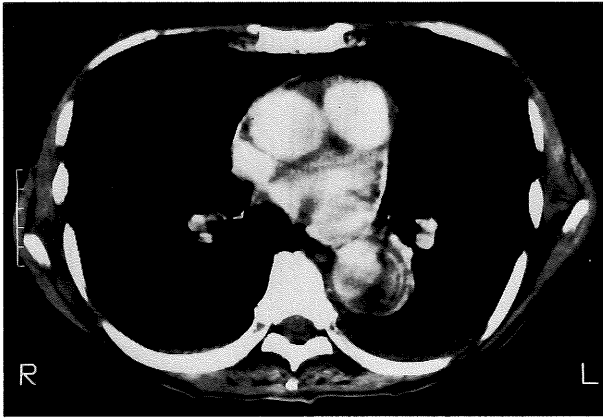

**Fig. 1.** An intimal tear was evident in the greater curve of the aortic arch beyond the left subclavian artery, and a false lumen was enlarging and progressing toward the proximal part of the aorta.

ment including reconstruction of the arch vessels was carried out in order to prevent arch vessel occlusion and ascending aortic dissection (ascending aorta-innominate artery bypass, left carotid artery-graft bypass, ascending aorta-left subclavian artery bypass) (Fig. 2). Postoperative computed tomography of the chest showed no false channel in the ascending aorta (Fig. 3). The



**Fig. 2.** Operative findings showed that an intimal tear was evident in the greater curve of the aortic arch and that a false lumen was enlarging and progressing toward proximal part of the aorta (left). Arch replacement was performed (right).

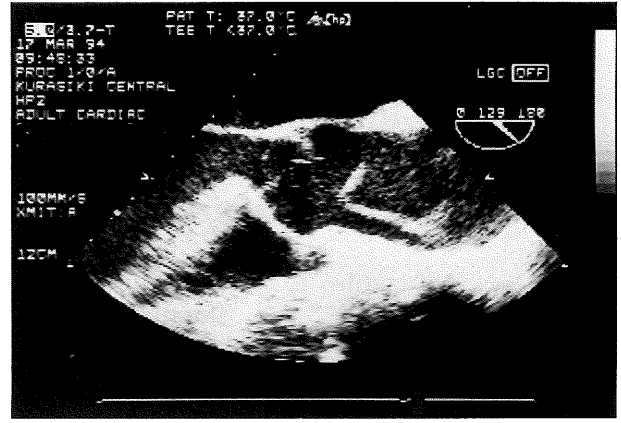


**Fig. 3.** Postoperative computed tomography of the chest showed that there was no evidence of a residual false lumen in the ascending aorta.

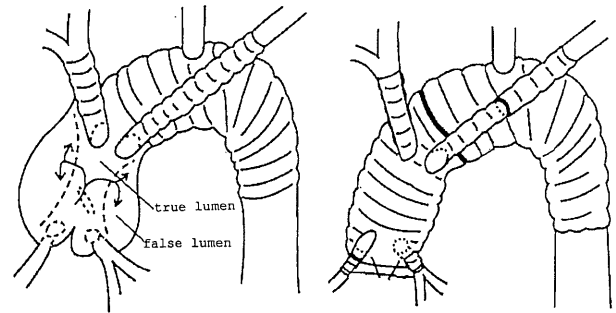
patient was well for 3 years since surgery without evidence of redissection.

#### The second admission)

The patient was again admitted to our hospital with general fatigue and dyspnea on effort lasting 2 weeks on May 23th 1994. Physical examination showed that a diastolic murmur was audible at the 2nd sternal border. Cardiomegaly was found in the chest roentgenography. The findings of echocardiography and transesophageal echocardiography were of DeBakey II aortic dissection and severe aortic regurgitation. An intimal flap was identified above the left coronary cusp and enlargement of the ascending aorta and aortic valve was found (Fig. 4). Operative findings revealed that there was an intimal tear above the left coronary cusp, that there was a



**Fig. 4.** The findings of transesophageal echocardiography was of DeBakey III aortic dissection.



**Fig. 5.** Operative findings identified an intimal flap above the left coronary cusp and showed that the false lumen did not involve the grafted arch vessels (left). A modified Bentall operation was carried out, including the reconstruction of the arch vessels. Operative findings revealed that the intimal tear was above the left coronary cusp, that there was a false lumen was in the native ascending aorta, and that a residual false lumen caused by the initial operation had not been detected.

false lumen in the native ascending aorta, and that a residual false lumen caused by the initial operation had not detected (Fig. 5). A modified Bentall method, using a composite graft under deep hypothermic selective cerebral perfusion, was performed. Thus replacement of the ascending aorta, coronary reconstruction and aortic valve replacement were carried out. Reconstruction of the arch vessels was also carried out, because the donor artery of the previously reconstructed arch vessels was the ascending aorta. Pathological examination of the resected aorta showed no medial degeneration as in Marfan's syndrome. There was no complication in the post-operative course and the patient has been well since the second surgery was performed.

## DISCUSSION

Redissection occurred in at least 8–21 % of surgically treated patients, in most of whom a persistent residual false lumen was recognized on reoperation<sup>4,6</sup>. Persistence of dissection in the residual thoracic aorta is not uncommon, especially after repair of ascending aortic dissection that extends into the aortic arch, as well as in primary aortic arch dissection with retrograde involvement of the ascending aorta<sup>2,5,8</sup>. However, isolated redissection which is actually a new aortic dissection in a different part of the previous aortic dissection is a rare condition, which has not been reported in literatures in English.

Clinical classification of the aortic redissection consists of three types: 1) Redissection associated with median degeneration, which is known as the pathological feature of Marfan's syndrome<sup>3,7</sup>; 2) Redissection mainly caused by the operative procedure, such as the failure to include the site of the intimal tear in the original repair and the formation of a new dissection on as a result of anastomotic failure; 3) Isolated redissection which is really a new aortic dissection in a different part of the previous aortic lesion. Marfan's syndrome is believed to significantly increase the possibility of redissection<sup>3,6,7</sup>. Most of the non-Marfan cases of redissection belong to the 2nd type in which residual false lumens are recognized postoperatively<sup>4</sup>. In particular, arch replacement is considered to involve a high risk of redissection, because it highly increases the possibility of a residual false lumen<sup>1,2,5</sup>. Our case is of the 3rd type, because neither a residual nor a new false lumen as the result of the initial operation was recognized in the second operation, and because medial degeneration was not identified in the pathological examination.

Urgent surgical treatment should undoubtedly be carried out for redissection in the ascending aorta, because the retrograde extension of a false lumen sometimes develops into acute aortic regurgitation, severe cardiac tamponade, and coronary arterial ischemia.

As far as the prevention for redissection is con-

cerned, the importance of primary resection of an intimal tear in the aortic arch is proved in significantly decreasing of the possibility of later reoperation and redissection<sup>2</sup>. Long term following up should be carried out for cases in which aortic medial degeneration is detected by postoperative pathological examination, because the possibility of redissection is significantly higher in Marfan's patients.

(Received November 21, 1994)

(Accepted March 7, 1995)

## REFERENCES

1. **Bachet, J., Brizard, C.H. and Goudot, B.** 1990. Repeated surgery for recurrent dissection of the aorta. *Eur. J. Cardiothoracic.* **4**: 238–244.
2. **Carrel, T., Pasic, M., Jenni, R., Tkebuchava, T. and Turina, M.I.** 1993. Reoperations after operation on the thoracic aorta: Etiology, surgical techniques, and prevention. *Ann. Thorac. Surg.* **56**: 253–258.
3. **Crawford, E.S., Crawford, J.L., Stowe, C.L. and Safi, H.L.** 1984. Total aortic replacement for chronic aortic dissection occurring in patients with and without Marfan's syndrome. *Ann. Surg.* **199**: 358–362.
4. **Glower, D.D., Speier, R.H., White, W.D., Smith, L.R., Rankin, J.S. and Wolfe, W.G.** 1991. Management and long-term outcome of aortic dissection. *Ann. Surg.* **51**: 31–40.
5. **Haverich, A., Miller, D.C., Scott, W.C., Mitchell, R.S., Oyer, P.E., Stinson, E.B. and Shumway, N.E.** 1985. Acute and chronic aortic dissections-determinants of long-term outcome for operative survivors. *Circulation* **72**: II22–34.
6. **Kirklin, J. and Barratt-Boyes, B.G.** 1993. *Acute aortic dissection: 1721–1748.* Cardiac Surgery, second edition, Churchill Livingstone. New York.
7. **Kouchoukos, N.T. and Marshall, W.G.** 1986. Treatment of ascending aortic dissection in Marfan's syndrome. *J. Cardiac. Surg.* **4**: 333–346.
8. **Miller, D.C., Stinson, E.B., Oyer, P.E., Rossiter, S.J., Reitz, B.A., Griep, R.B. and Shumway, N.E.** 1978. Operative treatment of aortic dissections: Experience with 125 patients over a sixteen-year period. *J. Thorac. Cardiovasc. Surg.* **78**: 365–387.