

Spinal Cord Injuries in Children Observed Over Many Years

Osamu YOSHIMURA, Kiyomi TAKAYANAGI, Kotaro KAWAGUCHI,
Akiteru TAKAGI and Masayuki NISHIKI

*Institute of Health Sciences, Hiroshima University School of Medicine, 1-2-3, Kasumi, Minami-ku,
Hiroshima 734, Japan*

ABSTRACT

The known salient features of spinal cord injuries in children are that 1) plane X-rays may not show dislocations or fractures, 2) many of these injuries are complete transections, 3) many injuries are located at the level of upper thoracic spine, and 4) the duration of spinal shock is short. Complications such as pressure sores occur just as easily in children as in adults and the injuries tend to be just as intractable. Complications characteristic in children with spinal cord injuries are spinal deformity and hip dislocation.

In this paper, we describe a case involving a C7 spinal cord injury caused by a fall when the patient was 3 years old. We have observed the physical complications for 15 years following that injury. We also report on other observed cases of spinal cord injury.

Key words: *Children, Spinal cord injury, Complication*

Spinal cord injury in growing children shows unique clinical phenomena usually not observed in fully grown adults since children spinal cord injury occurs. Features of the injury may be summarized as follows: fracture or dislocation is not revealed by a simple roentgenogram, many patients suffer from complete spinal cord injury, the injury is often found in the upper thoracic spinal cord, and spinal shock continues for a short period.

Pressure sore in children as a complication is liable to occur and tends to be more refractory than in adults. Complications specific to children are represented by spinal deformity and dislocation of the hip joint. In this report, some cases of spinal cord injury in children that have been observed over many years are reported and some of the salient issues are reviewed.

CASE REPORTS

Case 1 18-year-old senior high school boy (Fig. 1~3)

The patient fell to the ground from a window in the 4th floor of his apartment building at the age of 3. As is usual in cases of spinal cord injury in children, roentgenogram of the cervical spine failed to reveal fracture or dislocation. He showed moderate spasticity in his legs, suggesting a transverse injury at the level of the 7th cervical vertebra. He initially had reflex urinary incontinence, and became able to do self-catheterization after the age of 4. While he periodically underwent renal function tests, pyelography, and cysto-

graphy until the age of 18, nothing abnormal was noted urologically throughout. He could manage to propel a wheelchair and left hospital at the age of 4. Since then, he visited the hospital every 3 months as an outpatient. He showed bilateral acetabular dysplasia and dislocation of the hip joint, but no treatment was performed on his hip joint considering of the injured cervical spinal cord. He entered elementary school at the age of 6 without any particular trouble. He was handicapped with his fingers intrinsically minus-deformed, but he could use a pencil with his thumb and index finger in a lateral pinch, sufficient in terms of writing speed and legibility. He entered

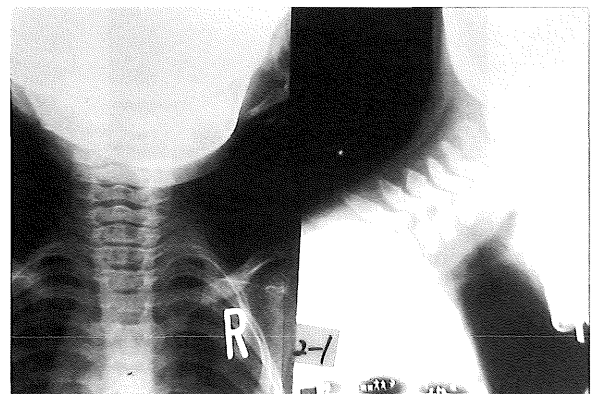

Fig. 1. Case 1 – a plane roentgenogram taken at the age of 3 revealed no sign of dislocation or fracture. (3 years)

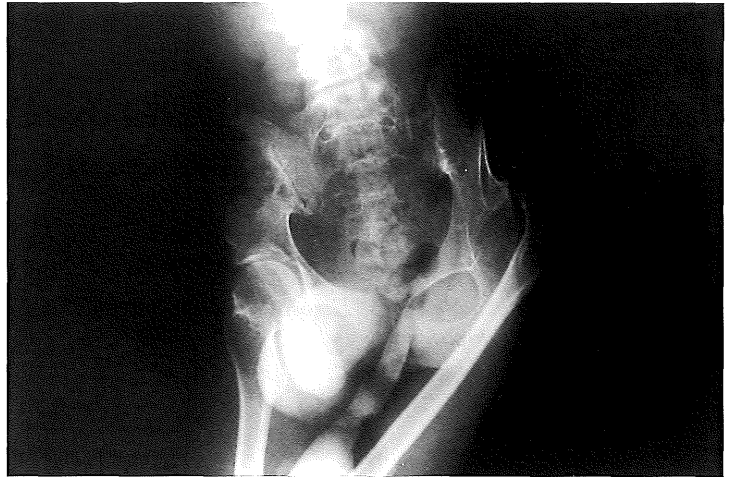
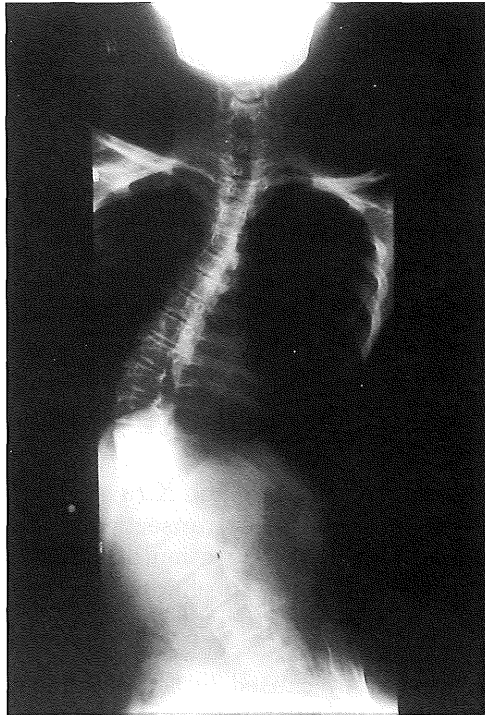


Fig. 2. Case 1 – spinal deformity, dislocation of hip, and pelvic tilt revealed. (14 years)

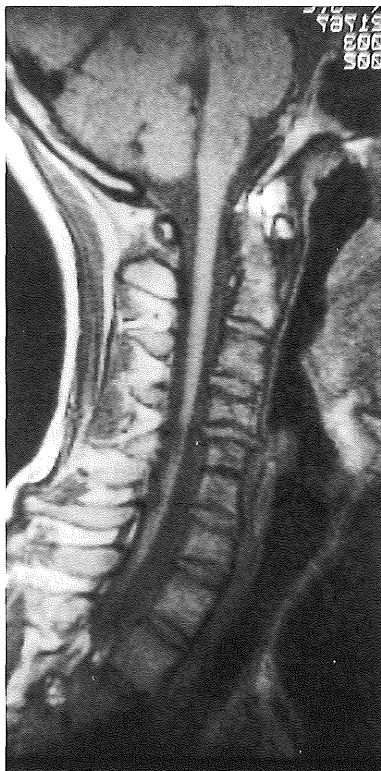


Fig. 3. Case 1 – on MRI recently taken showed abnormal spinal cord, vertebrae and intervertebral disks. (18 years)

junior high school at the age of 12. Spinal deformity appeared and was aggravated by the age of 14. Numerous forms of treatment such as sheet socket, spinal orthosis, and therapeutic exercise had been tried since his hospitalization to pre-

vent the progress of his deformity. In spite of the presence of severe spinal deformity, pelvic tilt, and dislocation of the hip joint, no surgical treatment was ever conducted up to the present stage. He was advised to do push-up exercises and use a ROHO cushion to avoid pressure sores due to his pelvic tilt and dislocation of the hip joint. A pulmonary function test revealed 1,900 ml of vital capacity and 82% of FEV_{1,0}%. He joined a personal computer club as an extracurricular activity. He also joined a study tour. He is now studying hard to prepare for university entrance examination. Development of the carpal and tarsal bones was examined to see if the early spinal cord injury unfavorably influenced skeletal growth, but no particular retardation was noted in those areas.

MRI taken recently showed that the spinal cord at the C4,5 level was narrowed, suggesting atrophy, and gave a signal almost equal to the concentration of cerebrospinal fluid in this region. The vertebral bodies of C3,4,5,6,7 were found to be deformed and the intervertebral disc of C5,6 was absent, so that the two segments had the appearance of being fused. Plane roentgenogram at the age of 3 revealed no dislocation or fracture of the spine, but he presumably suffered from injuries at the end plates and the intervertebral disc at that time.

Case 2 27-year-old woman (Fig. 4, 5)

The patient was caught by the rear wheel of a truck at the age of 3, and she suffered from spinal cord injury completely paralyzed below the 5th thoracic vertebra. She spent her childhood life in a nursery for the physically handicapped

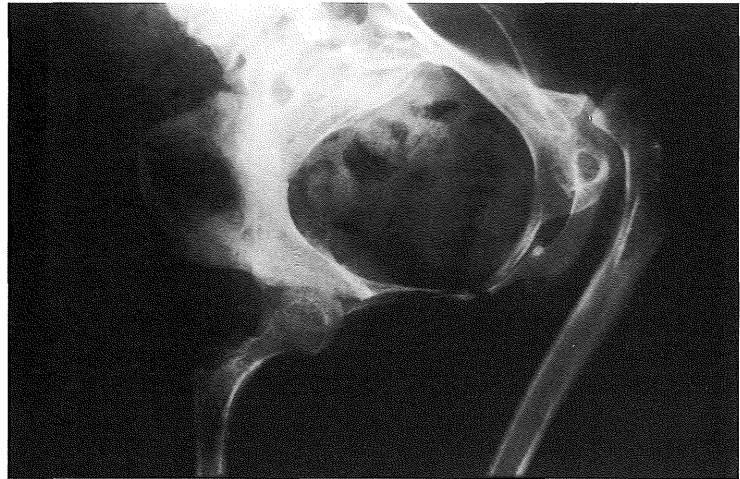
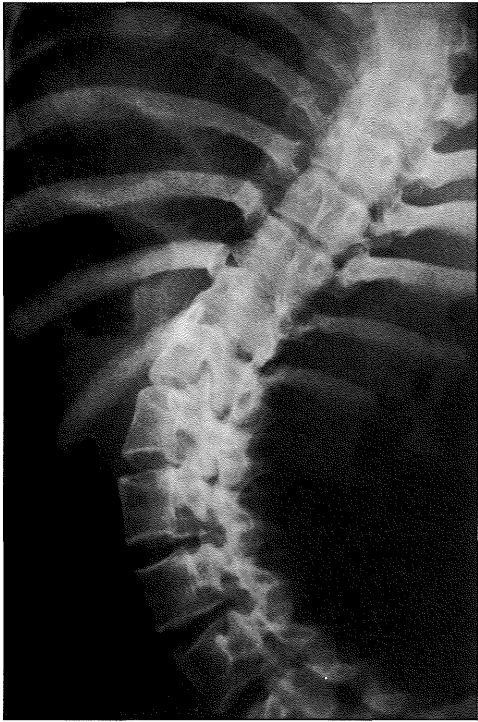


Fig. 4. Case 2 – spinal deformity, dislocation of hip, and pelvic tilt revealed.

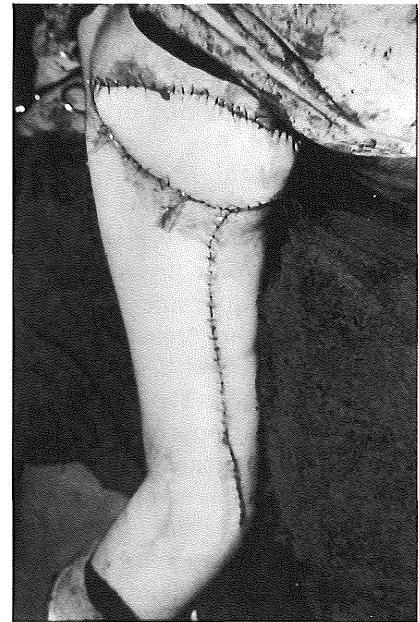
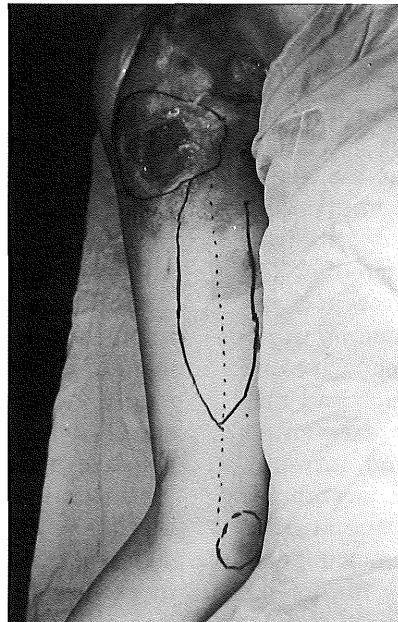
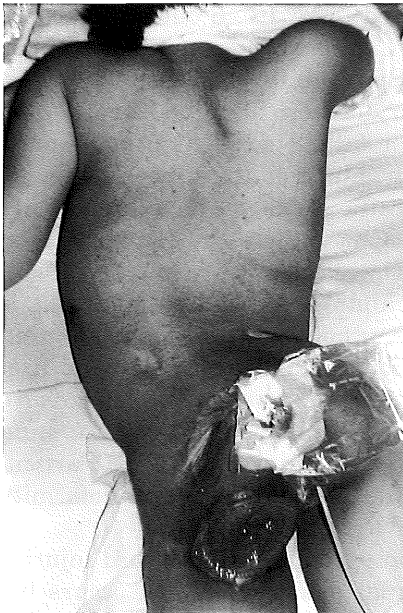


Fig. 5. Case 2 – pressure sore operation was conducted with use of gracilis muscle cutaneous flap.

children. She now works in printing and book-binding at a vocational training center. After the age of 17, a pressure sore arose at the left ischium, and the symptom has been alternately ameliorated and aggravated since then. When she underwent a medical examination at the age of 19, she had a pressure sore of 10×10 cm at the left ischium, with the left ischium and the left femur exposed and with the anus and the perineum shifted to the upper posterior part of the hip. The operation of the pressure sore was conducted by means of necrotomy, irrigation, and

use of the gracilis as a muscle cutaneous flap. After the operation, she was provided with a sheet socket for a wheelchair, but mild epidermal ablation recurred several times. While she still now uses a ROHO cushion, no recurrence of the pressure sore has been observed for past 8 years since the operation.

Pulmonary function tests revealed 2,100 ml of vital capacity and 86% of FEV_{1.0}%. Her upper extremities exhibited normal muscle force, but her lower extremities showed remarkable deformity and atrophy. Roentgenogram revealed a pelvic

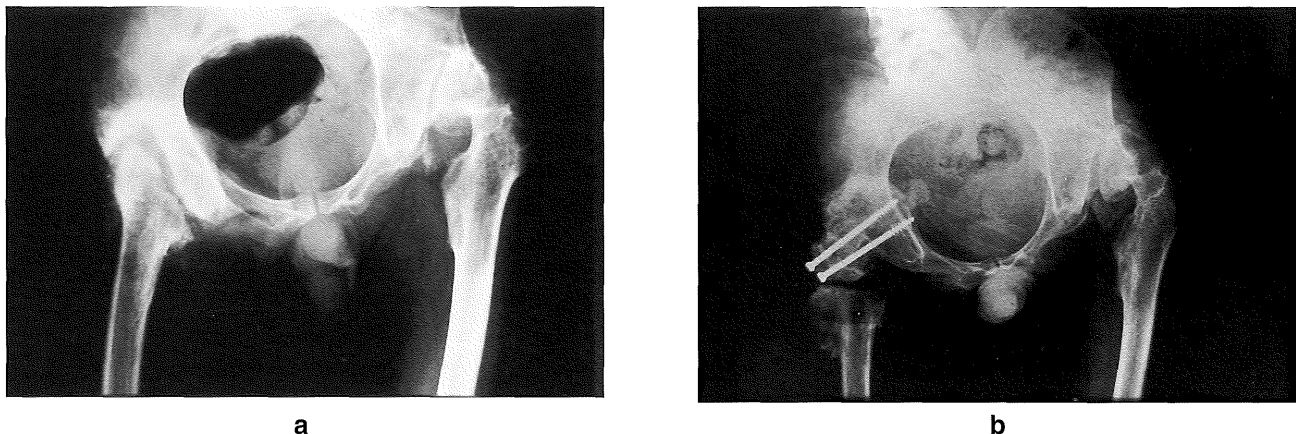


Fig. 6. Case 3 – a: before the operation, b: after the operation

tilt, acetabular dysplasia, dislocation of the hip joint, and severe spinal deformity. An X-ray film of the spine showed a left-concave lateral curvature with a Cobb angle of 70° . Because of an abnormality at the orifice of the urinary tract, self-catheterization was impossible and a residual balloon has been placed inside. No urological abnormality has been observed as yet.

Case 3 38-year-old male car allocator (Fig. 6)

When the patient fell from a cliff at the age of 5, he suffered complete spinal cord injury with the 10th thoracic vertebra dislocated and fractured. In 1975 a pressure sore occurred at the left ischium, and since then he underwent 7 operations for the pressure sore. Pulmonary function tests revealed 2,800 ml of vital capacity and 85% of FEV_{1.0}%. The upper extremities had normal muscle strength, but the lower extremities exhibited remarkable deformity and atrophy. Roentgenogram revealed pelvic tilt, acetabular dysplasia, dislocation of the hip joint, suppurative coxarthrosis, disappearance of the femoral head, and severe spinal deformity. An X-ray film of the spine showed a left-convex lateral curvature having a Cobb angle of 50° with the 9th thoracic vertebra as the top vertebra. At the age of 29, an operation for the pressure sore over the left ischium was performed with an advance muscle flap using a VY flap from the hamstrings, but the pressure sore relapsed 3 months later. At the age of 30, in the operation for his pressure sore using a muscle cutaneous flap by means of necrotomy, irrigation, and the gracilis, an osteotomy was performed at the shaft of the femur and a membrane of silicone and coxopexy interposed to produce a pseudarthrosis. The pressure sore has not occurred for past 8 years since using a ROHO cushion.

DISCUSSION

While the incidence of spinal cord injury in children is reported to be a only few percent¹⁻⁴), its manifestation is uncommon in babies. Its incidence is reported to be 9.4% in USA, 1.25% in Australia, and 5% in Switzerland. The incidence in Japan is reported to be 1%, 6 out of 396 cases of children below 13 years of age spinal cord injuries at the Sogo Spinal Injuries Center.

Spinal cord injury is most likely to be caused by traffic accidents or falling accidents, and reportedly even by birth injury at the time of delivery. Cases involving traffic accidents have been either injured while in a moving vehicle or have been hit by a car while walking.

In the case of children, as well as adults, it is important to take prophylactic steps in children against complications in the respiratory and urological systems and against symptoms of pressure sores, heterotopic ossification, contracture, and spasm associated with spinal cord injury. Particular attention should be paid to spinal deformity and dislocation of the hip joint.

One complication specific to spinal cord injuries in children is spinal deformity which occurs before the growth spurt. It is certain to occur in cases of injury at or above the 10th thoracic vertebrae. The younger the child at the time of injury, the higher the incidence and the more serious the deformity. The usual aim of treatment is to retard progress of the deformity and to resort to surgery if the deformity is excessive. For prophylactic purposes, patients are restricted from sitting until the vertebral column becomes supportable by itself, and are encouraged to use a Perthes trolley rather than a wheelchair, so that they can remain prone while moving around. In daily life, however, they are likely to use a wheelchair more often as they are growing up, and in fact the use of a wheelchair is inevitable in their school age from elementary school through junior high and senior high schools. Use

of a spinal orthosis and therapeutic exercise to retard progression of the deformity are not always effective. To treat serious spinal deformity, surgery is preferred as the most effective approach, but the accompanying risks should be taken into account. We should realize, therefore, that it is clearly difficult to take appropriate measures for prevention and treatment of spinal deformity secondary to spinal cord injury in children. Spinal deformity and pelvic tilt are causal factors of pressure sores, as well as of restricted respiratory function and ADL limitation, so care should always be taken to prevent pressure sores.

In spinal cord injury in children, the hip joint undergoes reduced muscle strength due to paralysis, muscular imbalance due to spasm, coxa valga due to no load of body weight, secondary insufficiency in cap formation, and pelvic tilt until it is ultimately dislocated. Treatment to prevent further progress includes normalization of the pelvic tilt, lying prone, removal of hip joint flexion and internal rotation contractures, and extension of lower extremities, and use of an abduction orthosis. Surgical procedures involve adductor tenotomies, nerve blocks, tendon transfers, intertrochanteric osteotomies, and other such measures.

Conclusion

In the rehabilitation of children with spinal cord injuries, particular attention should be paid

to specific problems that are intertwined with the growing process. Since motor dysfunction prevents these children from doing enough exercise to stimulate mental growth, they cannot have adequate learning experiences and their sociability may be inhibited as a consequence. It is important to make long-term observations of such cases in the light of features specific to spinal cord injuries in children. Particular attention should be focused on spinal deformity and dislocation of the hip joint.

ACKNOWLEDGEMENT

The authors would like to thank Professor Paul D. Andrew for his kind assistance in this manuscript.

(Received September 8, 1995)

(Accepted January 25, 1996)

REFERENCES

1. **Allen, J.P.** 1976. Spinal cord injury at birth. p.155-173. *In* P.J. Vinken and G.W. Bruyn(eds.), Handbook of Clinical Neurology, Vol.25. North-Holland and Publishing, Amsterdam.
2. **Burke, D.C.** 1974. Traumatic spinal cord paralysis in children. *Paraplegia* **11**: 268-276.
3. **Gehrig, K. and Michaelis, L.S.** 1968. Statistics of acute paraplegia and tetraplegia on a national scale. *Paraplegia* **6**: 93-95.
4. **Kewalrmini, L.S., Orth, Y.S., Kraus, J.F. and Sterling, H.M.** 1980. Acute spinal cord lesions in a pediatric population. *Paraplegia* **18**: 206-219.