

Abdominal Aorta and Visceral Arteries Visualized by Transgastric Echocardiography: technical considerations

Kazumasa ORIHASHI, Yuichiro MATSUURA, Taijiro SUEDA, Hiroo SHIKATA,
Satoru MORITA, Shinji HIRAI, Masafumi SUESHIRO and Kenji OKADA

*First Department of Surgery, Hiroshima University School of Medicine, Kasumi 1-2-3, Minami-ku,
Hiroshima, 734 JAPAN*

ABSTRACT

Despite the necessity of information regarding the abdominal aorta and visceral arteries during cardiovascular surgery, there has been no intraoperative modality available. We examined the feasibility and limitations of transesophageal echocardiography (TEE) for this purpose. In 21 consecutive patients, the celiac artery (CEA), superior mesenteric artery (SMA), and left and right renal arteries (LRA, RRA) were examined with TEE, and could be visualized in 21 cases (100%), 20 cases (95.2%), 14 cases (66.7%) and 14 cases (66.7%), respectively. Several attempts were needed for successfully visualizing the LRA and the RRA in 2 and 1 case(s), respectively. Three specific manipulations of the probe were helpful for visualizing these vessels: 1) an appropriate counterclockwise rotation and an upward flexion of the probe when the transducer entered the stomach; 2) a stiffening of the flexible portion of the probe at the position of upward flexion by fixing the handle of the TEE probe when the transducer was advanced; and 3) a lateral flexion of the probe to provide a rotation of the image in either the clockwise or counterclockwise direction and to optimize the assessment of the blood flow velocity in the branch artery. Inferior visualization of the renal arteries was a limitation of this method. Two solutions for this problem were 1) repeated attempts at visualization and 2) an examination of the blood flow in the renal parenchyma with color Doppler imaging. Because of possible damage to the gastric wall, it is recommended that this maneuver be conducted by an experienced sonographer.

Key words: *Visceral artery, Transesophageal echocardiography, Abdominal aorta, Surgery*

In aortic surgical patients, an involvement of the abdominal aorta and visceral arteries is not uncommon. A progression of dissection after preoperative diagnosis or a new development of dissection after cardiac surgery may occur^{4,5)} as well as a change in the blood flow pattern during the operation^{3,6)}. During cardiac surgery, pathologic changes in the abdominal aorta may be problematic in the case of an unscheduled placement of intraaortic balloon pumping or an arterial cannula via the femoral artery. However, thorough examination of the abdominal aorta on a routine basis is not practical.

Although transesophageal echocardiography (TEE) has proved to be useful for the diagnosis of aortic disease¹⁾, we have hesitated to examine the abdominal aorta because both the benefit and the safety of manipulating the TEE probe in the stomach has been unclear. Recently we have found that the celiac artery (CEA) can be visualized in more cases than we expected. Keen et al²⁾

showed that the abdominal aorta and its branch arteries could be successfully visualized when the surgeon grasped the TEE probe in the stomach and manipulated it. However, to our knowledge, there has been no report of visualizing the abdominal aorta and visceral arteries by the conventional manipulation of transesophageal approach of TEE. Thus, in this study, we examined the incidence of successful visualization, technical problems, limitations, and pitfalls of this method in a series of cases undergoing cardiovascular surgery.

MATERIALS AND METHODS

Twenty-one consecutive cases undergoing cardiac and/or aortic surgery were examined after an additional six cases in this period were excluded because sonographer was not available. They included 13 men and 8 women, with ages ranging from 52 to 76 years. The surgical procedures included aortic repair in 7, valve surgery in

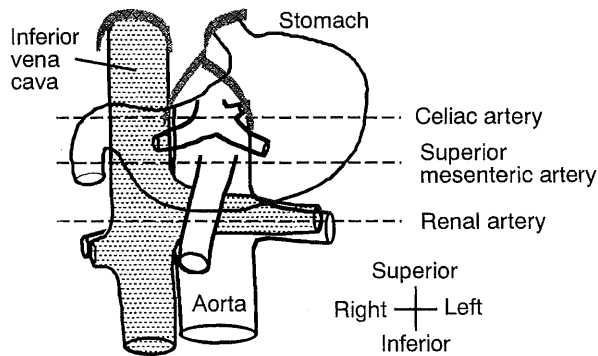


Fig. 1. Schematic illustration of the spatial relationship between the stomach and each vessel. The stomach lies over the abdominal aorta. The dotted lines indicate the level for visualizing each visceral branch.

6, coronary artery bypass surgery in 6 cases, and closure of an atrial septal defect with maze operation and pericardiectomy in one case each.

A 5 MHz biplane TEE system (EUB-555, EUP-ES322, Hitachi Co. Inc., Tokyo, Japan) was used and the data were recorded on S-VHS videotapes. Observation of the abdominal aorta and visceral arteries was added to the routine intraoperative monitoring and was carried out by a single sonographer in every case.

The abdominal aorta and branch arteries were visualized by advancing the transducer from the position where it depicted the descending thoracic aorta. The transverse scan was mainly used and the longitudinal scan was occasionally used, ori-

ented by the image of the former. Each branch artery was identified based on the following criteria according to the anatomical facts (Fig. 1).

- 1) The first major branch below the diaphragm is CEA.
- 2) The second branch is the superior mesenteric artery (SMA).
- 3) The CEA is divided into branches near its origin.
- 4) The SMA courses along the aorta and has no major branch near its orifice.
- 5) The right and left renal arteries (RRA and LRA) arise from the aorta distally to the CEA and SMA.
- 6) The left renal vein traverses between the aorta and SMA.

When the artery could not be visualized at the first attempt, several further attempts were made after the transducer was withdrawn to the esophagus. When unusual resistance was felt in advancing the transducer, it was not further advanced, but the probe was withdrawn at once.

RESULTS

No manifest complication related to the manipulation of the probe in the stomach was experienced in this series.

As the transducer was advanced from the esophagus into the stomach, the aorta moved toward the right and away from the transducer on the screen, and was often scanned obliquely. It was necessary to rotate the probe counterclockwise with an upward flexion of the probe tip to keep the image of the aorta within the screen. The vertebra which had been depicted at the 4

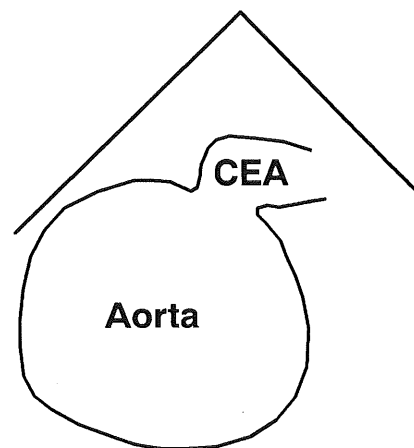
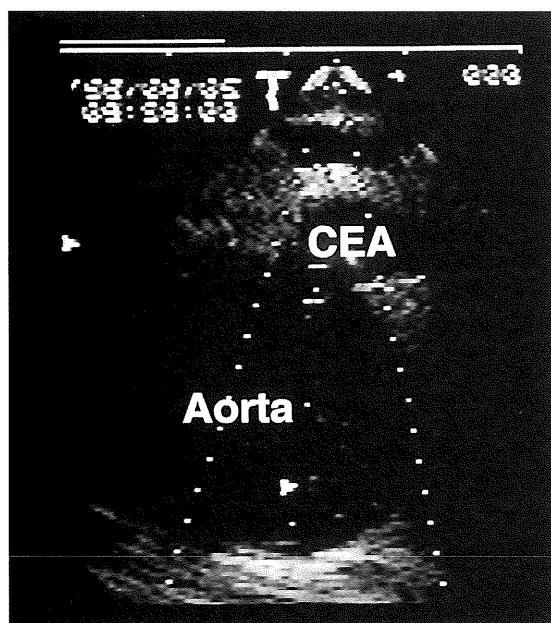


Fig. 2. Echogram (transverse scan) of the celiac artery (CEA) arising from the aorta from the 1 o'clock position. An upward and leftward flexion of the probe is applied for visualizing the CEA. It divides into branches soon after. The bright area in the lumen indicates the blood flow in color Doppler mode.

o'clock position of the aorta moved to the 8 o'clock position. The aorta usually led off to the CEA around this level, often at the 1 to 3 o'clock position (Fig. 2).

As the transducer was further advanced by 1 or 2 cm, the SMA appeared in a similar direction (Fig. 3), often through the pancreas. The SMA stayed near the aorta as the transducer was further advanced, depicted in the short axis, while the CEA had already divided into branches and moved away from the aorta. When the scanning plane was switched to the longitudinal scan at

this level, the CEA and SMA were depicted as arising from the aorta serially (Fig. 4), the former nearly perpendicularly to the aorta while the latter rose obliquely and coursed along the aorta below the pancreas and splenic vein.

In the transverse scan, the course of the CEA and SMA was nearly perpendicular to the ultrasonic beam, and a leftward flexion of the probe was helpful for rotating the image, moving the branches toward the 12 o'clock position of the aorta and their course nearly parallel to the ultrasonic beam.

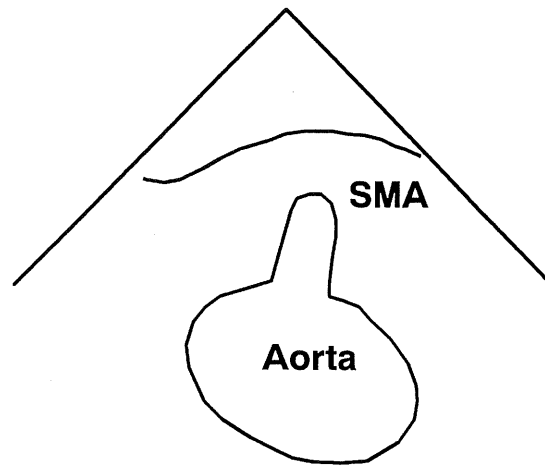
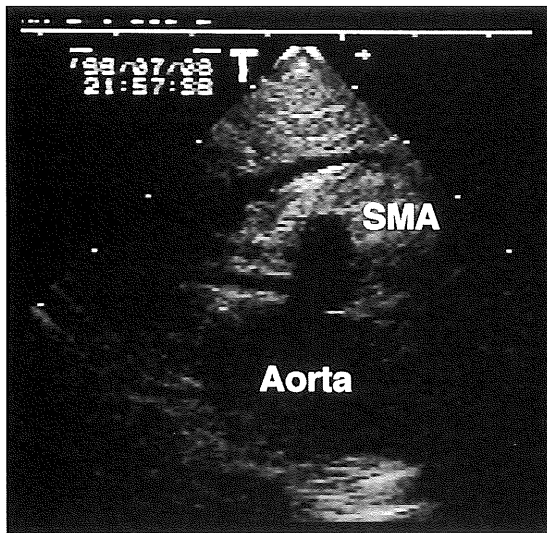


Fig. 3. Echogram (transverse scan) of the superior mesenteric artery (SMA) arising from the aorta at the 12 o'clock position.

An upward and leftward flexion of the probe is applied.

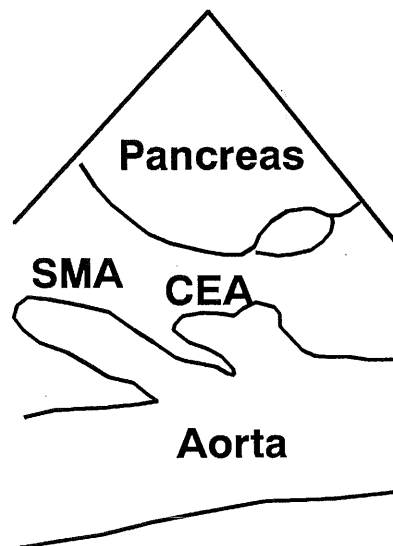
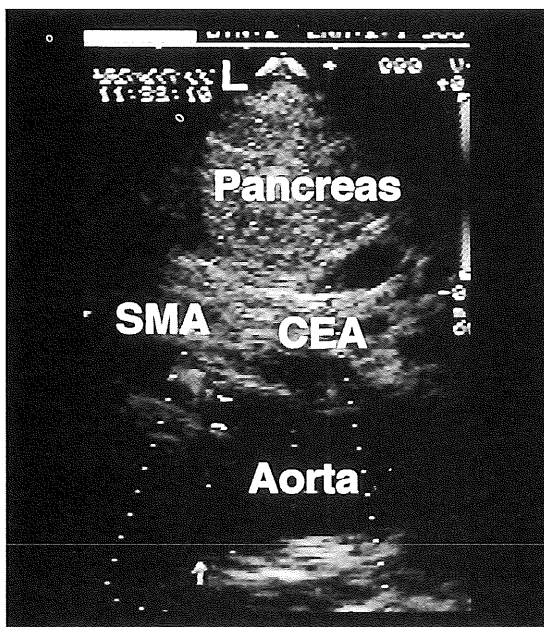


Fig. 4. Echogram (longitudinal scan) of the celiac artery (CEA) and superior mesenteric artery (SMA) arising from the aorta.

The pancreas is depicted over the CEA and SMA.

As the transducer was further advanced from the SMA level, the left renal vein appeared, traversing between the SMA and aorta, and entered the inferior vena cava which was depicted to the right of the aorta. The LRA was visualized around this level, often at around the 8 o'clock position of the aorta, just below the left renal vein on the screen (Fig. 5). The RRA was found at the opposite side of the aorta to the LRA, with its orifice closely below the inferior vena cava (Fig. 6). A lateral flexion of the probe was often helpful for visualizing the RRA, although the

image was often blurred by the noise, such as acoustic shadow or reverberations. At this level, some resistance was occasionally felt in advancing the probe and the image of the aorta was skewed, resulting in an oblong image. In several cases, the whole length of the LRA was visualized from the aorta to the hilus of the left kidney.

The CEA, SMA, LRA, and RRA could be visualized in 21 cases (100%), 20 cases (95.2%), 14 cases (66.7%), and 14 cases (66.7%). Every artery visualized fulfilled the criteria described above. Several attempts were needed for successfully

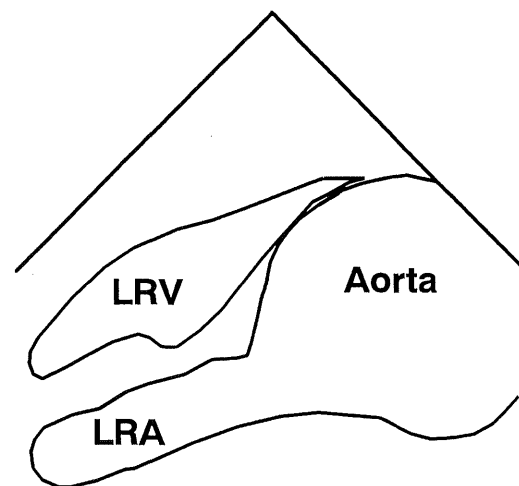
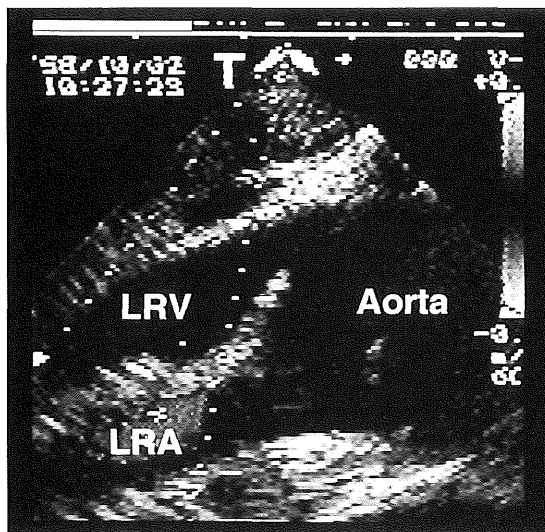


Fig. 5. Echogram (transverse scan) of the left renal artery (LRA) arising from the aorta at the 8 o'clock position. The LRA courses along the left renal vein (LRV). In this case, an intimal flap is depicted in the aortic lumen. Blood flow in the lumen is depicted as a bright area.

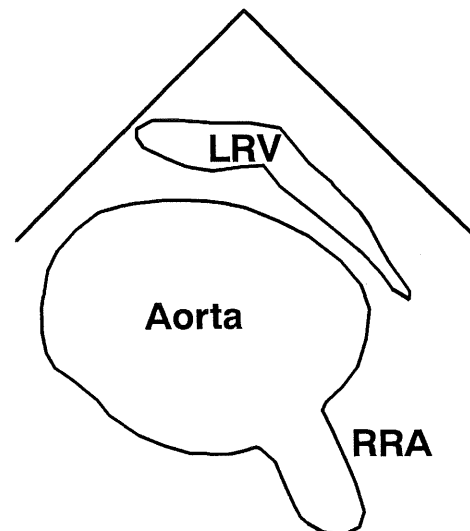
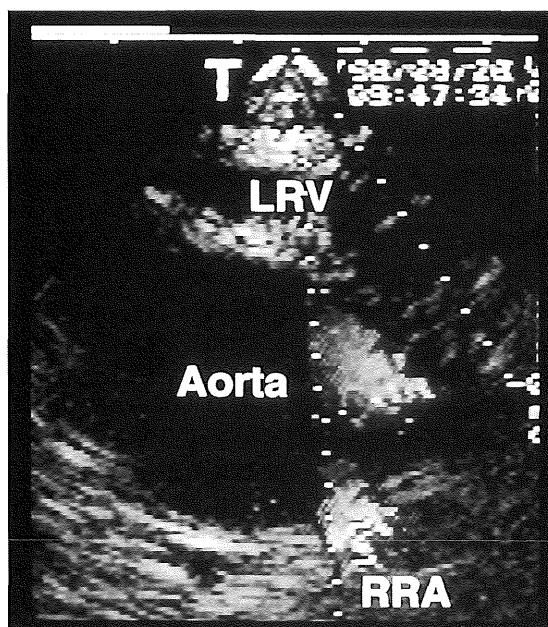


Fig. 6. Echogram (transverse scan) of the right renal artery (RRA) arising from the aorta at the 5 o'clock position. The left renal vein (LRV) is depicted traversing over the aorta.

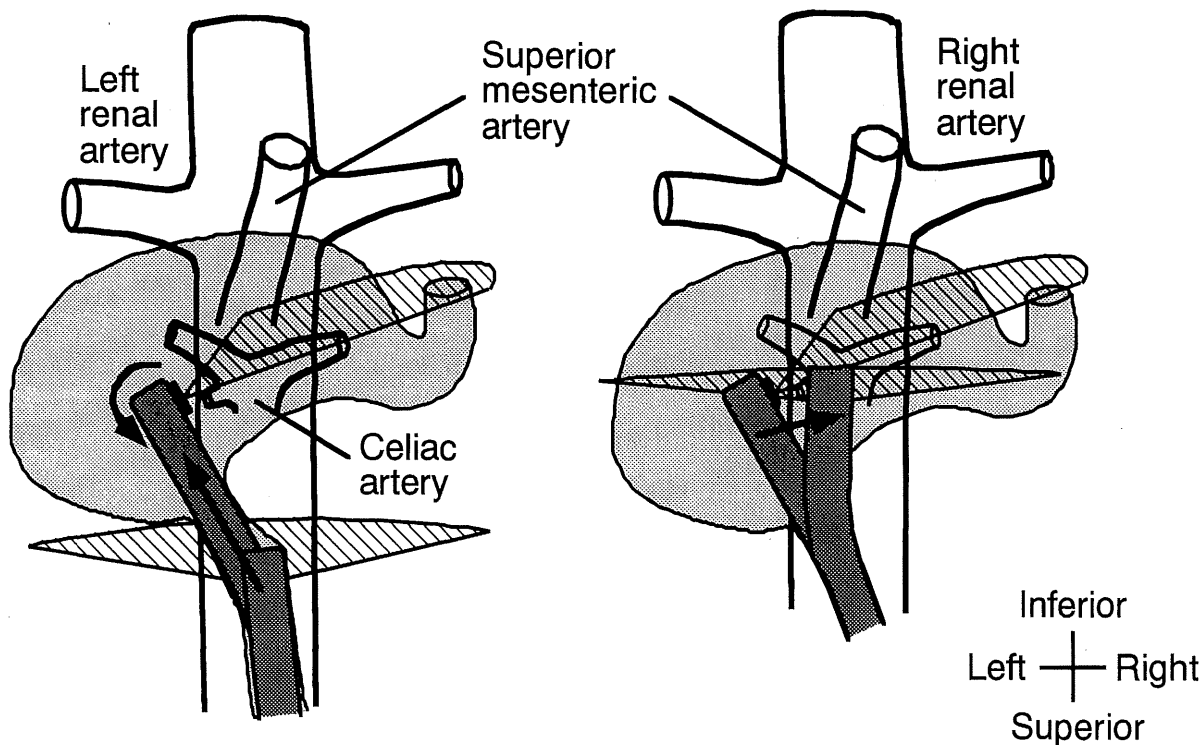


Fig. 7. Schematic illustration of manipulation of the probe in the stomach, drawn from the orientation of the sonographer.

The probe is directed toward the left anterior as it passes the cardia (left figure; scanning plane (a) to (b)), and needs to be rotated counterclockwise (left figure: scanning plane (b) to (c)) and bent upward with a slight clockwise rotation (right figure: scanning plane (c) to (d)) in order to keep the aorta in the screen.

visualizing the LRA and the RRA in 2 and 1 case(s), respectively.

DISCUSSION

Visualization of the CEA and SMA by means of TEE was feasible in nearly every patient and that of the renal arteries in two thirds of the patients. However, they could not be visualized by simply advancing the transducer into the stomach. The aorta moved toward the right and away from the transducer on the screen, probably because the probe was deviated toward the left-anterior when it passed through the cardia (Fig. 7). A manipulation needed at this point was to apply an appropriate counterclockwise rotation and an upward flexion of the probe so that the transducer could be situated close to the aorta.

The second manipulation required was to stiffen the flexible portion of the probe at the position of upward flexion by fixing the handle of the TEE probe when the transducer was advanced. This keeps the transducer close to the aorta and in contact with the gastric wall, and avoids a passive bending along the larger curvature of the stomach (Fig. 8). The latter situation leads to an oblique or long-axis view of the aorta in the transverse scan, making it difficult to identify each branch artery and to further advance the transducer.

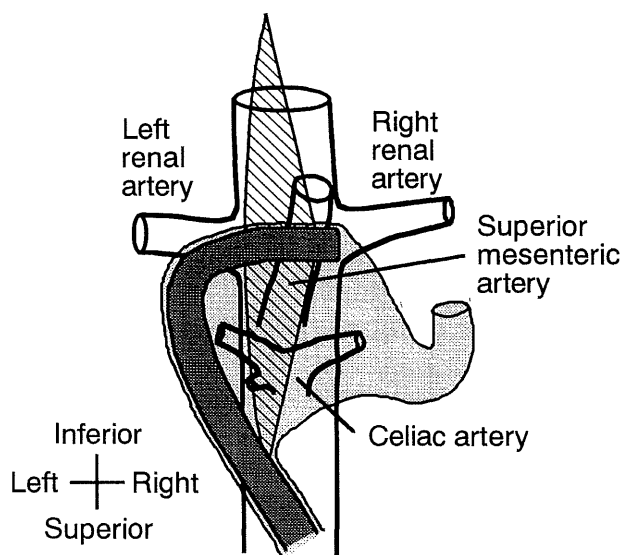


Fig. 8. Schematic illustration of the passive bending of the probe along the larger curvature of the stomach.

The aorta is scanned obliquely or in its long axis. The renal arteries cannot be scanned in the long axis in this situation.

The third manipulation required was to use the lateral flexion of the probe appropriately (Fig. 9). This provided a rotation of the image in either a

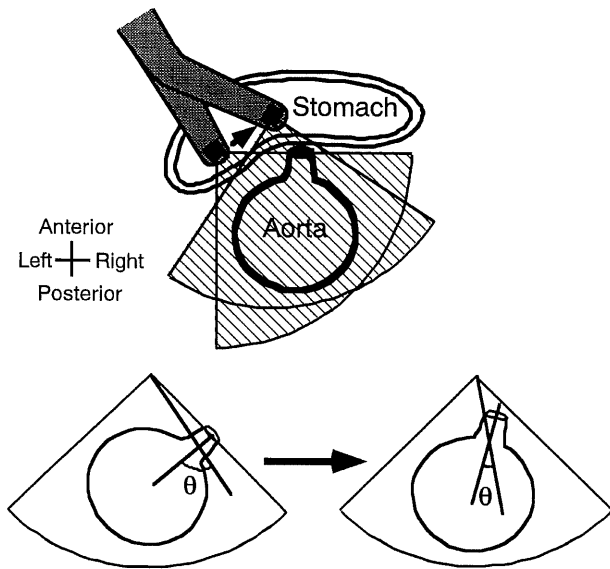


Fig. 9. Schematic illustration showing the effect of leftward flexion of the probe for optimizing the Doppler measurements. The image of the aorta rotates counterclockwise and the angle between the course of the artery and ultrasonic beam (θ) is reduced.

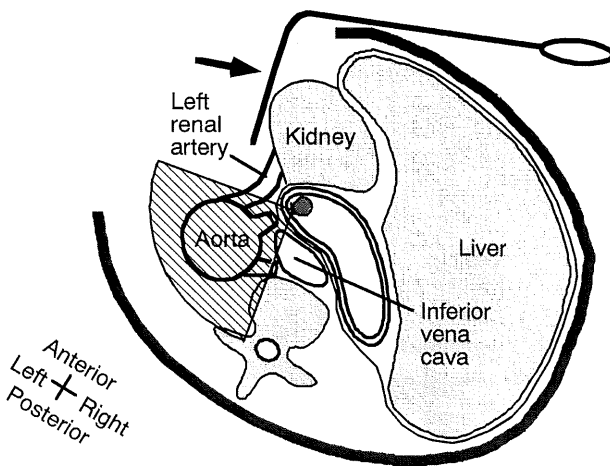


Fig. 10. Schematic illustration showing the influence of retracting the visceral organs toward the right during repair of the thoracoabdominal aorta. The aorta and visceral arteries are close to the stomach where the transducer is situated. Note that the visualization of vessels is feasible in this situation.

clockwise or counterclockwise direction and enabled the location of the CEA and SMA at the 12 o'clock position and the RRA and LRA at the 4 to 6 and 10 to 11 o'clock position, respectively, making the course of these arteries as parallel to the ultrasonic beam as possible. This optimizes an assessment of the blood flow velocity in the branch artery.

These manipulations did not interfere with the

surgical procedures, even in the case of thoracoabdominal aorta repair. While both the visceral organs, including the stomach, and the TEE transducer were retracted toward the right of the patient, the visceral arteries were situated close to the stomach and remained visualized (Fig. 10).

However, we failed to visualize the renal artery in one-third of the cases despite every effort with these manipulations. This result is apparently inferior to that of Keen et al. who could visualize the renal artery in 23 of 24 cases²⁾. As the transducer was advanced, resistance was encountered and the image of the aorta was skewed, as the transducer was probably hampered by the gastric wall. This seems to be determined by the spatial relationship between the stomach and branch arteries and to occur often in obese patients, probably because the stomach is compressed toward the diaphragm by the visceral organs. Under laparotomy, these visceral organs can be displaced and the transducer can be properly manually placed as long as the gastric wall is extended. However, this is a limitation of our method. We have two means of solution for this problem. Repeated attempts may lead to a successful visualization as was achieved in visualizing the three renal arteries in this series. The course of the probe might be altered in such an instance. Another solution is to examine the blood flow in the renal parenchyma with color Doppler imaging.

Damage to the gastric wall can be caused by an aggressive manipulation of the probe in the stomach. We consider that the maneuver of visualizing the abdominal aorta should be conducted by a sonographer who has much experience in TEE or endoscopic examination and can correctly assess the resistance in advancing the transducer. The sonographer in this series was familiar with endoscopy and met no apparent gastrointestinal complications.

In conclusion, visualization of the abdominal aorta and visceral arteries down to the renal arteries is feasible, although several specific techniques of manipulating the probe are needed. A further investigation is needed to evaluate the clinical implication of this method in a larger series.

(Received August 28, 1997)

(Accepted December 5, 1997)

REFERENCES

1. Erbel, R., Mohr-Kahaly, S., Rennollet, H., Brunier, J., Drexler, M., Wittlich, N., Iversen, S., Oelert, H., Thelen, M. and Meyer, J. 1987. Diagnosis of aortic dissection: The value of transesophageal echocardiography. *Thorac. Cardiovasc. Surg.* **35**: 126-133.
2. Keen, R.R., Yao, J.S., Astleford, P., Blackburn, D. and Frazin, L.J. 1996. Feasibility of transgastric ultrasonography of the abdominal

- aorta. *J. Vasc. Surg.* **24**: 834–842.
3. **Neustein, S.M., Lansman, S.L., Quintana, C.S., Suriani, R., Ergin, A. and Griep, R.B.** 1993. Transesophageal Doppler echocardiographic monitoring for malperfusion during aortic dissection repair. *Ann. Thorac. Surg.* **56**: 358–361.
 4. **Ohashi, Y., Onishi, Y., Akamatsu, T., Maruyama, K. and Kuro, M.** 1996. Aortic dissection after weaning from extracorporeal circulation. *Masui* **45**: 1281–1284.
 5. **Ozaki, S., Toyama, M., Kawase, I. and Horimi, H.** 1996. Successful surgical treatment of intraoperative aortic dissection complicating aortic valve replacement. *Nippon Kyobu Geka Gakkai Zasshi* **44**: 1022–1026.
 6. **Yamada, E., Matsumura, M., Kimura, S., Kyo, S., Ueda, K., Yokote, Y. and Omoto, R.** 1997. Usefulness of transesophageal echocardiography in detecting changes in flow dynamics responsible for malperfusion phenomena observed during surgery of aortic dissection. *Am. J. Cardiol.* **79**: 1149–1152.