

Cine Magnetic Resonance Imaging, Computed Tomography and Ultrasonography in the Evaluation of Chest Wall Invasion of Lung Cancer

Michiya YOKOZAKI¹⁾, Shigeru NAWANO²⁾, Kanji NAGAI³⁾,
Noriyuki MORIYAMA²⁾, Tetsuro KODAMA³⁾ and Yutaka NISHIWAKI³⁾

1) Second Department of Internal Medicine, Hiroshima University School of Medicine

2) National Cancer Center Hospital East, Division of Radiology

3) National Cancer Center Hospital East, Division of Thoracic Oncology

ABSTRACT

Purpose: To assess the usefulness of cine-magnetic resonance imaging (cine-MRI) in the evaluation of chest wall invasion, we compared the results of cine-MRI with those of computed tomography (CT) and ultrasonography (US).

Materials and Methods: Eleven patients were examined who had no pain and who were difficult to diagnose by routine examinations. MRI was performed with a Magnetom SP/4000, 1.5T unit (Siemens, Germany). For cine imaging, continuous turbo-FLUSH (ultra fast low angle shot) images were obtained at an orthogonal section to the chest wall during slow deep breathing. A CT scan was performed using a TCT 900S or Super Helix (Toshiba, Japan) at 1 cm intervals, with section thicknesses of 1 cm throughout the entire chest. US was performed with a model SSA-270A (Toshiba, Japan) with 7.5-MHz linear array scanners (PLF-705S; Toshiba, Japan).

Results: Sensitivity, specificity and accuracy were 67%, 75% and 73% for cine MRI, 67%, 63% and 64% for CT, 33%, 75% and 64% for US, respectively.

Conclusions: These results indicate that cine MRI is potentially useful for the diagnosis of chest wall invasion of lung cancer.

Key words: MRI, CT, US, Lung neoplasms

Chest wall invasion occurs in 5–8% of patients with lung cancer^{2,9,10,14}). In 1947, Coleman first reported long-term survival in patients with lung cancer invading the chest wall after treatment by combined pulmonary and chest wall resection²⁾. Since then, there have been many reports of combined pulmonary and chest wall resections with 2 to 15% mortality and 30–40% 5-year survival rates^{1,3,5,9,15,16,20}). In patients with chest invasion and without lymph node metastasis, Piehler et al¹⁵⁾ reported that the 5-year survival was 53.7%. The survival curves of those patients and patients with T2N0M0 disease were remarkably similar, with no significant difference. It is now thought feasible to treat patients with chest wall invasion and no lymph node metastasis surgically¹⁶⁾. Therefore, information about chest wall invasion is still an important factor in the clinical decision to perform surgery.

Cine magnetic resonance imaging (cine-MRI) can now make high speed images. In cine-MRI, images

are taken every 1.2 sec during deep breathing and videorecorded consecutively, clearly visualizing the movement of the tumor. We examined the possibility of the usefulness of cine-MRI in the evaluation of chest wall invasion of lung cancer, comparing it with conventional CT and US. This paper reports the results of our study.

MATERIALS AND METHODS

A total of 178 lung cancer patients underwent surgery at our hospital between November 1993 and January 1995. We selected patients whose tumors were considered to possibly invade the chest wall, based on the result of chest roentgenograms. We ruled out patients whose tumors were clearly apart from the chest wall or obviously invaded ribs, as shown on chest CT. As a result, 11 patients, all of whom had no pain, were examined. The histologic type of the tumor of these 11 patients consisted of 4 adenocarcinomas, 3 squamous cell carcinoma and 4 adenosquamous

Address for galley proofs, correspondence and requests for reprints:

Michiya Yokozaki

Second Department of Internal Medicine, Hiroshima University School of Medicine, 1-2-3 Kasumi, Minami-ku, Hiroshima 734, Japan

carcinomas. Three of the 11 cases had undergone preoperative cisplatin based chemotherapy. All 11 cases were evaluated by these three modalities within 1 month before operation.

MRI was performed with a Magnetom SP/4000, 1.5T unit (Siemens, Germany). Axial T1-weighted spin-echo (SE) images were obtained to determine the location of the tumor after intravenous administration of 0.1 mmol/kg gadopetate dimeglumine (Magnevist; Schering, Germany). Continuous turbo-FLASH (ultra fast low angle shot) images were obtained at an orthogonal section to the chest wall during slow deep breathing. The section thickness was 1 cm throughout the tumor. The matrix was 128 by 128. Acquisition time per image was 1.2 sec. Eight to ten images, including deep inspiration and deep expiration, were consecutively videorecorded. One of the authors (S.N.) evaluated chest wall invasion according to the respiratory movement of the tumor on cine-MRI.

A CT scan was performed using a TCT 900S or Super Helix (Toshiba, Japan) at 1 cm intervals, with section thicknesses of 1 cm throughout the entire chest. Intravenous contrast material was used in all cases. Chest wall invasion was evaluated mainly according to the presence of an extrapleural fatty layer on CT. If it was difficult to judge the presence of the fatty layer, we also looked at the characteristics of the interface of the lesion with the adjacent pleural surface. A sharp interface of the lesion with the adjacent pleural surface was interpreted as negative and an obtuse interface was interpreted as positive. If the lesion had no fatty layer and the interface was sharp, it was evaluated as positive.

The US instrument used in this study was a SSA-270A (Toshiba) with 7.5-MHz linear array scanners (PLF-705S; Toshiba). The coupling medium was a water-soluble ultrasound transmission gel (Sono Jelly; Toshiba) applied to the skin,

with or without a water path. One of the authors (M.Y.) analyzed the relationship of the tumor and the chest wall. Chest wall invasion was diagnosed mainly according to the respiratory movement of the tumor during US.

Surgical and histopathological findings were recorded according to the General Rules for Clinical and Pathological Records of Lung Cancer of the Japan Lung Cancer Society (Table 1)⁷⁾. We also recorded the depth of cancer invasion to the pleura and chest wall according to Mishina's microscopic classification as described below¹⁰⁾.

p3a: Cancer that extended to the parietal pleura.

p3b: Cancer that did not extend beyond the subpleural fatty tissue.

p3c: Cancer that did not extend beyond the intercostal muscle.

p3d: Cancer that extended to the rib

Table 1. Surgical and histopathologic findings of chest wall invasion according to the General Rules for Clinical and Pathological Record of Lung Cancer of the Japan Lung Cancer Society⁷⁾

Surgical findings	
P0	No pleural or chest wall invasion.
P1	Limited invasion into the visceral pleura.
P2	Cancer present on the surface of the visceral pleura.
P3	Invasion into the visceral and parietal pleura.
Histopathological findings	
p0	Cancer did not extend beyond the elastic membrane of the visceral pleura.
p1	Cancer reached the elastic membrane of the visceral pleura.
p2	Cancer present on the surface of the visceral pleura.
p3	Cancer invaded the chest wall or mediastinum.

Table 2. Preoperative evaluation, surgical findings and pathological findings in judgment of chest wall invasion

Case No.	Location	CT	US	cine MRI	Surgical*	Pathological†
1.	lt. lower	-	-	-	(P0)	(p0)
2.	rt. upper	-	-	-	(P1)	(p2)
3.	lt. upper	-	-	-	(P1)	(p1)
4.	rt. lower	-	-	-	(P0)	(p1)
5.	rt. lower	-	-	-	(P1)	(p2)
6.	lt. lower	+	+	+	(P3)	(p3b)
7.¶	lt. upper	+	+	+	(P3)	(p2)
8.¶	rt. upper	+	+	+	(P3)	(p0)
9.¶	rt. upper	+	-	-	(P3)	(p3a)
10.	lt. upper	-	-	+	(P1)	(p3a)
11.	rt. upper	+	-	-	(P1)	(p1)

* According to General Rules for Clinical and Pathological Record of Lung Cancer of the Japan Lung Cancer Society.

† According to Mishina's microscopic classification of the depth of invasion into the pleura and chest wall.

¶ Induction chemotherapy cases

RESULTS

The preoperative evaluation of the three modalities, surgical findings and pathological findings are summarised in Table 2. Five patients (cases 1 to 5) were evaluated preoperatively as negative for chest wall invasion on all three modalities, and the pathological findings also showed no invasion (Fig. 1). One patient (case 6) was evaluated as positive on all three modalities and was also positive pathologically but the tumor did not extend beyond the subpleural fatty tissue. Cases 7 and 8, which had undergone induction chemotherapy, were evaluated as positive for invasion in all three modalities, but, pathologically, they had only granulomatous fibrous adhesion to the chest wall. It was suspected that the cancer had invaded the chest wall before the induction chemotherapy. In the remaining three cases, differ-

ent evaluations were obtained by different modalities (Fig. 2).

Table 3 shows the sensitivity, specificity and accuracy of the three modalities and surgical findings. In each category, cine-MRI obtained a higher rate than CT and US, and the results of cine-MRI were approximately equivalent to those of the surgical findings.

DISCUSSION

Preoperative evaluation of chest wall invasion of lung cancer is important for selection of adequate treatment. Routine examinations such as chest roentgenogram and tomography provide limited evaluation of the chest wall invasion in cases of lung cancer. Conventional CT has been used for this purpose, but several authors have reported low accuracy in prediction of the chest

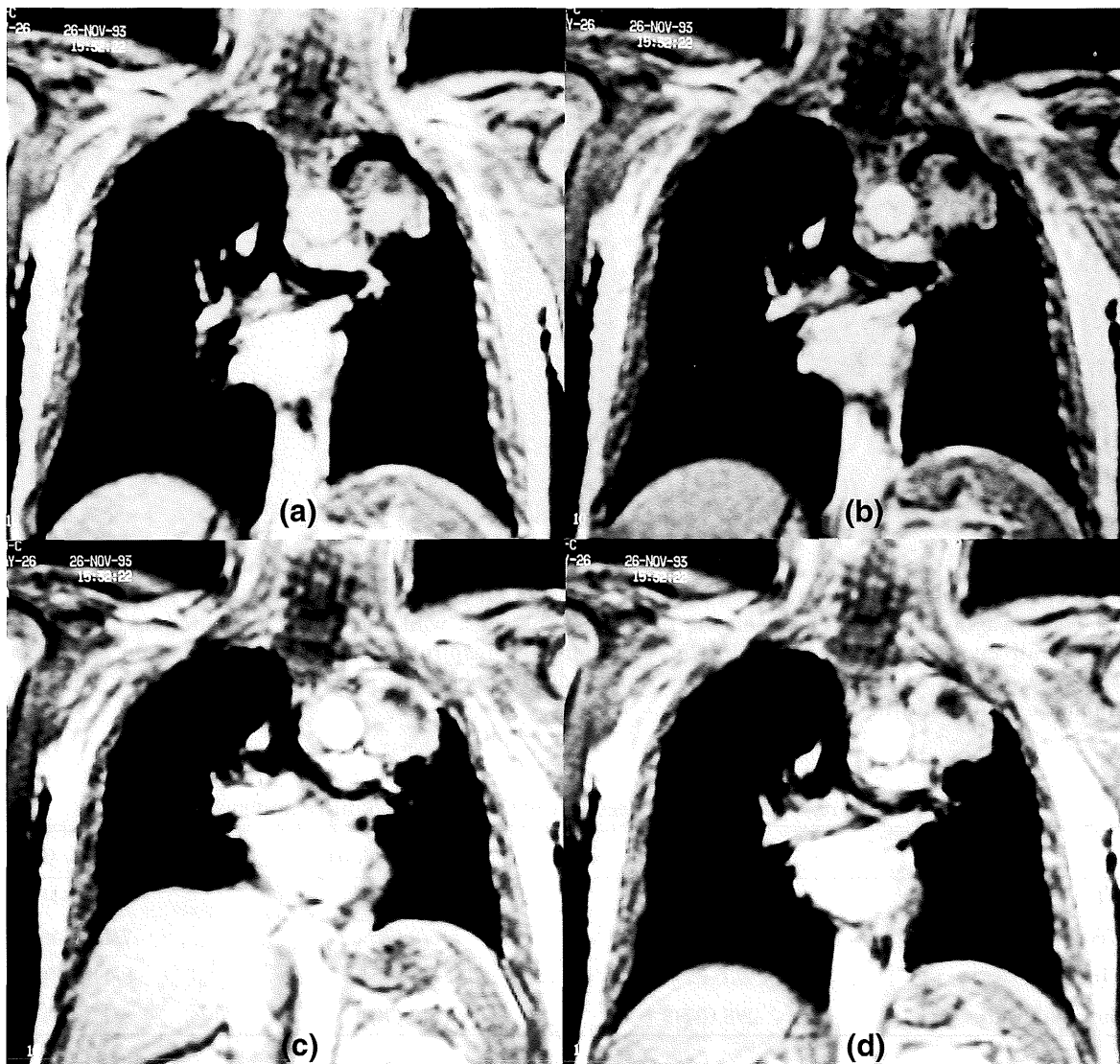


Fig. 1. Adenosquamous carcinoma of the left upper lobe in a 67-year-old man (case 3). (a) to (d) cine-MRI within a cycle of respiration. (a) cine-MRI on deep inspiration. (c) cine-MRI on deep expiration. The tumor moved smoothly apart from the chest wall in cine-MRI. Histologically, there were no chest wall invasion.

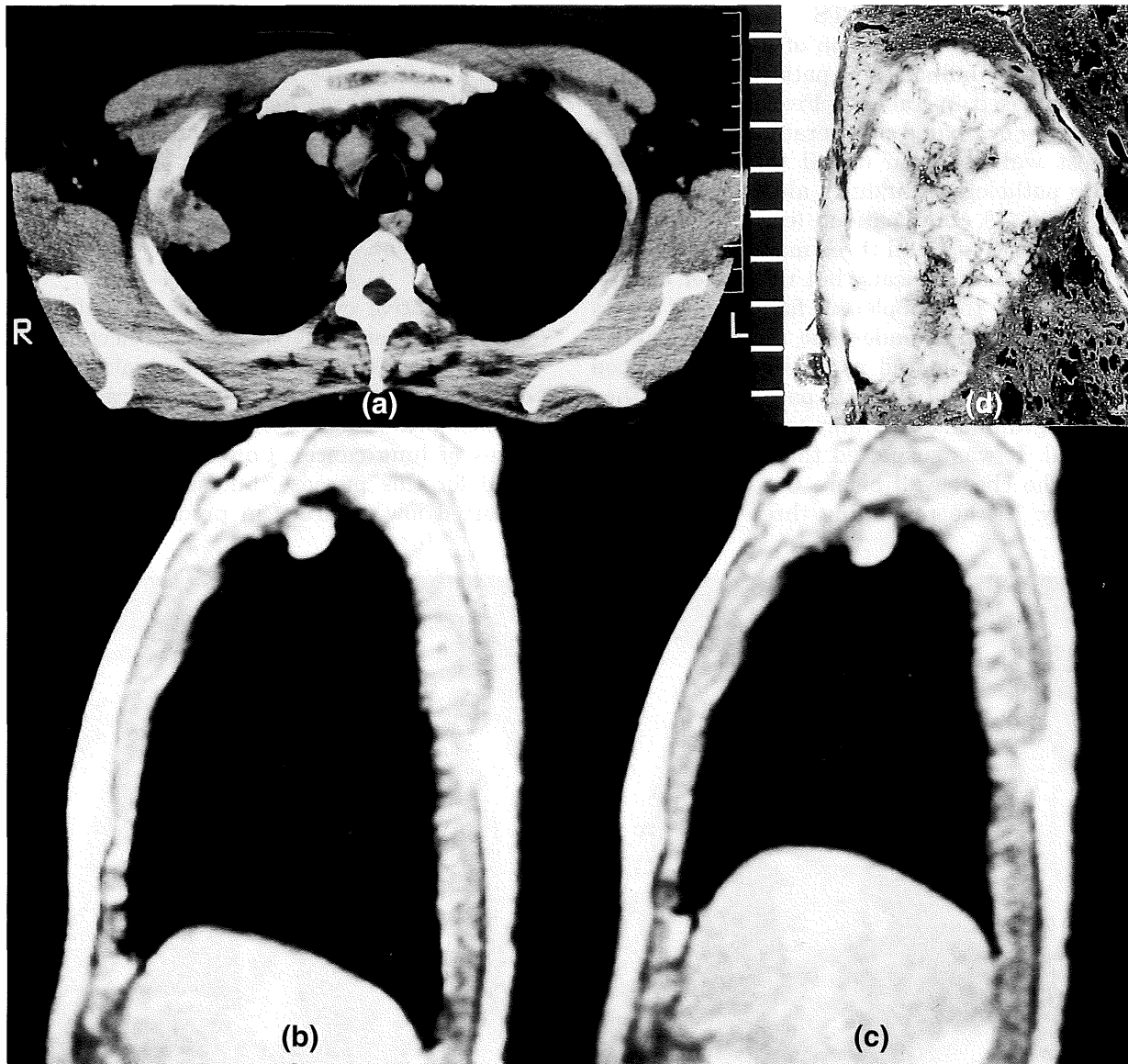

Fig. 2. Adenocarcinoma of left upper lobe in a 59-year-old man (case 10).

(a) There was a fatty plane between the tumor and the chest wall and it was evaluated as negative for chest wall invasion following CT. (b) Cine-MRI on deep inspiration. (c) Cine-MRI on deep expiration. They revealed no respiratory movement of the tumor. (d) Lobectomy specimen. Pathologically, adenocarcinoma extended to the parietal pleura.

Table 3. Sensitivity, specificity and accuracy of the three modalities and surgical findings

	sensitivity (%)	specificity (%)	accuracy (%)
CT	2/3 (67)	5/8 (63)	7/11 (64)
US	1/3 (33)	6/8 (75)	7/11 (64)
Cine MRI	2/3 (67)	6/8 (75)	8/11 (73)
Surgical findings	2/3 (67)	6/8 (75)	8/11 (73)

wall invasion^{4,14,17,22}). Therefore, new modalities have been reported including conventional MRI^{6,12,13}, pneumothorax CT^{21,23}, three dimensional helical CT⁸, US^{18,19}, and multisection expiratory dynamic CT (ED-CT)¹¹.

While the usefulness of conventional MRI in the evaluation of chest wall invasion in lung cancer has been reported^{6,12,13}, the Radiographic Diagnostic Oncology Group found no difference between CT and MRI⁴.

Yokoi et al reported that the accuracy of pneumothorax CT was 100% in the evaluation of chest wall invasion²³). However, this technique is invasive, and symptomatic pneumothorax occurred in four of 43 patients.

US^{18,19}, ED-CT¹¹) and cine-MRI are dynamic evaluation techniques using the characteristics of organs that change their size and shape during the respiration cycle. Suzuki et al reported very high sensitivity (100%) and specificity (98%) of US for chest wall invasion¹⁸). Although US has advantages in being able to evaluate soft tissue in real time, some skill is needed to describe the tumor findings on US because acoustic windows are needed. Three dimensional helical CT⁸) and ED-CT¹¹) using helical CT technique have been reported to be useful, but both results were preliminary. Furthermore, in CT, to distinguish between benign, firm, fibrous adhesion and malignant invasion may be possible but very difficult. Concerning MRI, Padvani et al reported that contrast medium uptake revealed no chest wall invasion in comparison with non-contrast-enhanced T1-weighted images¹³). However, we did not compare contrast with non-contrast enhanced MRI, which is being carried out in large number of patients. Fluoroscopic observation is also important to evaluate the movement of the tumor. However, because various lung and chest wall structures overlap with the tumor, the contrast resolution of fluoroscopy can be minimal.

Despite our study being small and preliminary, it showed that the results of cine-MRI were more favorable in the evaluation of chest wall invasion than CT or US, and that they were almost the same as the results of the surgical findings. This indicates that cine-MRI is potentially useful in establishing a correct diagnosis of chest wall invasion.

ACKNOWLEDGEMENTS

The authors thank Prof. Michio Yamakido, MD. of Second Department of Internal Medicine, Hiroshima University School of Medicine for his encouragement during this study and we also thank Kiyoshi Mukai, MD. for providing pathologic data. This work was supported in part by Grants-in-Aid for Cancer Research from the Ministry of Health and Welfare and by a SRF Grant for Biomedical Research.

(Received December 11, 1996)

(Accepted April 7, 1997)

REFERENCES

1. **Burnard, R.J., Martini, N. and Beattie, E.J.** 1974. The value of resection in tumors involving the chest wall. *J. Thorac. Cardiovasc. Surg.* **68**: 530-535.
2. **Coleman, F.P.** 1947. Primary carcinoma of the lung with invasion of the ribs: pneumonectomy and simultaneous block resection of the chest wall. *Ann. Surg.* **126**: 156-168.
3. **Geha, A.S., Bernatz, P.E. and Woolner, L.B.** 1967. Bronchogenic carcinoma involving the thoracic wall Surgical treatment and prognostic significance. *J. Thorac. Cardiovasc. Surg.* **54**: 394-402.
4. **Glazer, H.S., Duncun-Mayer, J., Aronberg, D.J., Moran, J.F., Levitt, R.G. and Sagel, S.S.** 1985. Pleural and chest wall invasion in Bronchogenic carcinoma: CT evaluation. *Radiology* **157**: 191-194.
5. **Grillo, H.C., Greenberg, J.J. and Wilkins, E.W.** 1966. Resection of bronchogenic carcinoma involving thoracic wall. *J. Thorac. Cardiovasc. Surg.* **51**: 417-421.
6. **Hagger, A.M., Pearlberg, J.L., Froelich, J.W., Hearshen, D.O., Beute, G.H., Lewis, J.W., Schkudor, G.W., Wood, C. and Gniewek, P.** 1986. Chest-wall invasion by carcinoma of the lung: detection by MR imaging. *AJR* **148**: 1075-1078.
7. **Hitomi, S., Ayabe, K., Ikeda, S., Ishihara, T., Kusajima, K., Kobayashi, S., Goya, T., Maeda, M., Mizuno, T. and Watanabe, H.** 1995. Description manual for lung cancer surgery, p. 73-87. *In* General rule for clinical and pathological record of lung cancer, 4th ed. The Japan Lung Cancer Society, Chiba.
8. **Kuriyama, K., Tateishi, R., Kumatani, T., Kodama, K., Doi, O., Hosomi, N., Sawai, Y., Inoue, E., Kadota, T., Narumi, Y., Fujita, M. and Kuroda, C.** 1994. Pleural invasion by peripheral bronchogenic carcinoma: assessment with three-dimensional helical CT. *Radiology* **191**: 365-369.
9. **McCaughan, B.C., Martini, N., Bains, M.S. and McCormack, P.M.** 1985. Chest wall invasion in carcinoma of the lung: therapeutic and prognostic implications. *J. Thorac. Cardiovasc. Surg.* **89**: 836-841.
10. **Mishina, H., Suemasu, K., Yoneyama, T., Naruke, T., Miyazawa, N., Shimosato, Y. and Ogata, T.** 1978. Surgical pathology and prognosis of the combined resection of chest wall and lung in lung cancer. *Jpn. J. Clin. Oncol.* **8**: 161-168.
11. **Murata, K., Takahashi, M., Mori, M., Shimoyama, K., Mishina, A., Fujino, S., Itoh, H. and Morita, R.** 1994. Chest wall and mediastinal invasion by lung cancer: evaluation with multisection expiratory dynamic CT. *Radiology* **191**: 251-255.
12. **Musset, D., Grenier, P., Carette, M.F., Frija, G., Hauuy, M.P., Desbleds, M.T., Girard, P., Bogot, J.M. and Lallemand, D.L.** 1986. Primary lung cancer staging: prospective comparative study of MR imaging with CT. *Radiology* **160**: 607-611.
13. **Padovani, B., Mouroux, J., Seksik, L., Chanalet, S., Sedat, J., Rotomondo, C., Rochelme, H. and Serres, J.J.** 1993. Chest wall invasion by bronchogenic carcinoma; evaluation with MR imaging. *Radiology* **187**: 33-38.
14. **Pennes, D.R., Glazer, G.M., Wimbish, K.J., Gross, B.H., Long, R.W. and Orringer, M.B.** 1985. Chest wall invasion by lung cancer:

- Limitation of CT. *AJR*. **144**: 507-511.
15. **Piebler, J.M., Pairolero, P.C., Weiland, L.H., Offord, K.P., Payne, W.S. and Bernatz, P.E.** 1982. Bronchogenic carcinoma with chest wall invasion: factors affecting survival following en Bloc resection. *Ann. Thorac. Surg.* **34**: 684-691.
 16. **Ratto, G.B., Piacenza, G., Frola, C., Musante, F., Serrano, I., Giua, R., Salio, M., Jacovoni, P. and Rovoda, S.** 1991. Chest wall involvement by lung cancer: computed tomographic detection and results of operation. *Ann. Thorac. Surg.* **51**: 182-188.
 17. **Scott, I.R., Müller, N.L., Miller, R.R., Evance, K.G. and Nelems, B.** 1988. Resectable stage III lung cancer: CT, surgical, and pathological correlation. *Radiology* **166**: 75-79.
 18. **Suguma, Y., Tamaki, S. and Kitamura, S.** 1988. Ultrasonographic evaluation of pleural and chest wall invasion of lung cancer. *Chest* **93**: 275-279.
 19. **Suzuki, N., Saito, T. and Kitamura, S.** 1993. Tumor invasion of chest wall in lung cancer: diagnosis with US. *Radiology* **187**: 39-42.
 20. **Trastek, V.F., Pairolero, P.C., Piebler, M.P., Weiland, L.H., O'Brien, P.C., Payne, W.S., Payne, W.S. and Bernatz, P.E.** 1984. En Bloc (non-chest wall) resection for bronchogenic carcinoma with parietal fixation. *J. Thorac. Cardiovasc. Surg.* **87**: 352-358.
 21. **Watanabe, A., Shimokata, K., Saka, H., Nomura, F. and Sakai, S.** 1991. Chest CT combined with artificial pneumothorax: value in determining origin and extent of tumor. *AJR*. **156**: 707-710.
 22. **Webb, W.R., Gatsonis, C., Zerhouni, E.A., Heelan, R.T., Glazer, G.M., Francis, I.R. and Macneil, B.J.** 1991. CT and MR imaging in staging non-small cell bronchogenic carcinoma: report of the radiologic diagnostic oncology group. *Radiology* **178**: 705-713.
 23. **Yokoi, K., Mori, K., Miyazawa, N., Saito, Y., Okuyama, A. and Sasagawa, M.** 1991. Tumor invasion of the chest wall and mediastinum in lung cancer: evaluation with pneumothorax CT. *Radiology* **181**: 147-152.