

## Laparoscopic Cholecystectomy in a Patient on Continuous Ambulatory Peritoneal Dialysis

Masanobu IKEDA<sup>1)</sup>, Yorimitsu TATSUKAWA<sup>2)</sup>, Hiroshi YAHATA<sup>3)</sup>, Kei KOIDE<sup>4)</sup>,  
 Atsuo KIMURA<sup>5)</sup> and Toshimasa ASAHARA<sup>3)</sup>

1)Department of Surgery, National Sanatorium Yanai Hospital, Japan

2)Department of Surgery, Sanyo Hospital, Japan

3)Second Department of Surgery, Hiroshima University School of Medicine, Japan

4)Department of Surgery, National Sanatorium Hiroshima Hospital, Japan

5)Department of Surgery, Yoshijima Hospital, Japan

### ABSTRACT

The patient was a 72-year-old man who was receiving continuous ambulatory peritoneal dialysis (CAPD) with a diagnosis of chronic renal failure. Although his response to dialysis therapy was favorable, right hypochondralgia and fever occurred, and gallstones were detected by abdominal ultrasonography and computed tomography. Drip-infusion cholangiography (DIC) revealed neither dilation nor calculus in the common bile duct. The patient was diagnosed as having acute cholecystitis and cholecystolithiasis and, in consideration of his general condition, laparoscopic cholecystectomy was carried out. Pneumoperitoneum was performed through a CAPD tube, and a 10 mm-trocar was carefully introduced through a supraumbilical incision so as not to injure the CAPD tube. Since intraoperative cholangiography showed a condition similar to preoperative DIC, only cholecystectomy was undertaken. The postoperative course was uneventful, with neither postoperative hemorrhage nor leakage of dialysate from the wound.

**Key words:** CAPD, Cholecystolithiasis, Laparoscopic cholecystectomy

Laparoscopic cholecystectomy is being actively employed for cholelithiasis, enabling a reduction in postoperative pain, early suspension of confinement to bed and a shortening of the hospitalization period. In our hospital, painful cholelithiasis was observed in a patient undergoing treatment by continuous ambulatory peritoneal dialysis (CAPD) for chronic renal failure, and laparoscopic cholecystectomy was performed. To our knowledge, there have been few reports on laparoscopic cholecystectomy in CAPD patients<sup>1-3)</sup>. We therefore consider the present case to be noteworthy, and discuss the relevant findings with reference to the literature.

### CASE REPORT

The patient was a 72-year-old man whose chief complaint was dyspnea. He was diagnosed on chest X-ray films as having congestive heart failure, and was admitted to the department of internal medicine of a local hospital for conservative treatment. His dyspnea was relieved thereafter, but a mild pre-existing renal dysfunction gradually worsened, and it was difficult to control blood pressure because of severe hypertension. Thus, the patient was admitted to our hospital.

### Results of laboratory testing on admission:

BUN was 99.1 mg/dl and Cr was 7.0 mg/dl, showing severe renal dysfunction. The erythrocyte count was  $251 \times 10^4/\text{mm}^3$ , Hb was 7.4 g/dl and Ht was 22.7 %, showing severe anemia. T.P. was 6.0 g/dl, also showing hypoproteinemia (Table 1). From these findings, the patient was diagnosed as having chronic renal failure, renal anemia, and hypertension.

As the patient was judged to require hemodialysis, hemodialysis was introduced immediately after admission. The patient underwent hemodial-

**Table 1.** Results of laboratory testing on admission

WBC	7000/mm <sup>3</sup>	T.Bil.	0.1 mg/dl
RBC	$251 \times 10^4/\text{mm}^3$	GOT	21 IU/liter
Hb.	7.4 g/dl	GPT	10 IU/liter
Ht.	22.7 %	LDH	437 IU/liter
Plt.	$19.5 \times 10^4/\text{mm}^3$	ALP	114 IU/liter
BUN	99.1 mg/dl	LAP	49 IU/liter
Cr.	7.0 mg/dl	$\gamma$ -GTP	7 IU/liter
Na	134 mEq/liter	T.P.	6.0 g/dl
K	2.8 mEq/liter	A/G	0.62
Cl	90 mEq/liter	FBS	147 mg/dl
Ca	7.3 mg/dl	PTH-C	0.6 ng/ml
P	5.4 mg/dl	$\beta_2$ -MG	16.1 mg/liter

ysis seven times in total. A decrease in ST on electrocardiograms (ECG) was observed, and ultrasonography of the heart revealed a slightly diminished movement of the septal wall. Since an old myocardial infarction was suspected from these findings, the hemodialysis was changed to CAPD, taking the load on the circulatory system into consideration.

The course after changing to CAPD was favorable, but right hypochondrialgia and a slight fever appeared. Tenderness localized to the right hypochondrial region was observed, as an abdominal finding. A hematological study revealed a leukocyte count of  $10,100/\text{mm}^3$  and C-reactive protein (+), indicating slight inflammation. Abdominal ultrasonography showed a high-echo image with an acoustic shadow in the gallbladder, and the presence of calculi was confirmed. Abdominal computed tomography showed a high-density area in the gallbladder, and cholecystolithiasis was observed, as on the ultrasound. Drip-infusion cholangiography (DIC) showed two images of calculi, each of which was about 1.2 cm in diameter. There was neither dilation nor any calculus in the common bile duct.

From these findings, the patient was diagnosed as having acute cholecystitis and cholecystolithiasis. Although the patient was at high risk, laparoscopic cholecystectomy was undertaken, because the symptom of right hypochondrialgia had not been relieved.

**Operative findings:** Under general anesthesia, pneumoperitoneum was performed through a CAPD tube. After adequate pneumoperitoneum (8–10 mm Hg) had been confirmed, a skin incision was made above the umbilicus, and under sufficient hemostasis, the fascia and peritoneum were excised. Then, a trocar of 10 mm in diameter was inserted for laparoscopy. The pneumoperitoneum was re-routed to this trocar, and skin incisions were then made in the median, right hypochondrial and right lateral region, in that order (Fig. 1(1)). Trocars were inserted into each site. The intraoperative cholangiography revealed neither dilation nor calculus in the common bile duct, as in the preoperative DIC. Therefore, only cholecystectomy was performed. After sufficient hemosta-

sis had been confirmed, the site of insertion of the 10 mm-diameter trocar was sutured bilaminarily, and the site of the 5 mm-diameter trocar was sutured monolaminarily (Fig. 1(2)). The excised gallbladder showed histopathological findings of chronic cholecystitis.

**Postoperative course:** CAPD was reinitiated immediately after the operation. For one day postoperatively, infusion and drainage of dialysate (Dianeal® PD-2, 1.5%, 1000 ml) containing 60 mg of tobramycin or 1 ml of heparin were repeated at 1- to 2-hour intervals. Tobramycin or heparin was added within 4 days after the operation. The frequency of change in the dialysate was 6–7 times within 6 days after the operation, 5 times within 10 days after the operation and 4 times from 10 days after the operation. There was neither hemorrhage nor leakage of dialysate from the wound postoperatively, and oral ingestion was started from the first postoperative day. There were no problems and the course was favorable.

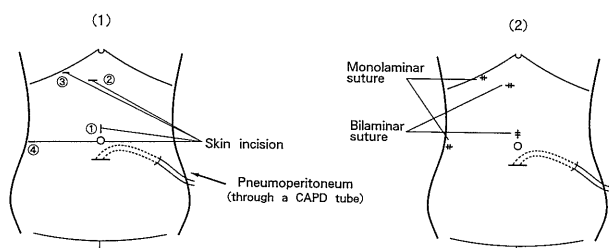
## DISCUSSION

The majority of cholecystectomies have been performed laparoscopically since clinical reports were first published in 1989–1990, because laparoscopic cholecystectomy has certain advantages (reduction in pain without laparotomy, cosmetic value, shortening of the admission period, and early return to social activities). However, there have been almost no reports on high risk patients, such as those undergoing dialysis for chronic renal failure. We performed laparoscopic cholecystectomy on a CAPD patient, who, as a result, had a very good postoperative course. Certain problems with the procedure will now be discussed.

One problem is that of maintaining sufficient pneumoperitoneum. In the present patient, the initiation of pneumoperitoneum through a CAPD tube facilitated safe and secure pneumoperitoneum maintenance during laparoscopic cholecystectomy. However, since the visual field was reduced by foam formation occurring from a lateral stoma of the CAPD tube, the route of pneumoperitoneum was changed to above the umbilicus.

It is also well-known that careful attention must be given to intraoperative hemostasis in patients with chronic renal failure, because the hemorrhagic tendency is marked in such cases. Our patient, fortunately, showed only a slight hemorrhagic tendency, probably because the treatment was changed to CAPD soon after the induction of hemodialysis. Even so, the inflammation due to cholecystitis was severe. We therefore proceeded with the operation more cautiously while maintaining careful hemostasis.

It is important to avoid leakage of dialysate through the wound suture. According to Breyer et al<sup>11</sup>, the site of insertion of a 10-mm trocar was sutured in a bilaminar manner. Following this



**Fig. 1.** Laparoscopic cholecystectomy((1) Start (2) End)

procedure, we first sutured the fascia and peritoneum together, followed by dermal suture. Thus, no leakage of dialysate was observed postoperatively.

There are various opinions concerning the time when CAPD should be restarted. According to Speck et al<sup>3)</sup>, CAPD should be terminated until the morning of the day following the operation, and thereafter CAPD should be conducted 6 times within 3 days after the operation. The frequency of the subsequent CAPD should be 4 times. With our patient, we were concerned about the possibility that the inside of the tube would be obstructed by opaque dialysate, which might occur when CAPD was restarted. Therefore, we started CAPD after the operation, and the dialysate was frequently exchanged. Fluid leakage was not observed, and the opacity in the dialysate had disappeared completely on the 10th day postoperatively. We added heparin to the dialysate within 4 days after the operation, on the basis of the results of discontinuation, because of a slightly hemorrhagic dialysate. The duration of heparin administration should be further investigated.

In laparoscopic cholecystectomy for CAPD patients, safe and secure pneumoperitoneum is possible through the CAPD tube. Sufficient hemostasis and careful progression during the operation are necessary, because such patients show a marked hemorrhagic tendency and have weakened tissues. These characteristics should be further investigated in more patients.

(Received August 29, 2000)

(Accepted October 12, 2000)

#### REFERENCES

1. **Breyer, J.A. and Chaudhry, A.** 1992. Laparoscopic cholecystectomy in an ambulatory peritoneal dialysis patient: a case report. *Perit. Dial. Int.* **12**: 73-75.
2. **Mutter, D., Marichal, J.F., Petitjean, P., Vix, M., Evrard, S. and Marescaux, J.** 1992. Protection of the catheter used in peritoneal dialysis in patients with chronic renal failure. Contribution of laparoscopic surgery. *Presse. Med.* **21**: 1584.
3. **Speck, R., Glattli, A., Czerniak, A., Uehlinger, D. and Horber, F.F.** 1992. Laparoscopic cholecystectomy in a patient on continuous ambulatory peritoneal dialysis. *Clin. Nephrol.* **38**: 238.