

## Laparoscopic Cholecystectomy: Experience with 150 consecutive patients in Kurashiki

Keisuke HAMAZAKI<sup>1)</sup> and Masao KUROSE<sup>2)</sup>

1) Department of Surgery, Kurashiki Medical Center, Japan

2) Department of Surgery, Fukuwatari Hospital, Japan

### ABSTRACT

One hundred and fifty consecutive patients who underwent laparoscopic cholecystectomy (LC) in Kurashiki between March 1991 and December 1997 were studied in order to examine intraoperative procedures, and complications, especially with regard to bile duct injuries and acute cholecystitis, furthermore postoperative management. Nine out of the 150 cases were converted to open cholecystectomy, so that the overall success rate was 94%. One hundred and forty-six patients (97%) presented on an elective basis, and the remaining four patients were admitted as acute cholecystitis. One hundred and forty-four patients had gallbladder stones. All of seven patients had adenomyomatosis with stones (4 cases) and without stones (3 cases). Nine patients had benign polyps of the gallbladder with stones (6 cases) and without stones (3 cases). Seven patients with choledocholithiasis were treated successfully with endoscopic sphincterotomy preoperatively. In six out of eight patients with acute cholecystitis, among whom 4 were treated preoperatively with percutaneous transhepatic gallbladder aspiration (PTGBA), LC was conducted.

Major complications included 3 cases of bile duct injuries (2%). Twenty cases (14) of bleeding encountered during operation were controlled easily under laparoscopy. Postoperative oral feeding was started in nearly all cases on the 1st postoperative day.

In conclusion, LC seems to offer significant advantages to patient recovery but attention to bile duct injury and the judgement for the timing of conversion to open cholecystectomy is considered necessary for a successful LC.

**Key words:** Laparoscopic cholecystectomy (LC), Acute cholecystitis, Bile duct injury

Initial reports demonstrate that LC offers remarkable advantages over open cholecystectomy, namely the minimal invasiveness of the procedure, early return to normal activity, and improved cosmetic results<sup>4,5)</sup>.

Thereafter, LC rapidly became a popular alternative to open cholecystectomy. As the number of LCs increased, problems accompanied by LC were uncovered<sup>12)</sup>. In particular, bile duct injury during LC became the focus of attention<sup>14,16)</sup>. The indications for LC were extended to patients with previous abdominal surgery, coagulopathy, choledocholithiasis and acute cholecystitis following the development of techniques and devices<sup>9)</sup>.

The aim of this study was to assess retrospectively the outcome of the incidence of complications, as well as the outcome in patients with relative contraindications of LC experienced in our hospital. Furthermore, we reviewed previous literature in LC in order to compare our results.

### PATIENTS AND METHODS

The median age of the patients was 49 (range 14-81) years old, and included 74 men and 76 women. One hundred and forty-four patients had cholecystolithiasis in whom combined with 7 choledocholithiasis. Seven patients had adenomyomatosis with stones (4 cases) and without stones (3 cases). Nine patients had benign polyps of the gallbladder with stones (6 cases) and without stones (3 cases). Twelve out of 150 patients had gross and histological findings of marked chronic inflammation, and eight had evidence of acute cholecystitis. Preoperative drip infusion cholangiography (DIC) was performed in the later 76 patients. PTGBA was conducted for patients with acute cholecystitis. The puncture was performed using a 21 gauge percutaneous transhepatic cholangiography (PTC)-needle under US guidance.

The operating technique proceeded in accordance with that reported by Reddick et al<sup>13)</sup> and Olsen<sup>11)</sup>. Under general anesthesia, pneumoperitoneum was obtained using Verress needle for the

first 98 consecutive patients and thereafter by open method, in order to avoid visceral injury. In the open method, double balloon cuff which was equipped with 10 mm trocar was inflated and held the abdominal wall between them. A 10 mm trocar for the videolaparoscope was placed close to the umbilicus. A 11 mm trocar, the operating port, was placed in the midline 3 to 5 cm below the xyphoid process, and two 5 mm trocars were placed along the right anterior axillary line and the mid-clavicular line just below the right costal margin. The fundus of gallbladder was grasped by the forceps and firmly retracted upward toward the diaphragm through the lateral trocar. A second pair of grasping forceps was used for lateral traction of Hartman' pouch, thus allowing optimal exposure of Calot' triangle. The operating port was used for dissection, cauterization, sucking and irrigation. Blunt dissection of the Calot' triangle was started, first dissecting the peritoneum overlying the cystic duct and artery. Both the cystic duct and cystic artery were double clipped and divided. When the cystic duct was too thick to be clipped, the duct was divided after ligation using a 1-0 silk string.

When preoperative endoscopic retrograde cholangiography (ERC) was not available and the anatomy of Calot' triangle was unclear, intraoperative cholangiography through the cystic duct was performed inserting ERC tube equipped with a bronchofiberscope (Olympus, P20, Tokyo Japan). Dissection of the gallbladder from the liver bed was carried out cautery. After coagulating and cutting the surrounding serosa, dissection was carried out using cautery. The gallbladder was put in a rubber container intraperitoneally and the container was brought out through the periumbilical port. After washing, a Penrose drain was placed in the Morrison' fossa.

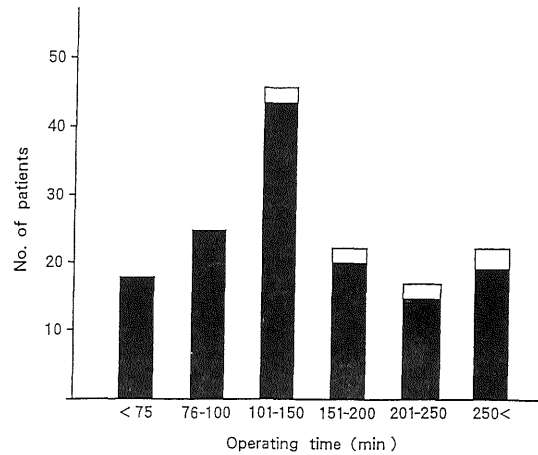
### Statistical analysis

Values are expressed as mean (s.d.). Statistical comparison was made using the Wilcoxon-test, and significance was considered to be  $p < 0.05$ .

## RESULTS

### Operating time of laparoscopic cholecystectomy

Distribution of 150 operations by operating time are shown in Fig. 1. The range of operating time



**Fig. 1.** Overall distribution of operations by operating time.

Most operations took between 101 and 150 min.

■: laparoscopic cholecystectomy

□: conversion to open cholecystectomy

was 50 to 450 min. Most operations lasted 101 to 150 min. Forty-four operations (29 %) took 100 min. or less. Twenty-two cases required more than 250 min. In three cases, LC was converted to open cholecystectomy.

LC was accomplished in 141 patients. The overall operating time (s.d.) for 141 laparoscopic cases was 155 (78) min. Obvious inflammation was present in 15 of 141 cases. The operating time (s.d.) for these patients was 226 (77), and that of the remaining patients was 146 (73); there was a significant difference ( $p < 0.01$ ) between them (Table 1). The operating time gradually decreased throughout the series (Fig. 2).

### Causes of conversion to open cholecystectomy (Table 2)

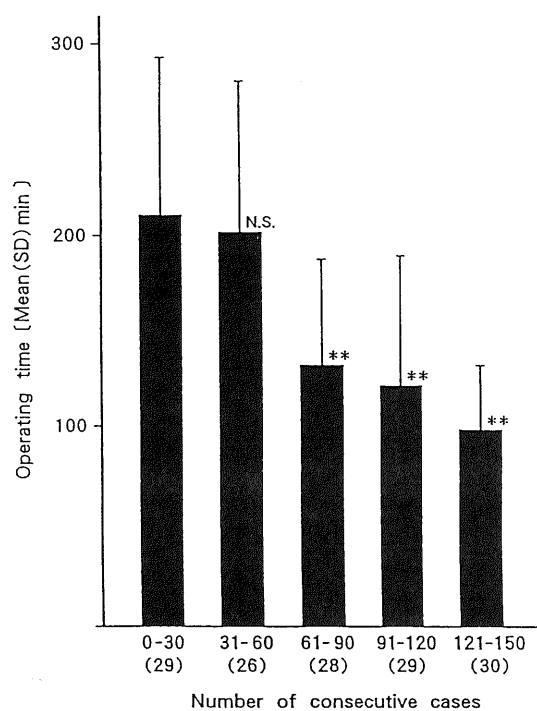
Failure of LC occurred in 9 cases (6%), the causes of which were severe cholecystic inflammation in five cases, bile duct injury in two, impacted stones in the cystic duct in one and severe adhesion in one.

### Complications in laparoscopic cholecystectomy (Table 3)

Intraoperative bleeding was encountered in 20 (14%) cases, but well controlled under lapa-

**Table 1.** Influence of obvious inflammation of the gallbladder on operating time

	No. of patients	Operating time mean (SD) min	p-value
Overall cases in whom LC was performed	141	155 (78)	
With obvious cholecystitis	15	226 (77)	] $p < 0.01$
Without obvious cholecystitis	126	146 (73)	



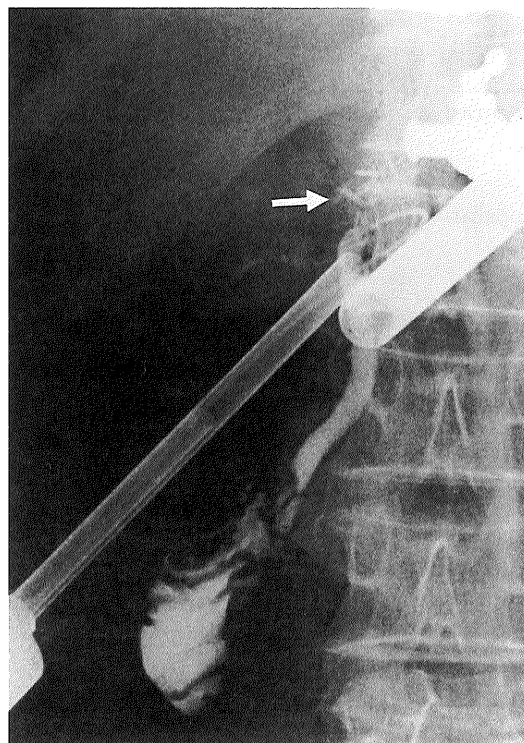
**Fig. 2.** Change of operating time on laparoscopic cholecystectomy. Operating time decreased gradually with the increasing of surgeon' experience. Values in parenthesis express the number of patients on whom laparoscopic cholecystectomy was performed. Significance was compared with the first 30 consecutive cases in which LC was conducted. N.S. not significant \*\* $p < 0.01$

**Table 2.** Causes of conversion to open cholecystectomy

Cause	No. of patient	%
Severe inflammation of gallbladder	5	3.5
Bile duct injury	2	1.4
Stones impacted in the cystic duct	1	0.7
Abdominal wall adhesion	1	0.7

**Table 3.** Complications in laparoscopic cholecystectomy

Complication	No. of patient	%
Bile duct injury	3	2.1
Intraoperative bleeding	20	14.2
Subcutaneous emphysema	9	6.4



**Fig. 3.** Intraoperative cholangiography shows only the lower part of the common bile duct. Arrow shows the clip on the common bile duct.

roscopy. We encountered three cases of common bile or hepatic-duct injuries, which occurred early in this series. One patient was the first case in this series. After dissection of the cystic duct, intraoperative cholangiography was performed. Only the lower part of the common bile duct was revealed by the intraoperative cholangiography (Fig. 3). The second patient was our 6th case. LC was performed uneventfully. However, on the 4th postoperative day (POD) a considerable amount of bile was discharged through the Penrose drain. Laparotomy revealed necrosis of the common hepatic duct due to excessive cauterization. The third patient was our 34th case. After excision of the cystic duct, major leakage of bile was noted. A laparotomy was performed after unsuccessful attempts to stop the leakage. Laparotomy revealed that excision had been performed at the confluence of the cystic and common bile duct.

Although 9 (4%) cases of subcutaneous emphysema were noticed later, all cases healed without particular treatment.

#### Patient recovery after laparoscopic cholecystectomy (Table 4)

No analgesics were necessary in 21 patients, while suppository of ketoprofen was administered to 91 patients. Postoperative oral feeding and ambulation was started in nearly all cases on the 1st or 2nd POD.

**Table 4.** Patient recovery after laparoscopic cholecystectomy

		No of patients	%
Postoperative treatment for pain	none	21	14.9
	Suppository* alone	91	64.5
	Suppository + pentazocine**	29	20.6
Postoperative oral feeding	POD 1	131	92.9
	POD 2	8	5.7
	POD 3	2	1.4
Postoperative ambulation	POD 1	119	84.4
	POD 2	20	14.2
	POD 3	2	1.4

\* Fifty mg ketoprofen suppository  
POD, postoperative day

\*\*Intramuscular injection of 15mg pentazocine

### Laparoscopic cholecystectomy for acute cholecystitis or combined with choledocholithiasis

Seven patients with combined choledocholithiasis were treated successfully by preoperative EST. Four of eight patients with acute cholecystitis were treated preoperatively with PTGBA. The common bile duct was visualized in two cases by percutaneous transhepatic cholecystography, and in the remaining 2 cases ERC was performed.

LC was performed successfully in 6 out of 8 patients (75%). The operating time of these six patients was 204 (63). The postoperative course in these cases was uneventful.

### DISCUSSION

Laparoscopic cholecystectomy offers several advantages to patients: the reduction of postoperative pain, early return to normal activity, early discharge from the hospital and improved cosmetic results. This compares favorably over open cholecystectomy<sup>4,5</sup>). In this series, 14.9% of patients needed no analgesics and 64.5% of patients needed only suppositories. Postoperative oral feeding and ambulation was begun on the first or second POD in almost all patients. In contrast, the patients who had LC converted to open cholecystectomy needed more analgesics and their recovery was delayed as compared with that of LC group.

Recently, with the accumulation of experience, the operating time required for LC without obvious inflammation of gallbladder can be reduced between 50 and 100 min.

Controversies exist regarding the necessity for and the imaging technique employed for evaluating the common bile duct (CBD) stones and the anatomy of biliary tree preoperatively or intraoperatively in patients considered for LC<sup>1,9,10,20</sup>). Wigmore et al<sup>20</sup>) stressed the value of DIC. However, preoperative DIC often failed to demonstrate choledocholithiasis and biliary tree clearly. On the other hand, preoperative endoscopic retrograde cholangiography (ERC) was very useful to determine precisely the anatomy of Calot' triangle

and the presence of choledocholithiasis<sup>10</sup>); ERC itself is not without complications. Therefore, ERC should be selected for the patients with evidence of jaundice, raised alkaline phosphatase level, or sonographic dilated duct. Metzger<sup>9</sup>) suggested the usefulness of intraoperative cholangiography by which bile duct stones or the anatomy of the biliary tree could be demonstrated clearly. We are trying to perform intraoperative cholangiography routinely.

Currently, four procedures are considered in the selection of therapy for the common bile duct stones: 1) endoscopic sphincterotomy (EST) and then LC, 2) LC followed by EST, 3) LC and simultaneous choledocholithotomy, 4) LC simultaneous EST.

In this study, common bile duct stones diagnosed preoperatively were removed by EST prior to LC. All seven cases with common bile duct stones were removed by preoperative EST successfully and safely. Recently, techniques of single stage laparoscopic procedures including cholecystectomy and the clearance of CBD stones tend to be prevailing<sup>15</sup>).

The main causes of conversion to open laparotomy were reported to be the bile duct injury, uncontrollable bleeding and obscure anatomy of Calot' triangle<sup>16</sup>). We experienced three cases of bile duct injury early in this series, and its incidence was 2%; this appears to be high. However, we experienced no bile duct injuries from case 34 through case 150.

The Southern Surgeons Club<sup>19</sup>) reported, on the basis of 1518 cases that the incidence of bile duct injury was 2.2% in the total for each group of the first 13 patients operated on by different surgical teams, and 0.1% thereafter. A decline in the frequency of bile duct injury after an initial rise following the introduction of LC has been attributed to acquisition of surgical experience. The most recent report regarding CBD injuries demonstrated that incidence of CBD injuries was 0.3 %, which is considered to be almost the same as that of open cholecystectomy<sup>3</sup>). Solheim emphasized the following maneuvers to avoid the bile duct injury during

LC; a) the use of oblique viewing telescope which leads to a wider visual field, b) firm cephalic traction on the fundus of the gallbladder, c) lateral traction on the infundibulum of the gallbladder, d) dissection of the cystic duct at the infundibulum of the gallbladder, e) routine intraoperative cholangiography.

The role and timing (early or delayed) of LC in the management of acute cholecystitis remains controversial<sup>2,7,8</sup>. Sonnenberg et al<sup>18</sup> recommended percutaneous transhepatic gallbladder drainage (PTGBD) prior to LC in severe acute cholecystitis. From our experience, a single puncture of the gallbladder seems to be sufficient to reduce pain, fever and leukocytosis. Therefore, it appears to be reasonable to perform LC after PTGBA in acute cholecystitis. On the other hand, Cox et al<sup>2</sup> recommended early LC, because in spite of the fact that early LC is technically demanding and time consuming, the conversion rate is lower than that for delayed LC due to less adhesions. Moreover, total hospital stay was reduced remarkably.

In this study, the conversion rate was 25% (2 of 8 cases). The rate of conversion to open cholecystectomy in acute cholecystitis was reported around 20%<sup>6,7</sup>. The most common reason for conversion was the difficulty in exposing the gallbladder and dissection because of severe adhesions.

In any case, the safety of the laparoscopic approach for acute cholecystitis is a major concern. Lo et al<sup>9</sup> reported that when LC was performed by surgeons experienced in the technique, both early and delayed LC for treatment of acute cholecystitis was safe and effective. Even when performed by experienced surgeons, LC is difficult when an acute attack is superimposed on the chronic inflammation or cholecystitis with empyema or gangrene exist<sup>2</sup>. Conversion to open cholecystectomy should be considered early to reduce the complications. We consider conversion to open cholecystectomy after adequate trial by an experienced laparoscopic surgeon not a complication or operative failure.

Although a previous operation on the lower abdomen rarely interferes with the success of LC, prior upper abdominal operation often does. In our patients, LC might be possible in some cases by choosing suitable trocar sites using ultrasonography and careful dissection in spite of severe upper abdominal adhesions.

In conclusion, LC appears to offer significant advantages to patient recovery, and our data suggest that accurate identification of current limitations, greater understanding of the mechanism of injury, elimination of operating error and the assurance of proper training can reduce the perioperative complications.

## REFERENCES

1. **Baev, St., Pozarliev, T. and Todorov, G.T.** 1995. Laparoscopic cholecystectomy: 700 consecutive cases. *Int. Surg.* **80**: 296–298.
2. **Cox, M.R., Wilson, T.G., Luck, A.J., Jeans, P.L., Padbury, R.T.A. and Toouli, J.** 1993. Laparoscopic cholecystectomy for acute inflammation of the gallbladder. *Ann. Surg.* **218**: 630–634.
3. **Fletcher, D.R., Hobbs, M.S.T., Tan, P., Valinsky, L.J., Hockey, R.L., Knuiman, M.W., Sheiner, H.J. and Edis, A.** 1999. Complications of cholecystectomy: risks of the laparoscopic approach and protective effects of operative cholangiography: a population-based study. *Ann. Surg.* **229**: 449–457.
4. **Gadacz, T.R. and Talamini, M.A.** 1991. Traditional versus laparoscopic cholecystectomy. *Am. J. Surg.* **161**: 336–338.
5. **Hannan, E.L., Imperato, P.J., Nenner, R.P. and Starr, H.** 1999. Laparoscopic and open cholecystectomy in New York State: mortality, complications, and choice of procedure. *Surgery* **125**: 223–231.
6. **Koo, K.P. and Thirlby, R.C.** 1996. Laparoscopic cholecystectomy in acute cholecystitis. What is the optimal timing for operation? *Arch. Surg.* **131**: 540–545.
7. **Lai, P.B.S., Kwong, K.H., Leung, K.L., Kwok, S.P. Y., Chan, A.C.W., Chung, S.C.S. and Lau, W.Y.** 1998. Randomized trial of early versus delayed laparoscopic cholecystectomy for acute cholecystitis. *Br. J. Surg.* **85**: 764–767.
8. **Lo, C.M., Liu, C.L., Lai, E.C.S., Fan, S.T. and Wong, J.** 1996. Early versus delayed laparoscopic cholecystectomy for treatment of acute cholecystitis. *Ann. Surg.* **223**: 37–42.
9. **Metzger, P. and Gamal, E.M.** 1995. Bile duct injuries in the Era of laparoscopic cholecystectomy. *Int. Surg.* **80**: 328–331.
10. **Morris, J.B., Margolis, R. and Rosato, E.F.** 1993. Safe laparoscopic cholecystectomy without intraoperative cholangiography. *Surg. Laparoscopy Endoscopy* **3**: 17–20.
11. **Olsen, D.** 1991. Laparoscopic cholecystectomy. *Am. J. Surg.* **161**: 339–344.
12. **Peters, J.H., Ellison, E.C., Innes, F.T., Liss, J.L., Nichols, K.E., Lomano, J.M., Roby, S.R., Front, M.E. and Carey, L.C.** 1991. Safety and efficacy of laparoscopic cholecystectomy: a prospective analysis of 100 initial patients. *Ann. Surg.* **213**: 3–12.
13. **Reddick, E.J., Olsen, D., Spaw, A., Baird, D., Asbun, H., O'Reilly, M., Fisher, K. and Saye, W.** 1991. Safe performance of difficult laparoscopic cholecystectomies. *Am. J. Surg.* **161**: 377–381.
14. **Richardson, M.C., Bell, G. and Fullarton, G.M.** 1996. Incidence and nature of bile duct injuries following laparoscopic cholecystectomy: an audit of 5913 cases. *Br. J. Surg.* **83**: 1356–1360.
15. **Santambrogio, R., Montorsi, M., Bianchi, P., Opocher, E., Verga, M., Panzera, M. and Cosentino, F.** 1997. Common bile duct exploration and laparoscopic cholecystectomy: role of intra-operative ultrasonography. *J. Am. Coll. Surg.* **185**: 40–48.
16. **Shea, J.A., Healey, M.J., Berlin, Sc. D., Clarke, J.R., Malet, P.F., Staroscik, R.N., Schwartz, J.S. and Williams, S.V.** 1996. Mortality and com-

- plications associated with laparoscopic cholecystectomy. *Ann. Surg.* **224**: 609–620.
17. **Solheim, K. and Buanes, T.** 1995. Bile duct injury in laparoscopic cholecystectomy. *Int. Surg.* **80**: 361–364.
  18. **Sonnenberg, E., D'Agostino, H.B., Goodacre, B.W., Sanchez, R.B. and Casola, G.** 1992. Percutaneous gallbladder puncture and cholecystostomy: Results, complications, and caveats for safety. *Radiology* **183**: 167–170.
  19. **The Southern Surgeons Club.** 1991. A prospective analysis of 1518 laparoscopic cholecystectomies. *N. Engl. J. Med.* **324**: 1073–1078.
  20. **Wigmore, S.T., Petro, A.B., Meena, A.L., Haick, A.J. and Koury, A.M.** 1991. A practical approach to laparoscopic cholecystectomy. *Am. J. Surg.* **161**: 365–370.