

Norovirus Gastroenteritis Accompanied by Ischemic Colitis: A Case Report

Takahiro ZENDA^{1,*}, Shuichi KANEKO²⁾ and Sakon NORIKI³⁾

1) Department of Internal Medicine, Tsurugi Municipal Hospital, Hakusan 920-2134, Japan

2) Department of Gastroenterology, Graduate School of Medical Science, Kanazawa University, Kanazawa 920-8641, Japan

3) Division of Tumor Pathology, Department of Pathological Science, Faculty of Medical Science, University of Fukui, Eiheiji, Fukui 910-1193, Japan

ABSTRACT

A 57-year-old woman was admitted to our hospital because of frequent bloody diarrhea, vomiting, and abdominal cramps. While the patient was diagnosed with norovirus gastroenteritis based on the presence by chance of positive norovirus antigen in the stool samples, endoscopic as well as pathological examinations demonstrated left-sided ischemic colitis. The patient soon recovered solely by supportive treatment. Although it is believed that patients with viral gastroenteritis do not develop bloody diarrhea, the present case suggested that conditions of viral gastroenteritis, such as intensified peristalsis, elevation of the intraluminal gut pressure, hypovolemia, and hemoconcentration might trigger ischemic colitis resulting in bloody diarrhea. Physicians should not exclude the diagnosis of viral gastroenteritis simply by depending on the presence of bloody diarrhea. Further studies to clarify the incidence of ischemic colitis in patients with viral gastroenteritis are indispensable.

Key words: *Viral gastroenteritis, Bloody diarrhea, Ischemic colitis, Mesenteric circulation*

It has been believed that bloody diarrhea is not observed in patients with viral gastroenteritis^{1,2,6)}. This observation is described as one of the characteristic features that distinguish viral gastroenteritis from bacterial gastroenteritis in the text book⁶⁾. Here, we describe a case of norovirus gastroenteritis with an initial manifestation of bloody diarrhea. We also conduct a literature review and discuss the possible mechanism underlying the development of and the incidence of bloody diarrhea associated with viral gastroenteritis.

CASE REPORT

A 57-year-old previously healthy woman was admitted to our hospital because of the acute onset of abdominal cramps, frequent vomiting, and diarrhea, which had become bloody approximately 4 hr after the onset. Physical examination conducted on admission revealed mild tenderness in the epigastrium and left lower abdomen. The bowel sound was enhanced. Laboratory tests revealed leukocytosis (while cell count, 12600/ μ l, with 82.7% neutrophils), but no other abnormal findings, including anemia and increase of

C-reactive protein, were found. Because it was an epidemic season of norovirus gastroenteritis and because we aimed to prevent nosocomial infection, we examined the patient's stool samples for antigens of norovirus, rotavirus, and adenovirus by using commercial kits with immunochromatographic assay (QUICKNAVITM-NORO, Otsuka Pharmaceutical CO., Ltd., Tokyo, Japan for norovirus, and RapidTesta[®] ROTA-ADENO, Sekisui Medical CO., Ltd., Tokyo, Japan for rotavirus and adenovirus). The stool samples tested exclusively and repeatedly positive for the norovirus antigen. Computed tomography demonstrated a wall thickening extending from the descending to the sigmoid colon, thereby suggesting some kind of colitis. Colonoscopy revealed an edematous swollen, reddish, friable mucosa from the sigmoid colon to the splenic flexure: this finding was suggestive of ischemic colitis (Figs. 1, 2). Pathological examination of the colonic lesion demonstrated a decrease in the number of mucosal glands and glandular goblet cells, which was prominent at the superficial region of the mucosa: these findings were also consistent with those of ischemic colitis (Fig. 3). On the basis of the existence of

*Correspondence: Takahiro Zenda, M.D.

Department of Internal Medicine, Tsurugi Municipal Hospital, Tsurugi-mito-machi NO-1, Hakusan 920-2134, Japan
Phone: +81-76-272-1250 Fax: +81-76-272-3144 e-mail: t-zenda@tsurugihp.jp

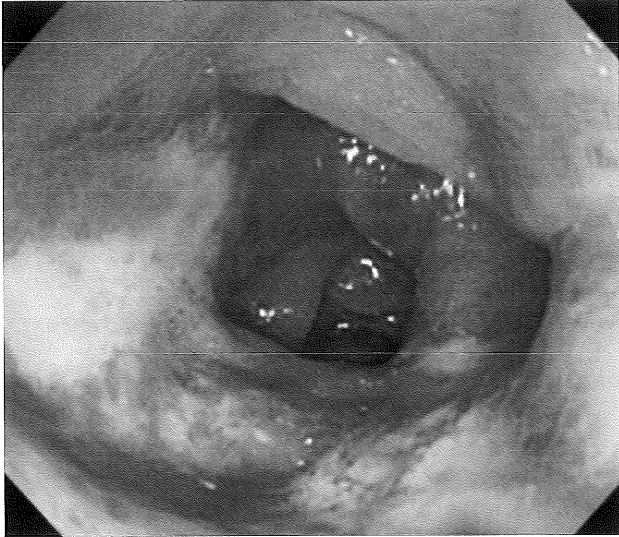


Fig. 1. Endoscopy revealed edematous, swollen, friable, reddish colonic mucosa extending from the splenic flexure to the oral side of the sigmoid colon, with an appearance identical to ischemic colitis.

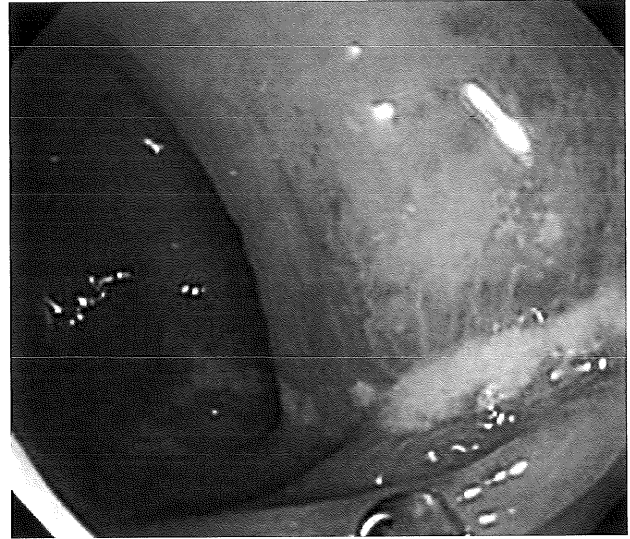


Fig. 2. Longitudinal ulcers were found in the descending colon.

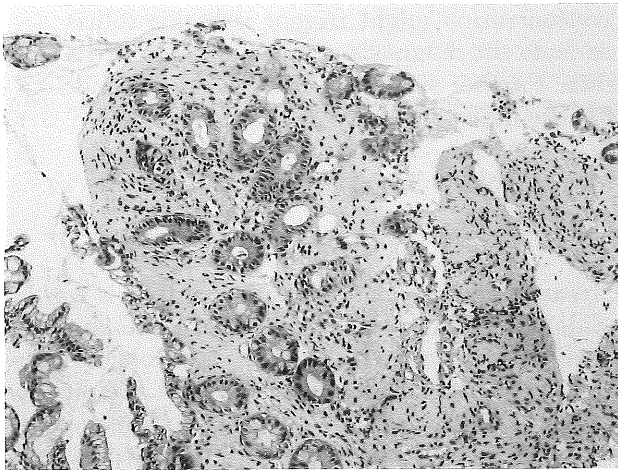


Fig. 3. The pathological findings of the colonic biopsy specimens were also consistent with those of ischemic colitis, i.e., a decrease in the number of mucosal glands and glandular goblet cells, which was prominent at the superficial region of the mucosa. (H-E stain $\times 100$)

norovirus antigen in the stool and the pathological and endoscopic findings, the patient was diagnosed with norovirus gastroenteritis accompanied by left-sided ischemic colitis. The patient soon recovered after conservative treatment, including bowel resting and intravenous rehydration, and was discharged on the 7th hospital day.

DISCUSSION

Norovirus is thought to infect the villous enterocytes of the duodenum and oral side of the jejunum^{1,6,7} via the carbohydrate ligands expressed on the surface of the intestinal epithelium, which also play a role as histo-blood group antigens^{1,6}.

Because of the replication of noroviruses in the enterocytes, a large number of infected enterocytes die and fall into the enteric lumen, thereby resulting in malabsorption and diarrhea^{1,6,7}. As for the pathogenesis of the colonic lesion in the present case, direct injury of the colonic mucosa by norovirus seems unlikely considering the cell affinity of norovirus and a report showing that no significant pathological alterations were found in the stomach and colon in patients with viral gastroenteritis³. Further, the endoscopic and pathological findings of the colonic lesion were exactly compatible with those of ischemic colitis.

According to the well-known classification of ischemic colitis proposed by Marston et al⁴, the present colonic lesion corresponded to the "transient type." In this type of colitis, ischemia is limited to the mucosal layer, and enteric but not vascular factors, such as elevation of intraluminal gut pressure and intensified peristalsis, principally contribute to the mucosal ischemia⁴. Therefore, it is more probable that enhanced intestinal peristalsis, increased intramural pressure due to excessive watery stool and gas output, and hypovolemia or hemoconcentration after diarrhea and vomiting impaired microcirculation in the colonic mucosa, thereby resulting in ischemic colitis.

Although we used PubMed to search for reports documenting the relationship between viral gastroenteritis and bloody diarrhea using the key words: *norovirus*, *Norwalk virus*, *viral enteritis*, *bloody stool*, *bloody diarrhea*, *melena*, *hematochezia*, *bleeding*, *hemorrhage*, *ischemic colitis*, *complication*, *sequel* and their combinations, we could find only few documents. However, Nishizawa et al⁵ recently reported an astonishingly high incidence rate of bloody diarrhea in Japanese adult patients with viral gastroenteritis (29 of 84 cases, 34.5%).

In addition, endoscopic examination revealed ischemic colitis-like lesions as the cause of bloody diarrhea in 81.5% of patients (22 of 27 cases), and all 8 patients who underwent pathological examination were diagnosed with ischemic colitis⁵. The findings in the present case were compatible with those in Nishizawa's report, which regrettably was written only in Japanese. These findings raise a critical issue that there may be patients who are treated solely for ischemic colitis without any recognition of viral gastroenteritis. If further studies demonstrate that the coexistence of viral gastroenteritis and ischemic colitis is not a rare condition, the current diagnostic criteria of ischemic colitis will have to be revised, because the exclusion of infectious enteritis is essential to diagnose ischemic colitis at present⁴. Nishizawa et al also reported significantly different incidence rates of bloody diarrhea depending on enteric viruses, i.e., 17.6% in norovirus infection, 58.6% in rotavirus infection, 62.5% in astrovirus infection, and 33.3% in adenovirus infection⁵. As rotavirus gastroenteritis, of which clinical symptoms are comparatively intense among the enteric viruses^{6,8}, presents bloody diarrhea with high incidence⁵, the incidence of bloody diarrhea may be influenced by the severity of viral gastroenteritis.

In order to prove that bloody diarrhea is not a coincidental or rare manifestation related to viral gastroenteritis, further studies to clarify the incidence rate of ischemic colitis in a large number of patients with viral gastroenteritis are indispensable. However, this present case clearly showed that not only bacterial but also viral gastroenteritis presents bloody diarrhea by complicating ischemic colitis. In addition, on the basis of a recent literature review, complication of ischemic colitis in patients with viral gastroenteritis may be higher than we have expected⁷. Clinicians should thus not exclude the diagnosis of viral gastroenteritis simply because of the presence of bloody diarrhea.

(Received October 26, 2010)

(Accepted November 29, 2010)

REFERENCES

1. **Glass, R.I., Parashar, U.D. and Estes, M.K.** 2009. Norovirus gastroenteritis. *N.Engl. J. Med.* **361**:1776-1785.
2. **Khan, R.R., Lawson, A.D., Minnich, L.L., Martin, K., Nasir, A., Emmett, M.K., Welch, C.A. and Udall, Jr., J.N.** 2009. Gastrointestinal norovirus infection associated with exacerbation of inflammatory bowel disease. *J. Pediatr. Gastroenterol. Nutr.* **48**:328-333.
3. **Levy, A.G., Widerlite, L., Schwartz, C.J., Dolin, R., Blacklow, N.R., Gardner, J.D., Kimberg, D.V. and Trier, J.S.** 1976. Jejunal adenylate cyclase activity in human subjects during viral gastroenteritis. *Gastroenterology* **70**:321-325.
4. **Marston, A., Pheils, M.T., Thomas, M.L. and Morson, B.C.** 1966. Ischaemic colitis. *Gut.* **7**:1-15.
5. **Nishizawa, A., Fujiwara, T., Egawa, N., Okamoto, T., Kubota, N., Sanaka, M., Nakajima, H., Urita, Y., Sugimoto, M., Nakagomi, T. and Nakagomi, O.** 2008. The significance of viral infections in infectious enterocolitis. *Shokakika (Gastroenterology)* **47**:233-238. (In Japanese)
6. **Parashar, U.D. and Glass, R.I.** 2005. Viral gastroenteritis, p.1140-1143. *In* D.L. Kasper, E. Braunwald, A.S. Fauci et al (eds.), *Harrison's principles of Internal Medicine*, 16th ed. McGraw-Hill, New York.
7. **Salim, A.F., Phillips, A.D. and Farthing, M.J.** 1990. Pathogenesis of gut virus infection. *Baillieres Clin. Gastroenterol.* **4**:593-607.
8. **Wu, T.C., Liu, H.H., Chen, Y.J., Tang, R.B., Hwang, B.T. and Yuan, H.C.** 2008. Comparison of clinical features of childhood norovirus and rotavirus gastroenteritis in Taiwan. *J. Chin. Med. Assoc.* **71**:566-570.