

Ruptured Vertebral Artery Dissecting Aneurysms Treated with Endovascular Treatment

Masaaki SHIBUKAWA, Shigeyuki SAKAMOTO, Yoshihiro KIURA,
Toshinori MATSUSHIGE and Kaoru KURISU*

Department of Neurosurgery, Graduate School of Biomedical Sciences, Hiroshima University, 1-2-3 Kasumi, Minami-ku, Hiroshima 734-8551, Japan

ABSTRACT

Intracranial vertebral artery (VA) dissecting aneurysms often present with severe subarachnoid hemorrhage (SAH) and a subsequent high rate of mortality. We retrospectively studied the treatment efficacy and outcomes of 26 patients with ruptured VA dissecting aneurysms treated with endovascular surgery. Twenty-six patients with ruptured VA dissecting aneurysms were enrolled. Fifteen patients presented with poor-grade SAH and eleven with good-grade SAH. All patients were treated with endovascular treatment. We reviewed modes of therapy, complications and clinical outcomes. Coil occlusion of the artery at the dissecting aneurysm was performed in 24 patients. Proximal parent artery occlusion was performed in 2 patients. Obliteration of the dissecting aneurysm on postoperative angiogram was found in all patients. No patient sustained permanent complications associated with endovascular treatment. Regarding clinical outcome, although five patients died due to severe SAH, 19 patients had a good recovery or moderate disability. Ruptured VA dissecting aneurysms can be managed safely with coil occlusion of the lesion and/or parent artery.

Key words: *Dissecting aneurysm, Endovascular treatment, Subarachnoid hemorrhage, Vertebral artery*

Intracranial artery dissections occur frequently in the vertebral artery (VA), and are likely to present with subarachnoid hemorrhage (SAH)¹⁸. Furthermore, the rebleeding rate from untreated VA dissecting aneurysms is extremely high⁹. The recurrent bleeding tends to occur within 7 days from the initial bleeding⁹. The mortality rate is significantly higher in patients with rebleeding than in those without. Therefore, patients with ruptured VA dissecting aneurysms have been treated by surgical or endovascular surgery to prevent a repeated rupture at the acute stage⁹. The aim of this study is to evaluate the treatment efficacy and outcome of ruptured VA dissecting aneurysms treated with endovascular coil embolization at Hiroshima University Hospital.

MATERIALS AND METHODS

Between November 1998 and December 2008, 27 patients presented with SAH for ruptured VA dissecting aneurysms. SAH was confirmed by CT

scanning of the head. Twenty-six of 27 patients with ruptured VA dissecting aneurysms were treated surgically. One of the 27 patients was managed conservatively because the Glasgow Coma Scale score was 3, the patient's eyes showed bilateral pupillary mydriasis after hemorrhage, and the autopsy clarified ruptured VA dissecting aneurysms. Twenty-six consecutive patients with ruptured VA dissecting aneurysms treated surgically were enrolled in this study. This study was approved by our institutional review board. The clinical characteristics of the patients are summarized in Table 1. The patients included 10 females and 16 males ranging in age from 36 to 74 years (mean age, 52.3 years). SAH was classified using the Hunt and Hess grading system. Five patients (19%) had Grade 2 by the Hunt and Hess grading system, 6 (23%) Grade 3, 5 (19%) Grade 4, and 10 (38%) Grade 5, respectively.

The VA dissecting aneurysms were classified into four types, as proposed in a previous study⁹: type 1, lesions distal to the origin of the posterior

*Correspondence: Kaoru Kurisu, MD

Department of Neurosurgery, Graduate School of Biomedical Sciences, Hiroshima University, 1-2-3 Kasumi, Minami-ku, Hiroshima 734-8551, Japan

Tel: +81-82-257-5227, Fax: +81-82-257-5229 E-mail: kuka422@hiroshima-u.ac.jp

inferior cerebellar artery (PICA) (Fig. 1a and 2a); type 2, lesions of the VA involving the origin of the PICA (Fig. 1b and 3a); type 3, lesions proximal to the origin of the PICA (Fig. 1c and 4a); and type 4, lesions involving the VA without the appearance of the PICA (Fig. 1d and 5a), respectively. Sixteen lesions were of type 1, two lesions were of type 2, four lesions were of type 3, and four lesions were of type 4, respectively. Dominant VA was affected in 14 patients, and nondominant VA in 12 patients. In 14 patients with dominant VA involvement, test occlusion preceded coil embolization.

All patients were treated with endovascular surgery, and direct surgery was not performed. Endovascular surgery was performed under local anesthesia and systemic anticoagulation with continuous heparin or argatroban. A guiding catheter was placed in the V2 portion of the involved VA via a femoral artery. Coil occlusion was performed according to the type of VA dissecting aneurysm. Twenty-three patients (88%) were treated within 7 days from the onset of the aneurysm rupture and 3 (12%) were treated after 14 days. Clinical outcome was evaluated according to the Glasgow Outcome Scale (GOS) at the time of discharge.

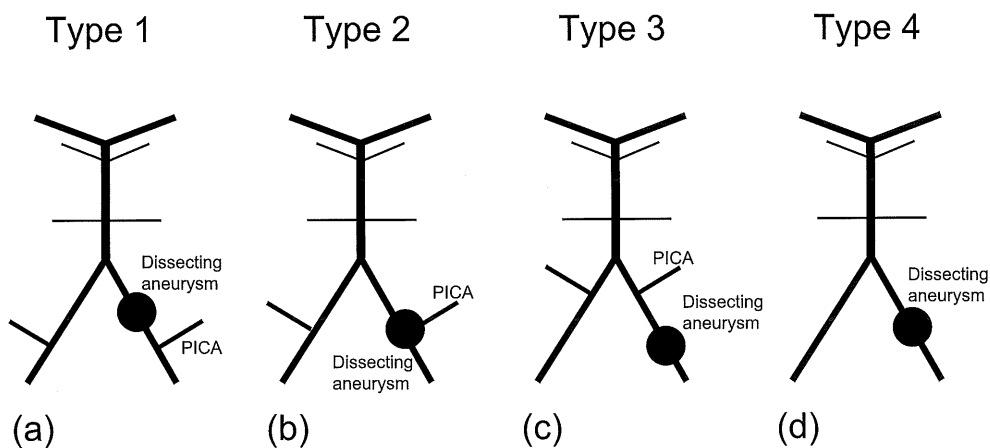


Fig. 1. Schematic diagram of different types of vertebral artery dissecting aneurysms classified according to the position of posterior inferior cerebellar artery (PICA).

- Type 1, dissecting aneurysm distal to the origin of the PICA
- Type 2, dissecting aneurysm of the vertebral artery involving the origin of the PICA
- Type 3, dissecting aneurysm proximal to the origin of the PICA
- Type 4, dissecting aneurysm involving the VA without the appearance of the PICA

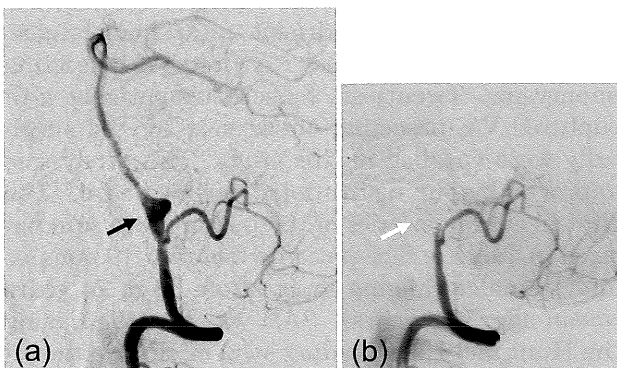


Fig. 2. Case No. 22: A patient with a ruptured dissecting aneurysm on the right side.

- The dissecting aneurysm was classified as type 1 because right vertebral angiogram, lateral view, revealed a dissecting aneurysm (arrow) distal to the origin of the posterior inferior cerebellar artery.
- Vertebral angiogram after endovascular occlusion of the vertebral artery at the dissection site (white arrow) showed complete obliteration of the dissecting aneurysm.

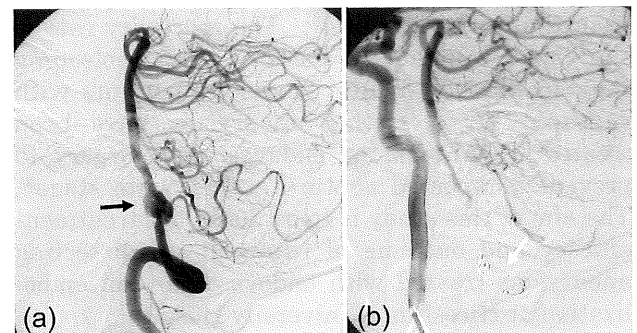


Fig. 3. Case No. 9: A patient with a ruptured dissecting aneurysm on the right side.

- The dissecting aneurysm was classified as type 2 because right vertebral angiogram, lateral view, revealed a dissecting aneurysm (arrow) of the vertebral artery involving the origin of the posterior inferior cerebellar artery.
- Internal carotid angiogram after endovascular occlusion of the proximal part of the dissecting aneurysm (white arrow) revealed disappearance of the dissecting aneurysm through retrograde flow.

RESULTS

The clinical characteristics of the patients are summarized in Table 1. Coil occlusion of the artery at the dissection site was performed in 24 patients. Proximal parent artery occlusion was performed in 2 patients. In types 1, 3 and 4, a microcatheter was advanced to the most distal part of the dissecting aneurysm through the guiding catheter, taking care not to enter the pseudolumen of the dissection, and the VA at the dissecting aneurysm was occluded using several detachable coils (internal trapping) (Fig. 2b, 4b and 5b). In type 2, a microcatheter was advanced to the proximal part of the dissecting aneurysm through the guiding catheter, and the proximal VA occlusion was performed using several detachable coils (proximal occlusion) (Fig. 3b). No dissecting aneurysm on postoperative angiogram was visible in any patient. No patient sustained permanent complications associated with endovascular treatment. Regarding clinical outcome, although five patients died of severe SAH, 19 patients, including 9 of the 15 presenting with poor-grade SAH, had a good recovery or moderate disability. No patients had rebleeding after endovascular treatment.

DISCUSSION

Intracranial artery dissections are caused by disruption of the internal elastic lamina (IEL)¹⁰. Intracranial artery dissection might be caused by penetration by circulating blood into the vascular wall with subsequent extensions of effused blood

for varying distances between vessel layers producing a dissociated alveus through disruption of the IEL¹⁰. The mechanism of clinical onset may involve subintimal dissection resulting in ischemia through stenosis or occlusion of the parent artery by hemodynamic mechanism, subadventitial dissection resulting in SAH¹⁹. Although intracranial artery dissection tends to occur more commonly in the vertebrobasilar system, it has been found that intracranial VA dissection itself is a rare cause of SAH, accounting for less than 10% of cases¹⁸.

The clinical characteristics of vertebrobasilar dissecting aneurysms occurring with SAH have been reviewed by Mizutani et al⁹. According to them, re-rupture occurred in 71% of cases. Furthermore, mortality of patients with re-rupture (46.7%) was significantly higher than that without re-rupture (8.3%), and 80% of re-ruptures occurred within the first week. On the other hand, the risk of rebleeding in cases of ruptured vertebrobasilar aneurysms decreases markedly when the acute stage has passed³. Therefore, conservatively treated ruptured vertebrobasilar aneurysms have been shown to follow a benign clinical course³. Hashimoto et al described seven patients with conservatively treated ruptured vertebrobasilar dissecting aneurysms³. They concluded that conservative treatment with fentanyl administration might be a good option for management of ruptured vertebrobasilar dissecting aneurysms during the acute stage³. However, patients with hemorrhage are at high risk of early rebleeding. Therefore, we suggest that early surgical treatment should be considered as soon as

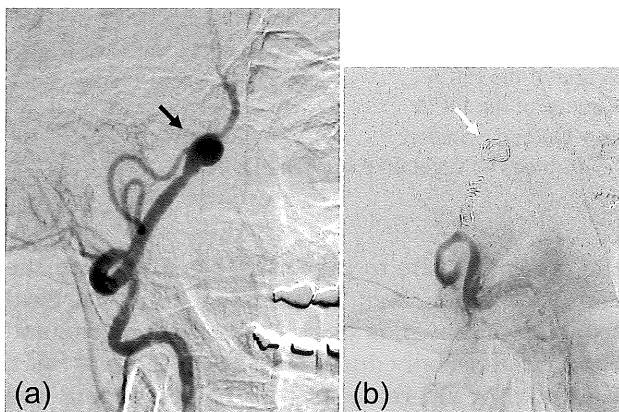


Fig. 4. Case No. 10: A patient with a ruptured dissecting aneurysm on the right side.

- The dissecting aneurysm was classified as type 3 because right vertebral angiogram, anterior view, revealed a dissecting aneurysm (arrow) proximal to the origin of the posterior inferior cerebellar artery.
- Right vertebral angiogram after endovascular occlusion of the vertebral artery at the dissection site (white arrow) showed complete obliteration of the dissecting aneurysm.

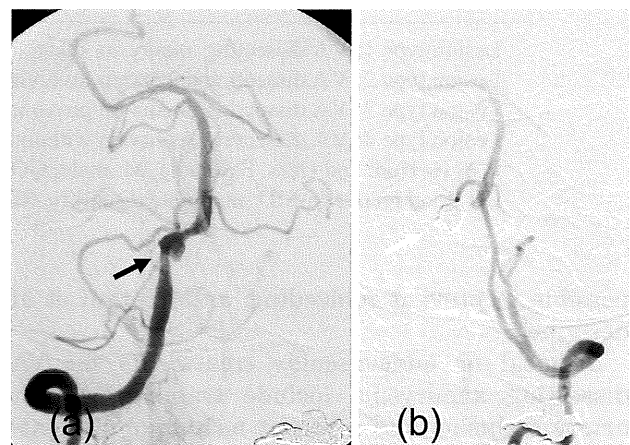


Fig. 5. Case No. 13: A patient with a ruptured dissecting aneurysm on the right side.

- The dissecting aneurysm was classified as type 4 because right vertebral angiogram, anterior view, revealed a dissecting aneurysm (arrow) without the appearance of the posterior inferior cerebellar artery.
- Left vertebral angiogram after endovascular occlusion of the vertebral artery at the dissection site (white arrow) showed complete obliteration of the dissecting aneurysm.

Table 1. Summary of 26 patients with ruptured vertebral artery dissecting aneurysms treated with endovascular surgery

Case No.	Age / sex	H & H Grade	Lesion Type	Endovascular Procedure	Time to Treatment (days)	GOS at the time of discharge
1	48 / M	4	1	internal trapping	7	GR
2	65 / F	5	1	internal trapping	5	MD
3	59 / M	5	1	internal trapping	2	MD
4	49 / F	2	1	internal trapping	15	GR
5	37 / M	3	3	internal trapping	1	MD
6	56 / F	2	1	internal trapping	4	GR
7	62 / F	2	1	internal trapping	23	GR
8	39 / M	5	1	internal trapping	1	D
9	47 / M	5	2	proximal occlusion	18	MD
10	66 / F	4	3	internal trapping	0	D
11	59 / M	4	1	internal trapping	1	MD
12	36 / F	2	4	internal trapping	3	GR
13	45 / M	5	4	internal trapping	4	MD
14	65 / M	2	1	internal trapping	1	MD
15	62 / M	3	1	internal trapping	1	GR
16	45 / F	3	1	internal trapping	0	D
17	50 / M	4	4	internal trapping	1	D
18	60 / M	5	1	internal trapping	0	GR
19	39 / M	3	3	internal trapping	1	GR
20	47 / F	3	3	internal trapping	6	GR
21	61 / F	3	4	internal trapping	1	GR
22	38 / M	5	1	internal trapping	0	GR
23	44 / M	5	1	internal trapping	1	GR
24	74 / F	4	2	proximal occlusion	0	D
25	47 / M	5	1	internal trapping	0	SD
26	62 / M	5	1	internal trapping	0	V

Lesion type 1: VA dissecting aneurysm distal to the origin of the PICA

Lesion type 2: VA dissecting aneurysm involving the origin of the PICA

Lesion type 3: VA dissecting aneurysm proximal to the origin of the PICA

Lesion type 4: VA dissecting aneurysm without the appearance of the PICA

H & H: Hunt and Hess, F: female, M: male, GOS: Glasgow Outcome Scale,

GR: good recovery, MD: moderate disability, SD: severely disabled, V: vegetative survival, D: dead

possible to prevent rebleeding, as Mizutani et al describe⁹).

Surgical or endovascular treatments for VA dissecting aneurysms include trapping, parent artery occlusion and a recent technique of stent-assisted coiling^{12,13,15}). Proximal VA ligation used to be performed as a treatment for VA dissecting aneurysms^{1,2,5}). Thus, alteration of the flow dynamics produced thrombosis of the aneurysm. Nevertheless, rebleeding after proximal VA occlusion by ligation or clipping was reported, though it was rare^{6,9}). The most complete appropriate treatment of VA dissecting aneurysms would be to exclude the affected segment of VA from normal blood circulation. Therefore, surgical trapping of

the dissection site to prevent rebleeding from the ruptured lesion was recommended¹²). Surgical trapping, however, is more difficult than proximal clipping, especially during the acute stage of SAH. Kitanaka et al⁶) reported that both trapping and clipping prevented further rebleeding, but surgical trapping was associated with a higher rate of lower cranial nerve palsy after direct surgery. The complexity of these approaches and their higher morbidity and mortality rates hastened the advent of endovascular treatment¹).

Endovascular treatment for VA dissecting aneurysms was initially performed to occlude VA proximal to the affected segment using detachable balloon or coils. This procedure was again limit-

ed by cases of aneurysm recurrence and repeated hemorrhage^{3,8,17}. Then, the policy of endovascular treatment changed from proximal occlusion to trapping⁴, in which the dissected site was completely occluded with detachable coils. This procedure was based on the same concept as surgical trapping¹⁶. The efficacy of endovascular treatment for ruptured VA dissecting aneurysms has been confirmed in a number of reports^{1,4,7,12,14,16}. Endovascular treatment seems the best for treating ruptured VA dissecting aneurysms during the acute stage of SAH. Furthermore, endovascular trapping was the best procedure for the prevention of re-rupture when the aneurysm location was far from the origin of the PICA and the spinal artery. On the other hand, endovascular trapping of the dissecting aneurysm involving the origin of the PICA and the spinal artery was difficult because occlusion of PICA and the spinal artery might cause cerebellar and spinal infarction. Stent? supported coil embolization has recently been performed for dissecting aneurysms involving the PICA or spinal artery^{11,16}. However, the procedure has been associated with a higher rate of thromboembolic complications¹.

There were some limitations in this study. This was a limited study comprising 26 patients with ruptured VA dissecting aneurysms treated with only endovascular surgery. Moreover, no patients were treated with direct surgical trapping of the dissecting aneurysm with an occipital artery-PICA bypass, especially VA dissecting aneurysms involving the origin of the PICA. Therefore, the treatment efficacy of endovascular and direct surgical treatment might have to be compared for our study.

In our study, endovascular treatment for ruptured VA dissecting aneurysms could be performed safely without complications and was effective without re-rupture postoperatively. Regarding clinical outcome, 19 patients, including 9 of the 15 presenting with poor-grade SAH, had a good recovery or moderate disability. Ruptured VA dissection can be managed safely with coil occlusion of the lesion and/or parent artery through endovascular treatment. From the results of our study, endovascular trapping was the best treatment for ruptured VA dissecting aneurysms. However, endovascular proximal occlusion was used as an alternative treatment for ruptured VA dissecting aneurysms when endovascular trapping could not be performed. Therefore, we concluded that endovascular treatment for ruptured VA dissecting aneurysms was effective.

(Received March 24, 2009)

(Accepted June 18, 2009)

REFERENCES

1. **Albuquerque, F.C., Fiorella, D.J., Han, P.P., Deshmukh, V.R., Kim, L.J. and McDougall, C.G.** 2005. Endovascular management of intracranial vertebral artery dissecting aneurysms. *Neurosurg. Focus* **18**: E3.
2. **Friedman, A.H. and Drake, C.G.** 1984. Subarachnoid hemorrhage from intracranial dissecting aneurysm. *J. Neurosurg.* **60**: 325-334.
3. **Hashimoto, M., Johkura, K., Ichikawa, T., Kojima, A., Nishimura, S. and Shinonaga, M.** 2008. Conservative treatment of ruptured vertebrobasilar dissecting aneurysm. *Neurol. Sci.* **29**: 241-244.
4. **Iihara, K., Sakai, N., Murao, K., Sakai, H., Higashi, T., Kogure, S., Takahashi, J.C. and Nagata, I.** 2002. Dissecting aneurysms of the vertebral artery: a management strategy. *J. Neurosurg.* **97**: 259-267.
5. **Kitanaka, C., Morimoto, T., Sasaki, T. and Takakura, K.** 1992. Rebleeding from vertebral artery dissection after proximal clipping. Case report. *J. Neurosurg.* **77**: 466-468.
6. **Kitanaka, C., Sasaki, T., Eguchi, T., Teraoka, A., Nakane, M. and Hoya, K.** 1994. Intracranial vertebral artery dissections: clinical, radiological features, and surgical considerations. *Neurosurgery* **34**: 620-627.
7. **Kurata, A., Ohmomo, T., Miyasaka, Y., Fujii, K., Kan, S. and Kitahara, T.** 2001. Coil embolization for the treatment of ruptured dissecting vertebral aneurysms. *A.J.N.R. Am. J. Neuroradiol.* **22**: 11-18.
8. **MacKay, C.I., Han, P.P., Albuquerque, F.C. and McDougall, C.G.** 2003. Recurrence of a vertebral artery dissecting pseudoaneurysm after successful stent-supported coil embolization: case report. *Neurosurgery* **53**: 754-761.
9. **Mizutani, T., Aruga, T., Kirino, T., Miki, Y., Saito, I. and Tsuchida, T.** 1995. Recurrent subarachnoid hemorrhage from untreated ruptured vertebrobasilar dissecting aneurysms. *Neurosurgery* **36**: 905-913.
10. **Mizutani, T., Miki, Y., Kojima, H. and Suzuki, H.** 1999. Proposed classification of nonatherosclerotic cerebral fusiform and dissecting aneurysm. *Neurosurgery* **45**: 253-260.
11. **Phatouros, C.C., Sasaki, T.Y., Higashida, R.T., Malek, A.M., Meyers, P.M., Dowd, C.F. and Halbach, V.V.** 2000. Stent-supported coil embolization: the treatment of fusiform and wide-neck aneurysms and pseudoaneurysms. *Neurosurgery* **47**: 107-115.
12. **Rabinov, J.D., Hellinger, F.R., Morris, P.P., Ogilvy, C.S. and Putman, C.M.** 2003. Endovascular management of vertebrobasilar dissecting aneurysms. *A.J.N.R. Am. J. Neuroradiol.* **24**: 1421-1428.
13. **Sakamoto, S., Ohba, S., Shibukawa, M., Kiura, Y., Okazaki, T., Arita, K. and Kurisu, K.** 2005. Staged bilateral vertebral artery occlusion for ruptured dissecting aneurysms of the basilar artery: a report of 2 cases. *Surg. Neurol.* **64**: 456-461.
14. **Sakamoto, S., Ohba, S., Eguchi, K., Shibukawa, M., Kiura, Y., Okazaki, T., Kajihara, Y., Arita, K. and Kurisu, K.** 2005. Churg-Strauss syndrome presenting with subarachnoid hemorrhage from

- ruptured dissecting aneurysm of the intracranial vertebral artery. *Clin. Neurol. Neurosurg.* **107**: 428-431.
15. **Sakamoto, S., Ohba, S., Shibukawa, M., Kiura, Y., Okazaki, T., Kurisu, K., Kajihara, Y. and Mukada, K.** 2008. Transient headache related to enlargement of the contralateral vertebral artery after vertebral artery occlusion. *Surg. Neurol.* **70**: 463-465.
 16. **Sugiu, K., Tokunaga, K., Watanabe, K., Sasahara, W., Ono, S., Tamiya, T. and Date, I.** 2005. Emergent endovascular treatment of ruptured vertebral artery dissecting aneurysms. *Neuroradiology* **47**:158-164.
 17. **Tsukahara, T., Wada, H., Satake, K., Yaoita, H. and Takahashi, A.** 1995. Proximal balloon occlusion for dissecting vertebral aneurysms accompanied by subarachnoid hemorrhage. *Neurosurgery* **36**: 914-920.
 18. **Yamaura, A.** 1988. Diagnosis and treatment of vertebral aneurysms. *J. Neurosurg.* **69**: 345-349.
 19. **Yonas, H., Agamanolis, D., Takaoka, Y. and White, R.J.** 1977. Dissecting intracranial aneurysms. *Surg. Neurol.* **8**: 407-415.