

The induction of insulinomas by X-irradiation to the gastric region in Otsuka Long-Evans Tokushima Fatty rats

HIROMITSU WATANABE and KENJI KAMIYA

Department of Experimental Oncology, Research Institute for Radiation Biology and Medicine, Hiroshima University, 1-2-3 Kasumi, Minami-ku, Hiroshima 734-8553, Japan

Received September 10, 2007; Accepted December 13, 2007

Abstract. The X-ray induction of tumors was examined in five-week-old male Otsuka Long-Evans Tokushima Fatty (OLETF) rats, treated with two 10 Gy doses to the gastric region with a 3-day interval (total 20 Gy). After irradiation, the rats received the commercial diet MF and tap water and were maintained for up to 564 days. The mean serum glucose level in the X-irradiated group was significantly lower than that in the non-irradiated animals at the 18 month time point. The total tumor incidence was 27/30 (87.1%) in the treated rats (islet tumors, gastric tumors, sarcomas, seminomas, adrenal tumors, kidney tumors, papilloma, lymphomas and mammary tumors). Islet tumors, generally showed to be positive for insulin by immunohistochemistry, developed in 19 rats (63.3%), and were associated with low serum glucose. Since spontaneous tumors observed in 6/19 (31.6%) rats (sarcomas, kidney tumors, duodenum tumors, seminoma, adrenal tumor and squamous cell carcinoma) did not include any insulinomas, these are clearly induced by X-irradiation in OLETF rats.

Introduction

Insulinoma, arising from the β -islet cells in the Langerhans islets, is one of the most common endocrine tumors of the pancreas with an annual incidence of 0.5 per million population (1). Experimental models for insulinomas induced by X-irradiation (2-4) or chemicals (5,6) have been reported and we previously described the induction of pancreatic tumors by local X-irradiation in Sprague-Dawley (SD) rats (7,8). The Otsuka Long-Evans Tokushima Fatty (OLETF) rats were developed as an animal model of type II diabetes with obesity by Kawano *et al* (9) and exhibited a late onset of chronic and slowly progressive hyperglycemia, with innate polyphagia

causing rapid body weight gain, hyperinsulinemia and hyperglycemia. Insulin resistance appears at 12-24 weeks of age, and overt diabetes develops at 20-30 weeks. At later than 40 weeks the rats become hypoinsulinemic, and exhibit defects in insulin secretion (9-11). Histologically, the OLETF rats also show progressive fibrosis in the pancreas (9,12). After 20 weeks, fibrosis and the enlargement of the islets clustered in connective tissue become prominent. After 40 weeks, the islets are increasingly replaced by connective tissues and by 70 weeks the pancreas is extremely atrophic and replaced by fatty and connective tissue. The number and size of the islets decreased significantly over time. Thus, the genetically obese hyperglycemic OLETF rat has many similarities with the human type II diabetes and its diabetic syndrome is characterized by a high degree of insulin resistance (13,14). In the present study, we examined its susceptibility to the induction of insulinoma by X-irradiation.

Materials and methods

Animals. OLETF (52, five-week-old male) rats were obtained from the Tokushima Research Institute, Otsuka Pharmaceutical Co., Tokushima, Japan (courtesy of Dr K. Kawano). They were housed in polycarbonate cages under constant conditions of temperature ($24 \pm 2^\circ\text{C}$), relative humidity ($55 \pm 10\%$) with a 12-h light/12-h dark cycle, according to the Guide for Care and Use of Laboratory Animals established by Hiroshima University, and fed an MF commercial diet (Oriental Yeast Co. Ltd., Tokyo, Japan).

X-irradiation. Rats were anaesthetized with Nembutal, and X-irradiated according to the method previously described (7,8). A 0.6-cm lead cover, with a hole of 1.8 cm in diameter, was positioned so that the hole lay over the gastric region. Each animal was given two X-ray doses of 10 Gy each, with a 3-day interval (total 20 Gy). Exposure factors were as follows: 200 kVp, filter 0.5 Cu + 1.0 Al, a half-value layer of 1.18 mm Cu, at a dose rate of 90 R/min as measured with a Radocon 555 dosimeter. The X-ray air dose (in R) was then converted to the absorbed dose (in cGy) using a factor of 0.95 cGy/R.

Correspondence to: Dr Hiromitsu Watanabe, Department of Experimental Oncology, Research Institute for Radiation Biology and Medicine, Hiroshima University, 1-2-3 Kasumi, Minami-ku, Hiroshima 734-8553, Japan
E-mail: tonko@hiroshima-u.ac.jp

Key words: insulinoma induction, X-irradiation, Otsuka Long-Evans Tokushima Fatty rat

Examination of animals. All animals were regularly observed and the survivors sacrificed and autopsied when they became moribund or at the end of the experiment after 564 days. All

Table I. Blood glucose values.

Group	X-irradiated		Non-treated		P-value
	No. of animals	Glucose (mg/dl)	No. of animals	Glucose (mg/dl)	
3 months	30	193.8±54.3 ^a	19	189.6±22.90	0.280
12 months	27	218.7±73.9	17	191.2±20.30	0.040
18 months	13	127.6±35.7	15	229.9±115.4	0.002

^aMean ± SD.

Table II. Body and organ weights (relative weights)^a.

Group	BW	Heart	Liver	Kidney	Testis	Adrenal	Spleen
X-irradiated	635.0±125.2 ^b	2.39±0.64 (0.39±0.13) ^c	20.33±4.77 (3.19±0.66)	3.77±0.72 (0.60±0.15)	2.71±0.77 (0.42±0.14)	0.09±0.05 (0.01±0.01)	1.58±1.03 (0.25±0.18)
Non-irradiated	657.3±108.4	2.01±0.22 (0.30±0.06)	22.33±3.30 (3.36±0.52)	3.89±0.78 (0.59±0.17)	2.76±1.04 (0.43±0.16)	0.08±0.02 (0.01±0.004)	2.20±1.96 (0.35±0.33)

^aOrgan/body weight x 100. ^bMean ± SD. ^cSignificantly different from the non-irradiated value (P<0.01).

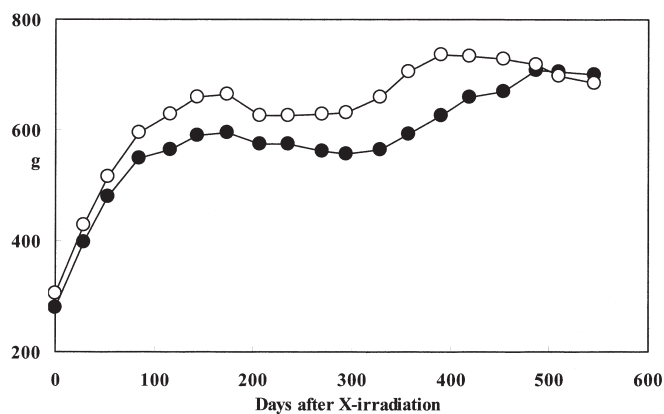


Figure 1. Body weights. ●, X-irradiated; ○, non-irradiated.

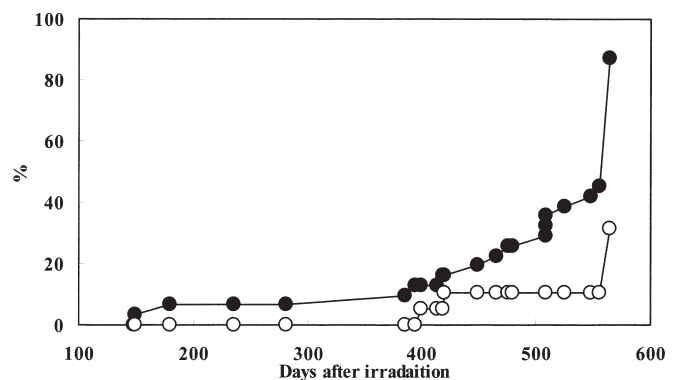


Figure 2. The induction of tumors in OLETF rats by X-irradiation. ●, X-irradiated; ○, non-irradiated.

major organs and tissues were resected, fixed in 10% neutral formalin and processed routinely to paraffin-embedded sections stained with hematoxylin and eosin.

Immunohistochemistry. Pancreatic tumors were fixed in formalin and then routinely processed for embedding in paraffin, sectioned, dewaxed, and incubated for 30 min at room temperature with rabbit anti-insulin antibodies (purchased from Shandon-Lipshaw, Pittsburgh, PA, USA). The sections were then sequentially incubated with a biotin-labeled secondary antibody and treated for demonstration of the binding sites.

Statistical analysis. The significance of differences in the numerical data was evaluated using the Chi-square test,

Student's t-test and Cox proportional hazard model for multiple comparisons using logarithmic transformation.

Results

Data for the change in body weights over time are shown in Fig. 1. The values for the non-irradiated controls were significantly greater than those in the irradiated animals from 1 month after irradiation until day 486.

Serum glucose values, 3 months after irradiation, did not significantly differ between the groups, but after 18 months the levels (127.6±35.7 mg/dl) in the X-irradiated group were significantly lower than those in the non-irradiated controls (230±115 mg/dl) (P<0.01, Table I).

Table III. The induction of tumors.

	Mean survival (days)	Incidence of tumors (%)	No. of tumors per animal	Islet tumors (%)	Sarcomas (%)	Gastric tumors (%)	Other tumors
X-irradiated	473.9±127.4 ^a	27/30 (87.1) ^b	1.3±1.1 ^b	19/30 (63.3) ^b No. per animal 1.5±0.7 Size 3.5±2.3 mm	7/30 (23.3)	5/30 (16.7)	Seminoma 2 Adrenal 2 Kidney 1 Squamous cell carcinoma 1 Papilloma 1 Lymphoma 1 Mammary 1
Non-irradiated	525.6±92.1	6/19 (31.6)	0.5±0.8	0	3/19 (15.7)	0	Kidney 2 Duodenum 2 Seminoma 1 Adrenal 1 Squamous cell carcinoma 1

^aMean ± SD. ^bSignificantly different from the non-irradiated value (P<0.01).

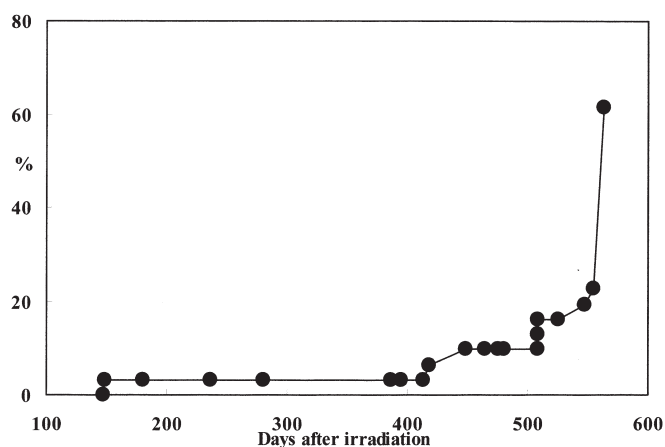


Figure 3. The induction of islet tumors by X-irradiation in OLETF rats. ●, X-irradiated.

After irradiation (564 days) all surviving animals were autopsied. The mean survival was not significantly influenced by irradiation. The organ weights did not significantly vary between the groups, although the heart relative weights in the X-irradiated group were significantly greater than those in the non-irradiated group (Table II). The first tumor appeared 149 days after X-irradiation, with a gradually increasing incidence thereafter (Fig. 2). The final total tumor incidence in the X-irradiated group (27/30, 87.1%) was significantly greater than that in the non-irradiated group (6/19, 31.6%) (P<0.01, Table III). The cumulative tumor incidence was also significantly different between the X- and non-irradiated

groups (Fig. 3, P=0.015). Islet tumors of the pancreas (Fig. 3) appeared in 19 X-irradiated animals (63.3%), sarcomas in 7 (23.3%) and gastric tumors in 5 (16.7%). Single examples of mammary tumors, lymphomas, seminomas, adrenal tumors, squamous cell carcinomas and papillomas were also noted. In the non-irradiated group, three sarcomas, 2 kidney and duodenum tumors, 1 seminoma, an adrenal tumor and a squamous cell carcinoma were observed.

The pancreata of non-irradiated animals were extremely atrophic and the numbers and sizes of the islets were reduced (Fig. 4). The islets of the irradiated rats, in contrast, were enlarged. Acinar cells were atrophic and degenerated and replacements by adipocytes and cell infiltration were observed. Immunohistochemistry showed the islet tumor cells to be generally positive against insulin antiserum (Fig. 5).

Intestinal metaplasia with ALP activity on the histopathological examination was more frequent in the X-irradiated than in the non-irradiated groups (Table IV).

Discussion

The present study showed that the OLETF rat is very susceptible to the induction of pancreas islet tumors, putative insulinomas positive for insulin staining and associated with a decrease of serum glucose concentration, by X-irradiation to the gastric region. We previously described islet tumors of the pancreas in 18% of Crj rats receiving the same two 10 Gy doses to the gastric region with a 3-day interval (total 20 Gy) (7). Boschetti *et al* (3) reported an 11.4% incidence of islet cell tumors in non-inbred Wistar rats treated with 430 rads of total body X-irradiation while the same treatment resulted in a 2.2% incidence in inbred Wistar Furth rats. Kido *et al* (8)

Table IV. Intestinal metaplasia incidences and numbers.

Group	Alkaline phosphatase	Pylorus				Fundus			
		A	B	C	Total	A	B	C	Total
X-irradiated	78.6% 174.8±179.1 ^{a,c}	53.3% 1.3±1.4 ^c	100% 39.8±36.2 ^c	86.7% 8.9±11.1 ^c	100% 50.1±46.6 ^c	6.7% 0.1±0.3	53.3% 6.4±9.0 ^c	40.0% 1.9±3.1 ^b	53.30% 8.3±10.6 ^c
Non-treated	71.4% 15.2±16.00	0% 0	100% 4.7±5.00	7.1% 0.1±0.30	100% 4.8±4.90	0 0	0 0	0 0	0 0

Alkaline phosphatase activity in gastric mucosa. A, goblet cells in gastric mucosa; B, intestinal crypts without Paneth cells and C, intestinal crypts with Paneth cells. ^aMean ± SD. ^bSignificantly different from the non-irradiated value (P<0.05). ^cSignificantly different from the non-irradiated value (P<0.01).

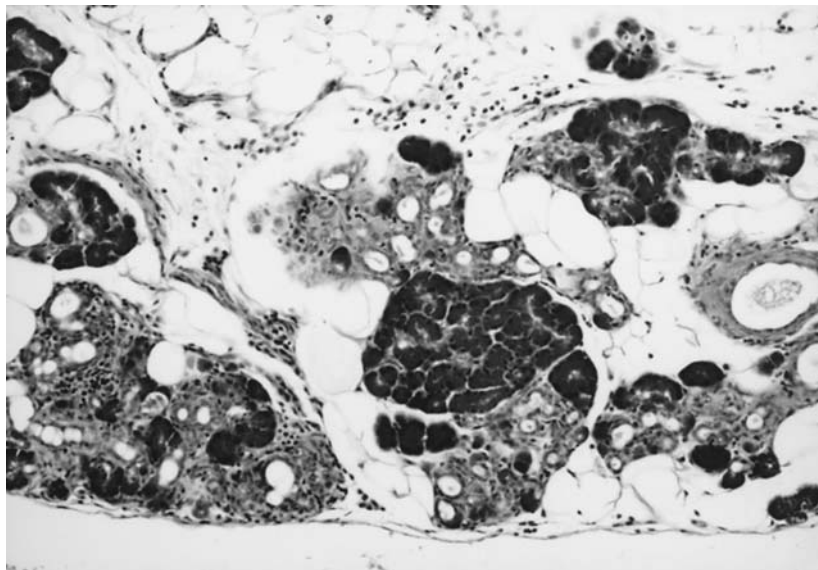


Figure 4. The pancreas of a non-irradiated control rat, x100 HE staining.

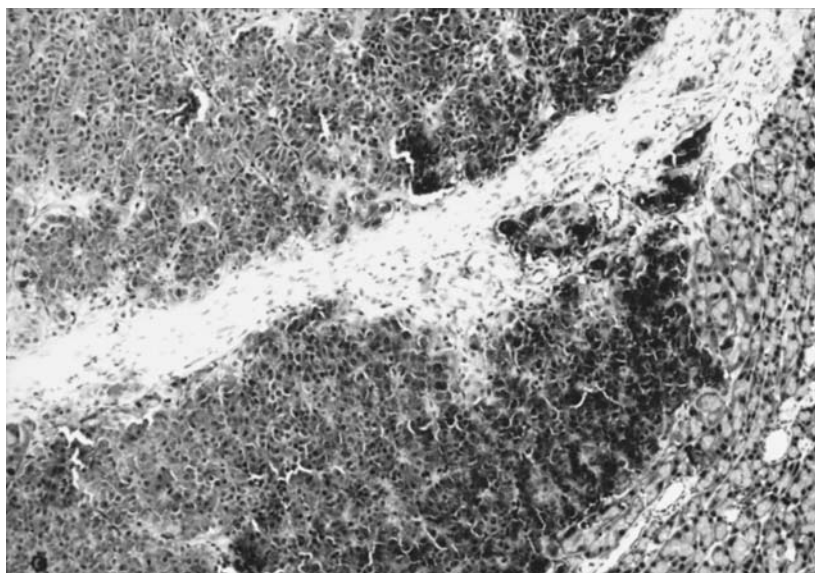


Figure 5. Immunostaining of an islet tumor for insulin, x100.

performed a localized X-irradiation to the gastric region of SD rats and induced a very high incidence of pancreatic tumors (25/28, 89.3%), most of which showed positive immunoreactivity for rat insulin and expressed insulin mRNA, as confirmed by Northern blot analysis. They also reported an inverse correlation between the serum insulin and glucose level and concluded that the pancreatic tumors induced by X-irradiation were functional insulinomas. In the present study, there was no examination of serum insulin, but the pancreatic tumors were anti-insulin antigen positive. In the aged OLETF rats, the exocrine and endocrine pancreas is extremely atrophic, and is replaced by fatty and connective tissues. The number and size of the islets decreases significantly (9,12,16-18) in line with the development of type II diabetes (9). Therefore, by inducing insulinomas X-irradiation allowed for the control of serum glucose levels to be maintained.

Gross and Dreyfuss reported a 10% incidence of spontaneous tumors in male Long-Evans rats, the lesions being fibromas, fibrosarcomas or leukemias and lymphomas (15). Pituitary tumors (19-21), multiple endocrine neoplasia syndrome (21), pancreatic tumors (21-23) and skin lesions (24) have been reported in aging Long-Evans rats. The Long-Evans Cinnamon rat, a mutant, features hepatitis and spontaneous liver tumors (25,26). As with the Eker model, Long-Evans rats typically develop multiple renal tumors (27). Thus, there may be certain differences in the spontaneous development of tumors between Long-Evans, substrain and OLETF rats.

In conclusion, OLETF rats may provide a useful strain to investigate insulinomas induced by X-ray irradiation.

Acknowledgements

We would like to thank Dr Malcolm Moore for his critical reading of the manuscript and Mr. T. Nishioka for his technical assistance.

References

- Porzio O, Rossi G, Biscardi A, *et al*: Insulinoma. Clinical and surgical considerations concerning a case. *Minerva Chir* 52: 289-293, 1997.
- Lamson BG, Meek RA and Bennett LR: Late effects of total-body roentgen irradiation. II. The influence of fractionated and single radiation doses on the incidence of tumors, nephrosclerosis, and adrenal vacuolation in Wistar rats during various periods of post-irradiation survival. *AMA Arch Pathol* 64: 505-521, 1957.
- Boschetti AE and Moloney WC: Observations on pancreatic islet cell and other radiation-induced tumors in the rat. *Lab Invest* 15: 565-575, 1966.
- Rosen VJ, Castanera TJ, Kimeldorf DJ and Jones DC: Pancreatic islet cell tumors and renal tumors in the male rat following neutron exposure. *Lab Invest* 11: 204-210, 1962.
- Kazumi T, Yoshino G and Baba S: Pancreatic islet cell tumors found in rats given alloxan and nicotinamide. *Endocrinol Jpn* 27: 387-393, 1980.
- Yamagami T, Miwa A, Takasawa S, Yamamoto H and Okamoto H: Induction of rat pancreatic B-cell tumors by the combined administration of streptozotocin or alloxan and poly (adenosine diphosphate ribose) synthetase inhibitors. *Cancer Res* 45: 1845-1849, 1985.
- Watanabe H, Tanizaki M and Fujimoto N: Induction of insulinomas and kidney tumors in SD male rats by X-irradiation of the gastric region. *J Toxicol Pathol* 10: 77-81, 1997.
- Kido S, Haruma K, Kitadai Y, Yoshihara M, Sumii K, Kajiyama G and Watanabe H: Enhanced tumorigenicity of insulinoma by X-irradiation of the gastric regions in Sprague-Dawley male rats. *J Gastroenterol Hepatol* 15: 766-770, 2000.
- Kawano K, Hirashima T, Mori S, Saitoh Y, Kurosumi M and Natori T: Spontaneous long-term hyperglycemic rat with diabetic complications. Otsuka Long-Evans Tokushima Fatty (OLETF) strain. *Diabetes* 41: 1422-1428, 1992.
- Yamamoto M, Jia DM, Fukumitsu KI, Imoto I, Kihara Y, Hirohata Y and Otsuki M: Metabolic abnormalities in the genetically obese and diabetic Otsuka Long-Evans Tokushima Fatty rat can be prevented and reversed by an alpha-glucosidase inhibitor. *Metabolism* 48: 347-354, 1999.
- Jia DM, Tabaru A, Nakamura H, Fukumitsu KI, Akiyama T and Otsuki M: Troglitazone prevents and reverses dyslipidemia, insulin secretory defects, and histologic abnormalities in a rat model of naturally occurring obese diabetes. *Metabolism* 49: 1167-1175, 2000.
- Yoshikawa H, Kihara Y, Taguchi M, Yamaguchi T, Nakamura H and Otsuki M: Role of TGF-beta1 in the development of pancreatic fibrosis in Otsuka Long-Evans Tokushima Fatty rats. *Am J Physiol Gastrointest Liver Physiol* 282: G549-G558, 2002.
- Ishida K, Mizuno A, Min Z, Sano T and Shima K: Which is the primary etiologic event in Otsuka Long-Evans Tokushima Fatty rats, a model of spontaneous non-insulin-dependent diabetes mellitus: insulin resistance, or impaired insulin secretion? *Metabolism* 44: 940-945, 1995.
- Okauchi N, Mizuno A, Zhu M, Ishida K, Sano T, Noma Y and Shima K: Effects of obesity and inheritance on the development of non-insulin-dependent diabetes mellitus in Otsuka-Long-Evans-Tokushima fatty rats. *Diabetes Res Clin Pract* 29: 1-10, 1995.
- Gross L and Dreyfuss Y: Spontaneous tumors in Sprague-Dawley and Long-Evans rats and in their F1 hybrids: carcinogenic effect of total-body X-irradiation. *Proc Natl Acad Sci USA* 76: 5910-5913, 1979.
- Hong EG, Noh HL, Lee SK, Chung YS, Lee KW and Kim HM: Insulin and glucagon secretion, and morphological change of pancreatic islets in OLETF rats, a model of type 2 diabetes mellitus. *J Korean Med Sci* 17: 34-40, 2002.
- Jia D, Taguchi M and Otsuki M: Synthetic protease inhibitor camostat prevents and reverses dyslipidemia, insulin secretory defects, and histological abnormalities of the pancreas in genetically obese and diabetic rats. *Metabolism* 54: 619-627, 2005.
- Ashizawa N, Hamamoto N and Kinoshita Y: Morphological changes of pancreatic ducts in Otsuka Long-Evans Tokushima Fatty rats. *Pancreas* 32: 417-421, 2006.
- Griesbach WE: Basophil adenomata in pituitary glands of 2-year-old male Long-Evans rats. *Cancer Res* 27: 1813-1818, 1967.
- Kovacs K, Horvath E, Bilbao JM and Ilse RG: *Annulate lamellae* in spontaneous prolactin cell adenomas of the rat pituitary. *Anat Anz* 141: 59-65, 1977.
- Lee AK, DeLellis RA, Blount M, Nunnemacher G and Wolfe HJ: Pituitary proliferative lesions in aging male Long-Evans rats. A model of mixed multiple endocrine neoplasia syndrome. *Lab Invest* 47: 595-602, 1982.
- Kovacs K, Horvath E, Ilse RG and Ilse D: Spontaneous pancreatic beta cell tumor in the rat. A light and electron microscopic study. *Vet Pathol* 13: 286-294, 1976.
- Spencer AJ, Andreu M and Greaves P: Neoplasia and hyperplasia of pancreatic endocrine tissue in the rat: an immunocytochemical study. *Vet Pathol* 23: 11-15, 1986.
- Esfandiari A, Loya T and Lee JL: Skin tumors in aging Long-Evans rats. *J Natl Med Assoc* 94: 506-510, 2002.
- Yoshida MC, Masuda R, Sasaki M, Takeichi N, Kobayashi H, Dempo K and Mori M: New mutation causing hereditary hepatitis in the laboratory rat. *J Hered* 78: 361-365, 1987.
- Mori M, Hattori A, Sawaki M, *et al*: The LEC rat: a model for human hepatitis, liver cancer, and much more. *Am J Pathol* 144: 200-2004, 1994.
- Eker R and Mossige JA: A dominant gene for renal adenocarcinomas in the rat. *Nature* 189: 858-859, 1961.