

Comparative Observations on Inhibition of Ovarian Development in Larval *Rana japonica* (Anure:Ranidae) Treated with Testosterone During Different Stages of Development

Terukiyo SHIRANE

*Department of Informational and Behavioral
Sciences, Faculty of Integrated Arts and Sciences,
Hiroshima University*

Received October 31, 1990

ABSTRACT

In order to investigate the effects of testosterone upon the inhibition of ovarian development, larvae of the ranid frog *Rana japonica* were treated with testosterone at different developmental stages, and their gonads examined at several subsequent larval stages. In larvae of genetic females treated with testosterone during Stages I - III, nests of germ cells (ovarian cords) were less well formed than in normally developing ovaries (Stage V). Secondary ovarian cavities formed late, and only a few germ cells initiated oogenesis (Stage XV). In these ovaries, significant proliferation of medullary cells for masculinization took place only after successive rounds of oogenesis had ceased completely. By contrast, in larvae exposed to testosterone during Stages III - X, the primitive nests of germ cells were formed normally, but the new nests corresponding to proliferation of germ cells were poorly formed owing to the presence of only few somatic cells. The replicated germ cells were arranged within primordial nests so as to form a colony (a kind of cyst); few cells participated in oogenesis. Although the medullary cells proliferated significantly during the period of treatment with testosterone, their morphogenesis for masculinization took place after the cysts of germ cells had moved completely away from the epithelium. These events suggest that the masculinization caused by treatment with testosterone is induced by stagnation of the development of the somatic cells at gonadal cortex rather than by the proliferation of medullary cells.

There have been many experiments on the effects of sex hormones and other substances upon sex determination and gonadal differentiation (for review, see Witschi, '67; Vannini, '75; Lepori, '80). Most were designed to determine whether or not sex reversal was induced by a particular treatment and to identify the periods during the developmental cycle that were sensitive to such treatments. A few studies have involved the effects of treatment with drugs on the development of individual components of the gonads.

In *Rana japonica* and *R. nigromaculata*, all germ cells in the gonads of larvae treated with

testosterone decrease in size in the same way as those in normally developing, genetic males prior to initiation of gonadal histogenesis (Shirane, '86). Although the decrease in size of germ cells is surely the first characteristic of testicular development in some anurans, the following questions remain to be answered with respect to masculinization of female gonads. How does testosterone treatment influence the reduction in the size of germ cells, and to what degree is the direction of gonadal development defined under such conditions?

In the present study designed to elucidate the effects of testosterone upon each component of gonads, larval *Rana japonica* were treated with testosterone at different developmental stages, and their gonads were examined and compared histologically at several subsequent larval stages. Based on the results, the effects and control of testosterone on the successive stages of gonadal development are described.

MATERIALS AND METHODS

Eggs of *Rana japonica* Guenther were collected from natural spawns, and separated into six groups that were reared in the laboratory at room temperature. One group received no special treatment (control group). The five remaining groups were divided into two series for testosterone treatment as follows: Series 1. TK I - III group, TK I - V group, and TK III - X group; Series 2. TK I - III group and TK III - X group. The experimental larvae were reared in water that contained 50 $\mu\text{g}/\text{l}$ testosterone during specific developmental stages, as described by Richards and Nace ('78). In Series 2, hormonal treatment was initiated and discontinued about 24 hr later in Stage III than in Series 1. These periods of treatment with testosterone were chosen because (1) gonadal dimorphism in the size of germ cells becomes apparent at Stage TK III (Shirane, '86); (2) gonadal differentiation (i. e., formation of nests of germ cells in presumptive ovaries) can be recognized histologically at TK V; and (3) the initial organogenesis of gonads (i. e., initial round of oogenesis in ovaries and migration of germ cells among medullary cells in testes) is nearly complete at TK X (Shirane, '87). The culture water was changed three times a week and prepared fresh on each occasion. The room temperature varied from 11-16 $^{\circ}\text{C}$, and the water temperature was always 1-2 $^{\circ}\text{C}$ lower than room temperature. Larvae were staged following Taylor and Kollros ('46).

Animals were killed at various developmental stages: TK V, X, XV, XX, and XXV in Series 1; and TK XV, XX, XXV in Series 2. Gonads were fixed in Bouin's solution, cut into 8- μm serial paraplast sections, and stained with haematoxylin-eosin for histological examination.

RESULTS

None died for developmental anomalies during larval period in each series.

Series 1

Results of histological observations of the gonads of control and testosterone-treated larvae of *R. japonica*, examined at various developmental stages appear in Table 1. Histological observa-

tions reported below involve mainly the gonadal development of the female genotype.

Table 1. The results of an examination of the gonadal sex of animals derived from *Rana japonica* larvae treated with testosterone at specific stages of development.

Larval stages examined	Treatment with testosterone															
	Control				TK I-III				TK I-V				TK III-X			
	F*	I	M	Total	F	I	M	Total	F	I	M	Total	F	I	M	Total
<i>Series 1</i>																
V	5	0	5	10	5	0	6	11	0	4	6	10	5	0	5	10
X	7	0	4	11	6	0	4	10	0	5	5	10	0	4	6	10
XV	4	0	6	10	5	0	5	10	0	2	8	10	0	6	5	11
XX	6	0	5	11	4	2	4	10	0	0	10	10	0	0	8 (5)	8
XXV	4	0	7	11	0	5	6	11	0	0	11	11	0	0	12 (5)	12
<i>Series 2</i>																
XV	6	0	4	10	0	5	5	10	—	—	—	—	0	2	3	5
XX	5	0	5	10	0	6	4	10	—	—	—	—	0	6	4	10
XXV	5	0	7	12	0	0	13 (7)	13	—	—	—	—	0	0	10 (4)	10

* F, I and M indicate female, intersex and male, respectively.
The numbers in parentheses show the numbers of larvae with abnormal testes (see text).

Stage TK V

The presumptive ovaries in the control group had small masses of medullary cells arranged segmentally from the anterior to the posterior part of the gonads (Fig. 1A₁; Shirane, '86). In contrast, most of the germ cells already had lost their yolk platelets and had multiplied within the nests. Thus, a vacant space in the nests was rarely observed (Fig. 1A₂). In the TK I-III group, five of 11 animals examined had ovarylike gonads. There were so many medullary cells in these gonads that they nearly came in contact with germ cells and hindered the formation of nests; however the primitive genital cavities were present, there was no evidence of invasion by medullary cells (Fig. 1B₁). Many germ cells retained several yolk platelets as did those in the testes of the control larvae. Nest formation around germ cells was poor, although the primitive cavities appeared to develop efficiently (Fig. 1B₂). In the TK I-V group, four of 10 larvae examined were regarded as genetic females. The masses of medullary cells in the gonads of these four larvae maintained a segmental arrangement, although the cells were somewhat loose and dispersed. In the TK III-X group, five larvae seemed to be genetic females based on their gonadal structure. However, medullary cells in these gonads proliferated so

many that they obstructed the formation of the nests of germ cells (Fig.1C₁). The portions of the primitive cavities were extremely shrivelled, though the nests of germ cells were formed to a certain degree (Fig.1C₂). Although not all germ cells in these gonads had completely digested their yolk platelets, some of them appeared to be proliferating within poorly formed nests, as in the ovaries of control larvae.

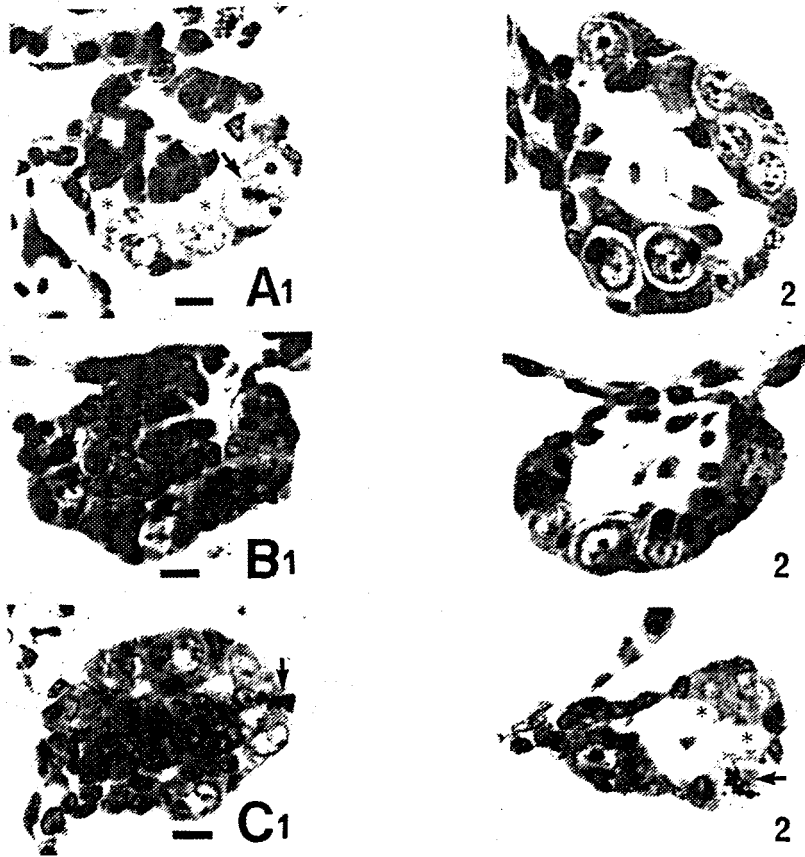


Fig.1. Cross sections of gonads in larvae of the female genotype at Stage V. Bar= 10 μ m. A1 and 2. Presumptive ovaries in normally developing larvae (control). B1 and 2. Larvae treated with testosterone during the period from Stages I - III. C1 and 2. Larvae treated with testosterone from the Stage III - X. Symbols indicate evidence of division of germ cells (arrows) and nests of germ cell (asterisks), respectively.

Stage TK X

Seven of 11 animals in the control group were females. The secondary genital cavities (ovarian cavities) were formed by the medullary cells in their gonads. In the so-called cortex, mesenchymal and epitherial (M/E) cells as well as the germ cells proliferated markedly, and arranged around the germ cells to form new nests. In this paper, the term "M/E cells" refers to somatic cells that have proliferated at the periphery of the gonads, because it has proved difficult to confirm whether they originate from mesenchymal or epithelial cells, or from both.

(Merchant-Larios and Villalpando [81] reported that mesenchymal cells originate from the epithelial cells.) Some nests differentiated into ovarian cords in which a few synaptic oocytes were present. In the TK I - III group, six of 10 animals seemed to be genetic females. Medullary cells were much less proliferated in their ovaries than those of the preceding stage. The M/E cells were increased in less number than the germ cells did, consequently, some germ cells did not seem to be associated with the formation of new nests (Fig.2B). Rarely, the synaptic oocytes, indicative of the initiation of oogenesis, were partially visible within the incompletely formed cords of such ovaries. In the TK I - V group, five of 10 larvae were regarded as genetic females, because the medullary cells did not disperse completely as did those in the gonads of normally developing, genetic males. However, the formation of ovarian cavities was scarcely observed in these gonads. Some germ cells appeared to have already migrated among the medullary cells. In the TK III - X group, four larvae had gonads that consisted of many medullary cells and of a small number of ovarian cords. The medullary cells increased markedly in number, but their migration among germ cells was obstructed with the ovarian cords. These cords were assumed to have been formed directly from the primordial nests of germ cells, because these were fewer cords than in the ovaries of normally developing larvae at the same stage. Although the germ cells within the cords seemed to proliferate and form a kind of colony without forming new cords, none showed any characteristic evidence of oogenesis in any of the gonads of the female genotype.

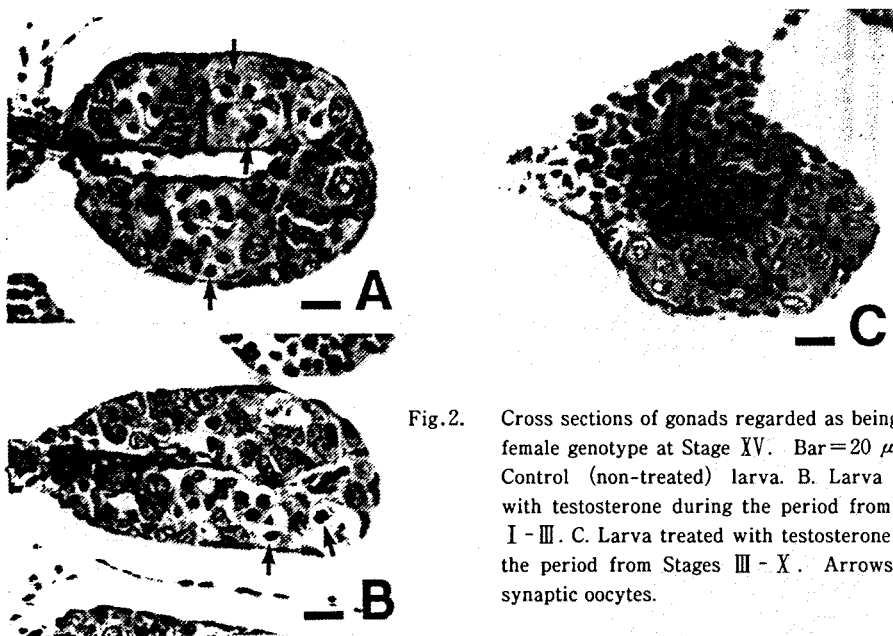


Fig.2. Cross sections of gonads regarded as being of the female genotype at Stage XV. Bar=20 μ m. A. Control (non-treated) larva. B. Larva treated with testosterone during the period from Stages I - III. C. Larva treated with testosterone during the period from Stages III - X. Arrows depict synaptic oocytes.

Stage TK XV

The ovaries of larvae in the control group evidenced active proliferation of germ cells, and contained a few auxocytes and many synaptic oocytes (Fig.2A). In the TK I - III group, five of 10 larvae were female. The differentiation of the ovarian cavities occurred later than in the

ovaries of control animals. The formation of ovarian cords was still so incomplete that some germ cells were free from the cords. Nevertheless, some synaptic oocytes were observed within some incomplete and small cords (Fig.2B). There were no auxocytes in these gonads. In the TK I - V group, the gonads of all animals examined were defined histologically as testes, except for the gonads of two animals that had poorly and partially differentiated ovarian cavities. In this experimental group, no animals had gonads with ovarian characteristics after this stage. In the TK III - X group, six of 11 animals were female. The structure of their gonads was nearly the same as that of larvae from the preceding stage, except for the appearance of a few degenerating germ cells within cysts derived from ovarian cords (Fig.2C).

Stage TK XX

In the ovaries of control animals, several auxocytes appeared to be arranged along the ovarian cavities, and some synaptic oocytes were seen at the outer portions of the gonads (Fig.3A); this indicates initiation of successive rounds of oogenesis. In the TK I - III group, six of 10 larvae were female. Four of the six had underdeveloped ovaries which contained a few smaller auxocytes. Differentiation of ovarian cords was still incomplete, and the products of successive rounds of oogenesis (synaptic oocytes) were observed rarely at this stage. The medullary cells were locally (or partially) increased in number, but none had migrated among the germ cells (Fig.3A). The other two larvae (the column, designated as intersex in Table

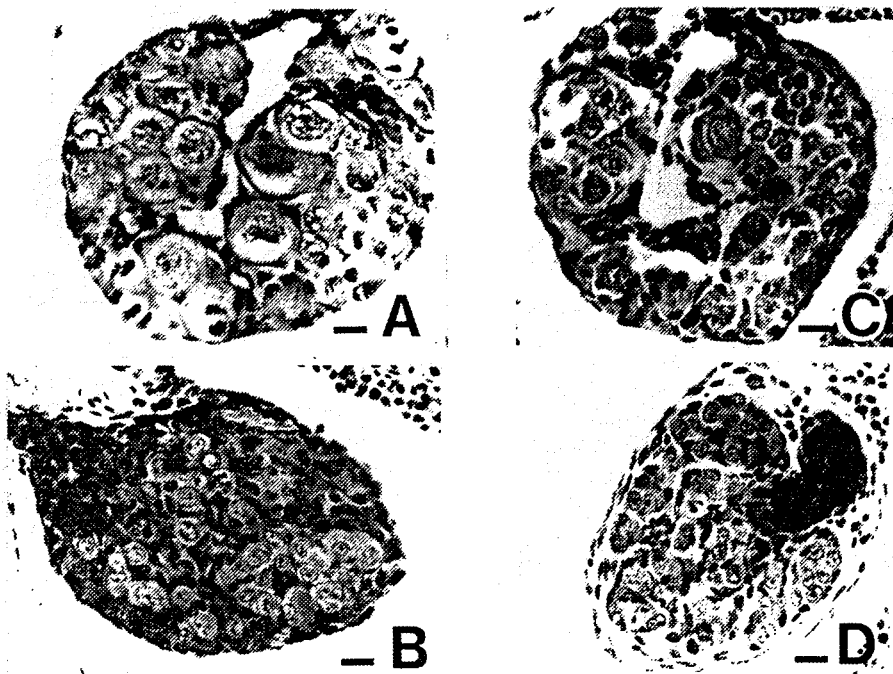


Fig.3. Cross section of gonads regarded as being of the female genotype at Stage XX. Bar=20 μ m. A. Ovary of control animal. B. Testis of control animal. C. Ovary of larva treated with testosterone during the period from Stages I - III. D. Abnormal gonad of larva regarded as being of the female genotype, derived from larvae treated with testosterone during the period from Stages III - X.

1) had testislike gonads, except for the presence of some auxocytes and the degenerating ovarian cavities. In the TK III - X group, five of eight larvae examined had characteristic gonads (Fig.3D). These larvae were regarded as having a female genotype but are counted as males in Table 1. Their gonads lacked any typical ovarian characteristics and differed significantly in structure from proper testes at the same stage (Fig.3B). Thus, medullary cells were present as masses in several regions of the gonads, and the cysts of germ cells had moved away completely from the epithelium. A few medullary cells had begun to migrate among the cysts, but not among the germ cells.

Stage TK XXV

There were so many auxocytes of various size in the ovaries of the control group that the ovarian cavities could not be distinguished. In the TK I - III group, five animals had the gonadal structure of genetic females. Two retained ovarylike gonads with respect to the existence of large numbers of auxocytes. However, the medullary cells of these gonads had begun active proliferation and begun to migrate among germ cells in several regions; this suggests initiation of masculinization (Fig.4A). The other three animals had testislike gonads in which the germ cells, together with a few auxocytes, were mingled with the medullary cells. In the TK III - X group, five of 12 animals examined were regarded as genetic females based on the abnormal structures of their gonads. In four of these animals, medullary cells had migrated among the cysts of germ cells as if preparing to form seminiferous tubules. The other female had gonads with some degenerating cords which had a lacunae instead of oocytes (Fig.4B).

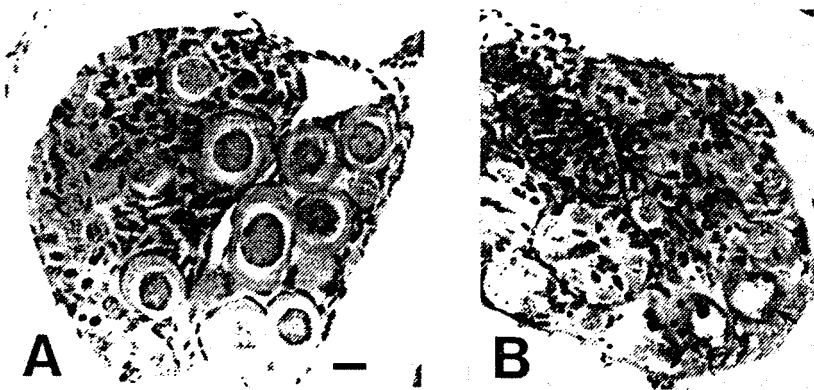


Fig.4. Cross sections of the intersex gonads in animals at Stage XXV. Bar=20 μ m. A. Larva treated with testosterone during the period from Stages I - III. Somatic cells proliferated markedly and began to surround some indifferent germ cells and auxocytes (diplotenic oocytes). B. Animal treated with testosterone during the period from Stages III - X. The lower part of this gonad has lacunae that suggest the existence of some degenerating oocytes (arrows), and this area itself was also degenerating.

Series 2

Stage TK XV

In the TK I - III group, five of 10 animals were female, as judged from the presence of six independent masses of medullary cells. In their gonads, germ cells as well as M/E cells seemed to multiply, and both cell types were intermingled. Successful formation of ovarian cords was rarely observed in these gonads, and no germ cells evidenced oogenesis. Although the medullary cells were proliferated in each medulla, no cells had migrated among the germ cells. In the TK III - X group, two of five animals were regarded to have the female genotype based on the presence of segmental medullae. The medullary cells had increased in number, but there was no evidence of ovarian cavity formation. The number of ovarian cords was small, as mentioned for the same group in Series 1. A few synaptic oocytes were observed within the cords.

Stage TK XX

In the TK I - III group, six of 10 animals examined were of the female genotype. Medullary cells were still present as separate masses in their gonads, but these cells had not migrated into the genital cortex (i. e., among the germ cells). The germ and M/E cells in these gonads seemed to multiply slightly more frequently than those in gonads of similarly treated larvae at the preceding stage. Furthermore, the M/E cells, were loosely grouped with a few germ cells, as indicated by the delayed formation of ovarian cords. However, no germ cells evidenced initiation of oogenesis within such incomplete cords. In the TK III - X group, six of 10 animals were of the female genotype with their gonadal medullary cells located primarily in the middle of the gonads. The ovarian cords were larger than those of the preceding stage. Some germ cells appeared to be loosely separated within these cords by a few M/E cells, as observed after the formation of new cords, in which some oocytelike germ cells were observed to be degenerating. In addition, some underdeveloped cords with a few germ cells were already surrounded by medullary cells.

Stage TK XXV

In the TK I - III group, seven of 13 animals had histologically abnormal testes. The cysts of germ cells, which originated from the primitive ovarian cords, appeared to have moved completely away from genital epithelium, as described for the TK III - X group of Series 1. Some medullary cells had begun to migrate among the cysts. In the TK III - X group, no animals examined had gonads with any traces of ovarian development. However, four males (4/10) had small testes (i. e., ca. 66 % of the length and width of normal testes). The number of germ cells in these testes was less than that in testes of the other males. This suggested that these gonads might have been derived from underdeveloped ovaries in which the ovarian cords had contracted completely and degenerated after some oocytes failed to complete oogenesis.

DISCUSSION

The results suggest that there are three principal events that merit consideration—viz., (1) differentiation of germ cells, (2) development of M/E cells, and (3) proliferation of medullary cells.

The first problem to be addressed is the influence of testosterone on the size reduction of germ cells during the period of the initial determination of gonadal sex. As reported by Shirane ('86), migrating and exogonadal primordial germ cells (PGCs) are not reduced in size by testosterone treatment. In the TK I - III group, the germ cells in larvae of the female genotype at Stage V retained several yolk platelets during primary histogenesis of gonads, as did germ cells in the control larvae of the male genotype. Subsequently, some of the gonadal germ cells began the delayed process of oogenesis. In the TK III - X group, by contrast, germ cells in female larvae at Stage V rapidly digested their yolk platelets and initiated cell division in the presence of testosterone, as did control larvae of the female genotype. However, none achieved successful oogenesis. These observations indicate that testosterone did not necessarily define the fate of all germ cells during the period of initial determination of gonadal sex, even though the germ cells were reduced in size similarly to those in gonads of larvae of the male genotype. However, the developmental direction of germ cells seemed to be defined to a large degree during this period in normally developing larvae. Thus, reduction in size of germ cells seems not to be a direct effect of testosterone.

The second question concerns the effect of testosterone on development of M/E cells. In the TK I - III group, the gonadal M/E cells in larvae of the female genotype seemed slowly to recover the proper characteristics required for development as ovaries. However, these gonads did not differentiate completely into ovaries, because their delayed development was sufficiently incomplete to permit subsequent continuous oogenesis. In contrast, the M/E cells in the TK III - X group did not seem to form additional cords in response to the proliferation of germ cells. The few germ cells within such cords rarely participated in oogenesis, and soon degenerated.

It is relevant to this discussion that a specific substance (peanut-lectin-affinity molecule) on primordial germ cells (PGCs) plays an important role in the initial determination of gonadal sex in anura (Shirane, '87). The synthesis of such a substance (i. e., stimulant) perhaps is restricted to a certain period of the life cycle. If this is these, it is possible, in the TK I - III groups, that the amount of stimulant would become so less during the period of testosterone treatment that the M/E cells would be activated fully for subsequent ovarian development. This does not mean that testosterone would inhibit directly the sensitivity of M/E cells to the stimulant. Therefore, testosterone treatment seems to act only to obstruct a favorable interaction between the germ cells and the M/E cells. Consequently, the delayed-ovarian development as well as the size reduction of germ cells may be resulted by treating with testosterone during the Stages TK I - III. In the TK III - X groups, also, it is possible that testosterone would act similarly to obstruct an appropriate contact of the germ cells with the M/E cells. In addition, because the extent of oogenesis clearly differed among each of the experimental groups, it seems that the beginning and course of oogenesis depend on the degree of differentiation of the cords (M/E cells). In other words, the initial process of oogenesis may be controlled, step by step,

by interactions between the germ cells and M/E cells that constitute the ovarian cords.

The findings of Vannini et al. ('75) are relevant to these hypotheses. They reported that actinomycin D and puromycin failed to suppress the anti-oogenetic activity of testosterone, but did suppress its effect on medullary cells. Given the effects of actinomycin D (an inhibitor of DNA-dependent transcription of RNA) and puromycin (an inhibitor of mRNA-dependent synthesis of protein), it is not surprising that these drugs barely affected the anti-oogenetic activity of testosterone, because the information for gonadal development in both M/E and germ cells would not be induced if testosterone interfered with the appropriate contacts of germ cells with M/E cells. It may be not totally reasonable to compare the present results with those from the experiments with *Rana dalmatina* by Vannini et al. ('87). The latter is regarded as a species of undifferentiated race; however, it is noteworthy that a few auxocytes (large diplotenic oocytes) were present in the gonads of experimental females. Owing to the low number of auxocytes, they probably were derived from the first cluster of ovarian cords. Thus, testosterone as well as the other drugs tested could not completely inhibit oogenesis, which would continue to some extent when the larvae were exposed initially to drugs.

The third question invalues the effect of testosterone on medullary cells. Witschi ('57, '67) reported that the medullary cells multiply markedly during testosterone treatment. However, the cells do not evidence the active movement that is associated with morphogenesis required for masculinization of ovary before subsequent ovarian development at the cortex is apparent. A similar result was observed in the masculinization of underdeveloped ovaries of *Rana nigromaculata* larvae derived from UV-irradiated eggs; masculinization of underdeveloped ovaries containing a few germ cells took place without much proliferation of medullary cells at the earlier larval stages (Shirane, '84).

In contrast to its negative (or inhibitory) effect on M/E cells, testosterone has a positive (or stimulatory) effect on medullary cells. Although the medullary cells generally have been regarded as the main factors involved in masculinization of ovaries, the present results seem to contradict this concept, despite the fact that proliferation of medullary cells was required for morphogenesis of testes. Therefore, we conclude that the role of medullary cells in testicular organogenesis in anurans may be auxiliary, rather than antagonistic, to the differentiation of M/E cells.

引用文献

- Lepori, N. G. (1980) Sex Differentiation, Hermaphroditism and Intersexuality in Vertebrates including Man. Piccin Medical Books, Padua (Italy). pp 149-165.
- Merchant-Larios, H. & Villalpando, I. (1981) Ultrastructural events during early gonadal development in *Rana pipiens* and *Xenopus laevis*. Anat. Rec. 199,349-360.
- Richards, C. M. & Nace, A. W. (1978) Gynogenetic and hormonal sex reversal used in tests of XX-XY hypothesis of sex determination in *Rana pipiens*. Growth 42,319-331.
- Shirane, T. (1970) One the formation of germ cells of the frog's larvae from eggs irradiated with ultraviolet rays. Mem. Fac. Gen. Ed. Hiroshima Univ. III, 4,24-37.
- Shirane, T. (1984) Regulation of gonadal differentiation in frogs derived from UV-irradiated eggs. Zool.

- Sci. 1, 281-289.
- Shirane, T. (1986) A new early morphological indication of sex differentiation in anuran, *Rana japonica* and *R. nigromaculata*. J. Exp. Zool. 240, 113-118.
- Shirane, T. (1987) Role of peanut-lectin-affinity molecules (PLAM) on the primordial germ cells in the initial determination of sex in anura. J. Exp. Zool. 243, 495-502.
- Taylor, A. C. & Kollros, J. J. (1946) Stages in normal development of *Rana pipiens* larvae. Anat. Rec. 94, 7-24.
- Vannini, E., Stagni, A. & Zaccanti, F. (1975) Autoradiographic study on the mechanisms of testosterone-induced sex-reversal in *Rana* tadpoles. In Intersexuality in the Animal Kingdom (ed. R. Reinboth), pp. 318-331. Berlin-Heidelberg-New York: Springer-Verlag.
- Witschi, E. (1957) The inductor theory of sex differentiation. J. Fac. Sci. Hokkaido Univ. ser. VI 13, 428-439.
- Witschi, E. (1967) Biochemistry of sex differentiation in vertebrate embryos. In Biochemistry in Animal Development, vol. II (ed. R. Weber) pp. 193-225. New York: Academic Press.