

## Mass Mortality of Cultured Sevenband Grouper, *Epinephelus septemfasciatus*, Associated with Viral Nervous Necrosis

Y. Fukuda\*<sup>1</sup>, H. D. Nguyen\*<sup>2</sup>, M. Furuhashi\*<sup>2</sup> and T. Nakai\*<sup>2</sup>

\*<sup>1</sup>Oita Institute of Marine and Fisheries Science, Kamiura,  
Oita 879-26, Japan

\*<sup>2</sup>Faculty of Applied Biological Science, Hiroshima University,  
Higashihiroshima 739, Japan

(Received March 25, 1996)

Mass mortalities of sevenband grouper *Epinephelus septemfasciatus* reared in Oita Prefecture were investigated. The outbreaks of the disease occurred in summer seasons (July to October; water temperature 25–28°C) of 1993 and 1994. Affected fish ranging 170 to 1,850 g in body weight were characterized by upside down swimming and inflation of swimbladder. Histopathologically, necrosis and vacuolation in the central nervous tissues and retina were observed. Although bacteria or parasites associated with the disease were not detected from affected fish and no CPE was observed on RTG-2, BF-2, and EPC cell lines, spherical virus particles, 28 nm in diameter, were found abundantly in the cytoplasm of affected nerve cells of most of the affected fish. The virus was identified as a fish nodavirus (nervous necrosis virus), based on the results of fluorescent antibody technique test with anti-SJNNV rabbit serum and polymerase chain reaction test with primers for amplification of SJNNV coat protein gene. These results suggest that the mortalities of sevenband grouper were at least partly due to viral nervous necrosis (VNN). This is the first report describing VNN of sevenband grouper and the first case of VNN in the adult fish.

**Key words:** sevenband grouper, *Epinephelus septemfasciatus*, viral nervous necrosis, VNN, nodavirus

Marine aquaculture industry has highly developed in Japan, and various marine fish and shellfish species are marked as new target species for aquaculture. However, mass mortalities due to infectious diseases have often occurred in these newly introduced species as well as in fish with long-termed culture history such as yellowtail *Seriola quinqueradiata*, red sea bream *Pagrus major*, and Japanese flounder *Paralichthys olivaceus* (Ishioka, 1992; Muroga, 1995). Particularly, newly emerging viral diseases such as viral nervous necrosis (VNN) (Nakai *et al.*, 1995) and red seabream iridovirus (RSIV) infection (Inouye *et al.*, 1992), both have already spread to a wide variety of cultured marine fish species, are causing very serious damages in the industry.

Sevenband grouper *Epinephelus septemfasciatus* has been cultured at several private fish farms in Oita Prefecture for these 10 years. However, during summer season mass mortalities due to an unknown cause have often been encountered in the cultured population of young and adult sevenband grouper

since 1989. The affected fish float upside down around the surface of water and the mortality often reaches more than 50%. In this study, diseased sevenband grouper collected during mass mortalities in Oita Prefecture in 1993 and 1994 were investigated epizootiologically and pathologically.

### Materials and Methods

#### *Fish examined*

Four disease cases of sevenband grouper occurred in Oita Prefecture in 1993 (farm K) and 1994 (farm B, L, M) were examined. Fish floating upside down were sampled during each case and a total of 19 fish (170–1,850 g in body weight) was examined in this study.

#### *Parasitological and bacteriological examinations*

The presence of parasites and bacteria on the gills, body surface, and brain was examined under a microscope. For bacterial isolation, the kidney and

brain were inoculated on brain heart infusion agar (Nissui, 1.5% NaCl) and incubated at 25°C for 7 days.

#### *Histological examination*

The organs (gills, spleen, liver, kidney, brain, and eye) of fish were fixed in 10% buffered formalin. The samples were embedded in paraffin wax and the sections were stained with haematoxylin-eosin (H&E). For transmission electron microscopy, samples were re-fixed in a 2.5% glutaraldehyde-2% paraformaldehyde mixture (pH 7.4), post-fixed with 1% osmium tetroxide, and embedded in Quetol 812. Thin sections were stained with 1% uranyl acetate and 1% lead citrate, and then examined with a Hitachi H-600A electron microscope.

#### *Virological examination*

Freshly prepared or frozen (-80°C) kidney samples were homogenized with 9-volumes of Hanks' balanced salt solution (Gibco) and centrifuged at 1,000×g for 15 min. The supernatant was filtered with a 0.45 µm-membrane filter. The filtrate was inoculated in 3 fish cell lines (RTG-2, BF-2, and EPC) and incubated at 25°C for 2 weeks.

For detection of striped jack nervous necrosis virus (SJNNV) by an indirect fluorescent antibody technique (FAT), paraffin sections of the brain and eyes were processed according to the method described previously (Nguyen *et al.*, 1996). The sections were stained with an anti-SJNNV rabbit serum and FITC (fluorescein isothiocyanate)-conjugated swine Ig to rabbit Ig (Dako). For the PCR (polymerase chain reaction)-based detection of SJNNV, the same organs were homogenized with DEPC (diethyl pyrocarbonate)-treated distilled water containing Tween 20 (0.5%) and proteinase K (0.5 mg/ml) and incubated at 37°C for 30 min, and the total nucleic acids were extracted with phenol saturated with TE buffer (10 mM Tris-HCl pH 8.0, 1 mM EDTA) and chloroform-isoamyl alcohol (24:1). PCR amplification was carried out using a primer set designed for T4 region (about 430 bp) in the open reading frame of SJNNV coat protein gene (RNA2), according to the method described by Nishizawa *et al.* (1994).

## Results

#### *Epizootiology and clinical pathology*

In 4 disease cases examined, the mortalities occurred in the middle of July to October and the peak of the mortality was recorded in September. Water temperature during mass mortalities ranged from 25 to 28°C. Any clinical signs such as anorexia and blackening in body color were not observed before the mortality. When water temperature increased to 24 to 25°C in July, a few fish with upside down swimming behavior appeared and 2 to 3 weeks later the number of fish with such abnormal swimming increased abruptly. After the continuous mortality for 3 to 4 weeks in summer season, the mortality ceased in October when water temperature decreased below 25°C. In Fig. 1, as an example, daily and cumulative mortalities in a case of the farm B in 1994 were shown. The mortality initiated in the early August and ceased in the late September. The cumulative mortalities reached 57.8% and the water temperature during mass mortality ranged from 24.8 to 28.0°C.

The diseased fish swam erratically and floated upside down. Although lack of body mucus, hemorrhage in the snout, exophthalmus, or hemorrhage in the liver were observed in some fish, most of the fish did not show any apparent disease signs. All of the fish examined exhibited inflation of swimbladder (Fig. 2).

#### *Parasitological and bacteriological examinations*

Although *Trichodina*-like ciliates and epitheliosytis-like organisms were observed on or in the gills of a few fish examined, other parasites were not found on the gills, body surface, and brain. Filamentous bacteria such as *Flexibacter maritimus* were not observed on the gills and body surface and any fish-pathogenic or dominant bacteria were not isolated from the kidney and brain of the diseased fish.

#### *Histopathological and virological examinations*

Table 1 shows the results of histopathological examinations by light and electron microscopy and specific detection of nervous necrosis virus by FAT and PCR methods. The results of these examinations were positive in 15 out of 19 fish examined but the remaining 4 fish showed negative results in the all tests. No histopathological changes were observed

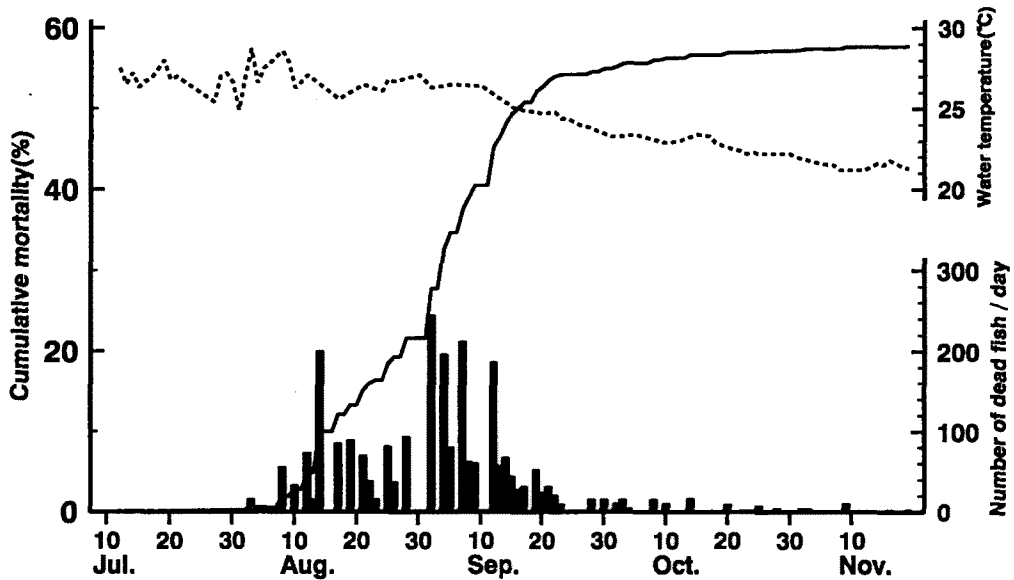


Fig. 1. Daily and cumulative mortalities of sevenband grouper in B farm in 1994.  
 ■ daily mortality, — cumulative mortality, -- water temperature

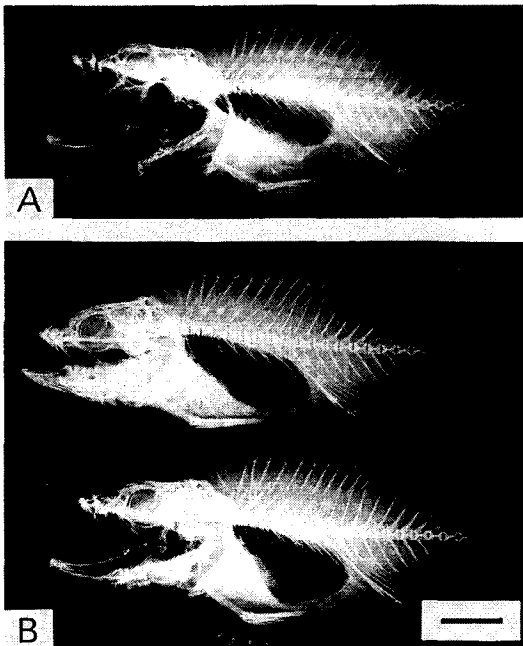


Fig. 2. Diseased sevenband groupers showing enlarged swimbladder. A: normal, B: diseased. Bar=20 mm.

in the gills and internal organs (spleen, liver and kidney), but the vacuolation and degeneration of nerve cells were observed in the brain and retina.

However, these vacuolation was not so intensive and dead nerve cells seemed to be replaced with astrocytes forming an astrocytic scar (Fig. 3). No cytopathic effect was observed for 2 weeks in the fish cell lines inoculated with the filtrate of the kidney. Numerous round-shaped, unenveloped virus particles, about 28 nm in diameter, were observed in the cytoplasm of the degenerated nerve cells. The virus particles were distributed without forming crystal-line-array arrangement but forming bounds of a membraneous structure (Fig. 4). In FAT test using anti-SJNNV serum, positive reaction was observed in the nerve cells of retinal and brain tissues but the number of nerve cells showing positive-fluorescence was relatively few. About 430 bp products were detected from the eyes and brain by PCR using primers for amplification of SJNNV RNA2 gene.

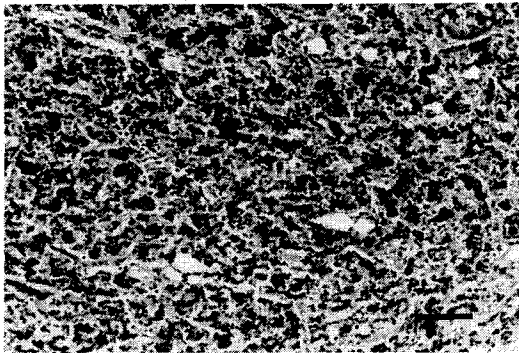
#### Discussion

Three species of groupers, redspotted grouper (*E. akaara*), kelp grouper (*E. moara*) and sevenband grouper, have been cultured in Japan. The seed production techniques for the former two species have been developed, while seed of the last one still depends on the natural fish and a large amount of seed fish has been imported from foreign countries. Recently, a viral infection, viral nervous necrosis

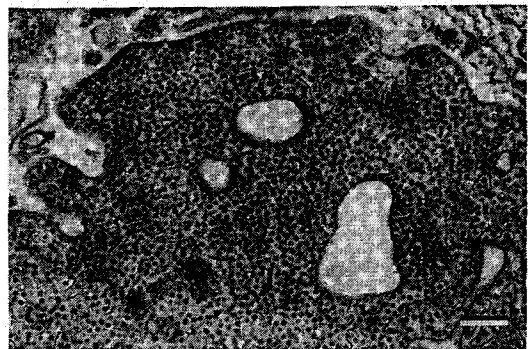
**Table 1.** Histopathological changes observed by light microscopy (LM) and the result of the detection of nervous necrosis virus by fluorescent antibody technique (FAT), polymerase chain reaction (PCR), and electron microscopy (TEM) in diseased sevenband grouper

Farm (year)	Body weight (g)	Results*			
		LM	FAT	PCR	TEM
K (1993)	240	nd	nd	+	nd
	220	+	+	+	+
	230	nd	nd	+	nd
	220	+	+	+	+
	170	nd	nd	+	nd
	230	nd	nd	+	nd
B (1994)	700	+	+	+	+
	430	+	+	+	+
	620	-	-	-	nd
	520	+	+	+	nd
	500	-	-	-	nd
	690	-	-	-	nd
L (1994)	510	+	+	+	nd
	450	+	+	+	nd
	610	-	-	-	nd
	330	+	+	+	nd
	570	+	+	+	nd
M (1994)	370	+	+	+	+
	1,850	+	+	+	+

\* Results are given positive or negative for necrosis and vacuolation (LM), specific fluorescence (FAT), 430 bp-products (PCR), and the virion (28 nm in diameter) (TEM) in the retina and brain, nd: not done.



**Fig. 3.** Light micrograph showing necrosis and vacuolation in the brain of a diseased sevenband grouper. Bar=50  $\mu$ m.



**Fig. 4.** Electron micrograph showing virus particles in the nerve cell of a diseased sevenband grouper. Bar=200 nm.

(VNN) caused by a *nodavirus* (*Nodaviridae*), was reported in larvae and juveniles of redspotted grouper (*Mori et al.*, 1991) and kelp grouper (*Nakai et al.*, 1994) as well as in other marine fishes. The VNN disease was characterized by abnormal swimming behavior such as a whirling or corkscrew motion, heavy vacuolation of the central nervous tissues, and

spherical virus particles (25–30 nm in diameter) observed in the cytoplasm of affected nerve cells (*Nakai et al.*, 1995).

In the present study, diseased sevenband grouper collected during mass mortalities in Oita Prefecture were investigated. The affected fish were characterized by upside down swimming behavior, swimblad-

der inflation and degeneration of nervous tissues (necrosis and vacuolation). No parasites or bacteria associated with the disease were found, but small round-shaped virus particles were observed in the cytoplasm of affected nerve cells in the central nervous tissues and retina. The virus was identified as a nodavirus (SJNNV; Mori *et al.*, 1992) by FAT and PCR tests, though some of fish examined resulted in negative in these tests. Transmission experiments to fulfill the Koch's postulates were not carried out in the present study due to the lack of healthy sevenband grouper available for the experiment. However, a preliminary transmission experiment using juvenile redspotted grouper demonstrated that the disease was produced by intramuscular injection with the filtrate of homogenized brain of diseased sevenband grouper. Affected redspotted grouper also showed upside down behavior (data not shown). These results suggest that the present mass mortalities of sevenband grouper were associated with VNN.

Sohn *et al.* (1991) found hexagonal or polygonal virus particles, 45–60 nm in diameter, in the liver cells of diseased sevenband grouper, which had clinical pathology similar to the present case. They confirmed by intramuscular injection that the liver filtrate from diseased fish produced mortalities in healthy sevenband grouper. The differences in the size and localization of the virus and some clinical signs seem to indicate that the disease reported by Sohn *et al.* (1991) was not VNN.

As mentioned above, VNN disease has been reported in many marine fish species in Japan and other countries, however, the reported disease outbreaks have been restricted to their larval and juvenile stages so far. The causative agent of VNN, named as SJNNV, was detected from the gonads of adult striped jack *Pseudocaranx dentex* but not from the central nervous systems (Arimoto *et al.*, 1992; Mushiake *et al.*, 1992), and the infected or carrier adult fish are apparently healthy without showing any clinical signs. It was also reported that juvenile striped jack were resistant to experimental infection with SJNNV (Arimoto *et al.*, 1993) and some of juvenile redspotted grouper experimentally infected with the virus recovered after showing diseased sign (Mori *et al.*, 1991). These results may suggest that 4 fish failed to detect the virus in the present case was in the convalescent stage. If sevenband grouper has also the age-dependence, there must have been a

predisposing factor(s) which enabled the virus to invade into the central nervous system. As a possible predisposing factor, we suspected a higher rearing water temperature in summer season. The effect of rearing water temperature on the defence mechanisms of sevenband grouper should be examined in further infection experiments.

#### Acknowledgement

We thank Dr. K. Muroga, Hiroshima University, for critical reviewing of the manuscript.

#### References

- Arimoto, M., K. Mushiake, Y. Mizuta, T. Nakai, K. Muroga and I. Furusawa (1992): Detection of striped jack nervous necrosis virus (SJNNV) by enzyme-linked immunosorbent assay (ELISA). *Fish Pathol.*, **27**, 191–195.
- Arimoto, M., K. Mori, T. Nakai, K. Muroga and I. Furusawa (1993): Pathogenicity of the causative agent of viral nervous necrosis disease in striped jack, *Pseudocaranx dentex* (Bloch & Schneider). *J. Fish Dis.*, **16**, 461–469.
- Inouye, K., K. Yamano, Y. Maeno, K. Nakajima, M. Matsuoka, Y. Wada and M. Sorimachi (1992): Iridovirus infection of cultured red sea bream, *Pagrus major*. *Fish Pathol.*, **27**, 19–27.
- Ishioka, H. (1992): Epidemiology of marine fish diseases in the warm waters along the Kuroshio Current. NOAA Technical Report NMFS, **111**, 69–83.
- Mori, K., T. Nakai, M. Nagahara, K. Muroga, T. Mekuchi and T. Kanno (1991): A viral disease in hatchery-reared larvae and juveniles of redspotted grouper. *Fish Pathol.*, **26**, 209–210.
- Mori, K., T. Nakai, K. Muroga, M. Arimoto, K. Mushiake and I. Furusawa (1992): Properties of a new virus belonging to Nodaviridae found in larval striped jack (*Pseudocaranx dentex*) with nervous necrosis. *Virology*, **187**, 368–371.
- Muroga, K. (1995): Viral and bacterial diseases in larval and juvenile marine fish and shellfish: a review. *Fish Pathol.*, **30**, 71–85.
- Mushiake, K., M. Arimoto, T. Furusawa, I. Furusawa, T. Nakai and K. Muroga (1992): Detection of antibodies against striped jack nervous necrosis virus (SJNNV) from brood stocks of striped jack. *Nippon Suisan Gakkaishi*, **58**, 2351–2356.
- Nakai, T., H. D. Nguyen, T. Nishizawa, K. Muroga, M. Arimoto and K. Ootsuki (1994): Occurrence of viral nervous necrosis in kelp grouper and tiger puffer. *Fish Pathol.*, **29**, 211–212.

- Nakai, T., K. Mori, T. Nishizawa and K. Muroga (1995): Viral nervous necrosis of larval and juvenile marine fish. Proceedings of the International Symposium on Biotechnology Applications in Aquaculture, Asian Fisheries Society Special Publication No. 10, 147-152.
- Nguyen, H. D., T. Nakai and K. Muroga (1996): Progression of striped jack nervous necrosis virus (SJNNV) infection in naturally and experimentally infected striped jack *Pseudocaranx dentex* larvae. *Dis. Aquat. Org.*, **24**, 99-105.
- Nishizawa, T., K. Mori, T. Nakai, I. Furusawa and K. Muroga (1994): Polymerase chain reaction (PCR) amplification of RNA of striped jack nervous necrosis virus (SJNNV). *Dis. Aquat. Org.*, **18**, 103-107.
- Sohn, S.-G., M.-A. Park, S.-D. Lee and S.-K. Chun (1991): Studies on the mass mortality of the cultured grouper, *Epinephelus septemfasciatus*. *J. Fish Pathol.*, **4**, 87-94.