

## Diagnosis of Viral Epidermal Hyperplasia of Japanese Flounder Larvae by Fluorescent Antibody Technique

Toshihiro Nakai,\*<sup>1</sup> Koh-ichiro Mori,\*<sup>1</sup> Kiyokuni Muroga,\*<sup>1</sup>  
and Takayuki Mekuchi\*<sup>2</sup>

(Received March 5, 1991)

The first occurrence of "viral epidermal hyperplasia" of Japanese flounder larvae was recorded in Hiroshima Prefecture in 1985, and since then the same disease has been prevailing in hatchery-reared flounder in various districts of Japan. In the present study, we applied fluorescent antibody technique (FAT) to the disease as a diagnostic procedure. Electron microscopy and transmission experiments revealed that 4 out of 5 cases examined were due to viral epidermal hyperplasia. FAT test, using a rabbit antiserum against virus particles collected from epithelial cells of affected flounder larvae, exhibited a positive reaction on only the epidermis of the fish in the above 4 epizootics. Thus, the FAT method proved to be useful for rapid diagnosis of the present disease.

A new disease characterized by fin opacity occurred with high mortality in hatchery-reared Japanese flounder *Paralichthys olivaceus* larvae in Hiroshima and Mie Prefectures from 1985 to 1987. Although attempts to culture the causative virus in fish cell lines were not successful, the disease proved to be a herpesvirus infection based on the results of electron microscopy and transmission experiments.<sup>1,2)</sup> Two different names, "epidermal necrosis"<sup>2)</sup> and "viral epidermal hyperplasia"<sup>3)</sup> have been proposed for this disease. Thereafter, the same disease, at least symptomatically indistinguishable from the above disease, has been spreading in some hatcheries in various districts of Japan, however, a difficulty has been encountered in establishing precise diagnosis of the disease due to the impracticability of virus isolation and the lack of specific method.

In general, serological procedures, especially immunofluorescence and enzyme immunoassay, are known to be very useful for the rapid and specific detection of fish pathogens.<sup>4)</sup> However, it has not been possible to obtain the antibody against the present viral pathogen because of unsuccessful propagation of the virus in cell lines.<sup>1)</sup> In this study, we developed a specific diagnostic method for this disease by indirect fluorescent antibody technique (FAT) using a rabbit antiserum against the virus antigen(s) collected from epi-

dermal cells of affected flounder larvae.

### Materials and Methods

Naturally affected flounder larvae with opaque fins, 10-25 day-old and 6-8 mm in total length, were taken from 5 hatcheries (commercial and public) in Hiroshima, Shimane, Ehime, Kumamoto, and Niigata Prefectures in 1988 and 1989. All cases resulted in mass mortalities, where fish were cultured at a density of approximately 10,000-15,000 fish/m<sup>3</sup> at 18-19°C except for the Niigata's case at 15°C. Some of the whole samples obtained from each hatchery were fixed for light and electron microscopic examinations, and the rest were frozen at -80°C as a source of the infectious agent for experimental infections. In every cases, 17-25, 2, and 2 fish were examined for clinical pathology, histopathology, and electron microscopy, respectively. Healthy flounder larvae, 9-10 mm in total length and 18-25 day-old, reared in Hiroshima Prefectural Fisheries Experiment Station were employed as normal fish for histological examinations and experimental infections.

Experimental infections were carried out by the previously described method.<sup>1)</sup> A batch of diseased fish weighing 1 g as a whole was homogenized with 9 ml of Hanks' balanced salt

\*<sup>1</sup> Faculty of Applied Biological Science, Hiroshima University, Higashi-Hiroshima 724, Japan (中井敏博, 森 広一郎, 室賀清邦: 広島大学生物生産学部).

\*<sup>2</sup> Hiroshima Prefectural Fisheries Experiment Station, Ondo, Hiroshima 737-12, Japan (馬久地隆幸: 広島県水産試験場).

solution (HBSS), centrifuged at  $1,600\times g$ , and filtered through a  $0.45\ \mu\text{m}$ -membrane filter. Healthy larvae consisting of 50 individuals were exposed for 30 min to the filtrate at a 1,000-fold dilution with seawater, or to HBSS (control). After virus exposure, fish were kept in 20 l tanks at  $20^\circ\text{C}$  for 10 days. For light microscopy, naturally and experimentally affected larvae were fixed in Bouin's solution, embedded in paraffin wax, cut at  $3\text{--}5\ \mu\text{m}$ , and stained with Hematoxylin-Eosin (H & E). For transmission electron microscopy (TEM), fish were fixed in a 2.5% glutaraldehyde-2% paraformaldehyde mixture in 10 mM phosphate buffer (pH 7.0), post-fixed in 1% osmium tetroxide, and embedded in Quetol 812. Thin sections were stained with 1% uranyl acetate and 1% lead citrate, and examined with a JEOL JEM-1200EX at 80 kV.

In order to collect the affected epidermal cells for virus isolation, diseased flounder larvae (total weight 60 g) obtained from another hatchery in Hiroshima Prefecture were stirred in  $\text{Ca}^{++}$ - and  $\text{Mg}^{++}$ -free Dulbecco's phosphate buffered saline (CMF-PBS) for 30 min at room temperature. Epidermal cells were detached easily from the skin and fins by this procedure and the cell suspension through a  $75\ \mu\text{m}$ -stainless mesh was centrifuged at  $200\times g$  for 10 min ( $4^\circ\text{C}$ ). Cells were resuspended in 10 mM Tris-HCl buffer (pH 7.8), sonicated at 20 W for 2 min, and then centrifuged at  $10,000\times g$  for 60 min ( $4^\circ\text{C}$ ). The supernatant was centrifuged through a discontinuous gradient of 30% and 60% sucrose at  $71,000\times g$  for 3 h ( $4^\circ\text{C}$ ) and a band formed on 60% sucrose layer was collected. After confirming by TEM observation with negatively stained specimen that this band contained virus particles, it was dialyzed against Tris-HCl buffer overnight. The virus suspension was injected several times in the hypodermis of a rabbit with Freund's complete adjuvant and in the ear vein

without adjuvant. The blood was taken 42 days after the first injection. The collected serum was inactivated and stored at  $-80^\circ\text{C}$ .

Prior to the FAT test, the antiserum was absorbed with epithelial cells collected from fins of a healthy adult flounder (720 g body weight). A 100-fold diluted antiserum was mixed with an equal volume of the packed cell at room temperature for 1 h and centrifuged at 3,000 rpm for 5 min. This absorption was repeated 3 times.

Diseased fish samples fixed in 10% buffered formalin (stored at  $4^\circ\text{C}$ ) were immersed in 5% sucrose added 0.1 M PBS (pH 7.2) overnight. After successive immersing in 10%, 30%, and 40% sucrose added PBS for 1–2 h, samples were embedded in O. C. T. compound (Miles Inc.), cut at  $7.5\ \mu\text{m}$  by a cryostat apparatus, and washed with cold PBS. Samples were incubated with the absorbed rabbit antiserum at  $37^\circ\text{C}$  for 30 min, washed with PBS, and then reacted with FITC labelled goat anti-rabbit IgG (Kirkegaard & Laboratories Inc.) at  $37^\circ\text{C}$  for 30 min, washed with PBS, and examined by fluorescence microscopy (Nikon EFD). Controls of healthy flounder larvae stained with the same antiserum and diseased fish with pre-immune rabbit serum were also employed.

### Results and Discussion

The results of experimental infection, histopathological, electron microscopic examinations, and FAT tests were summarized in Table 1. Macroscopically, affected fish from 4 outbreaks in Hiroshima, Shimane, Ehime, and Kumamoto exhibited opaque lesions not only on the fins but also over the entire skin, while such a lesion was confined to their fins, especially the caudal fin, in Niigata's samples. As mentioned before, the water temperature of the hatchery in Niigata was significantly lower than the others.

**Table 1.** Diagnosis of 5 disease outbreaks by histopathological and electron microscopic examinations, experimental infection, and fluorescent antibody technique (FAT)

Outbreak (Prefecture)	Epidermal hyperplasia* <sup>1</sup>	Virus particle* <sup>2</sup>	Filtrable agent* <sup>3</sup>	FAT
Hiroshima	+	+	+	+
Shimane	+	+	+	+
Ehime	+	+	+	+
Kumamoto	+	+	+	+
Niigata	+	—	—	—

\*<sup>1</sup> histopathological examination.

\*<sup>2</sup> electron microscopic observation.

\*<sup>3</sup> experimental infection.

**Table 2.** Experimental infection in flounder larvae with filtered homogenates of diseased fish from 5 different cases

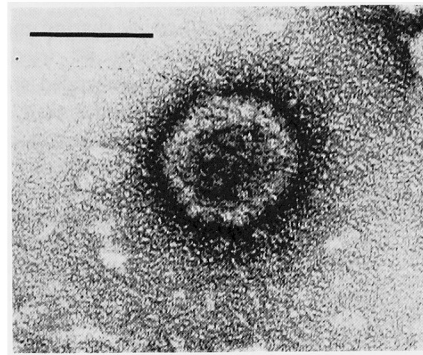
Filtrate source	Infected group		Control group	
	mortality %	clinical sign %* <sup>1</sup>	mortality %	clinical sign %
Hiroshima	70 (35/50)* <sup>2</sup>	100 (15/15)	8 (4/50)	0 (0/46)
Shimane	76 (38/50)	100 (12/12)	8 (4/50)	0 (0/46)
Ehime	82 (41/50)	100 (9/9)	2 (1/50)	0 (0/49)
Kumamoto	90 (45/50)	100 (5/5)	0 (0/50)	0 (0/50)
Niigata	14 (7/50)	0 (0/43)	8 (4/50)	0 (0/46)

\*<sup>1</sup> manifestation of clinical sign (epidermal hyperplasia) in survived fish.

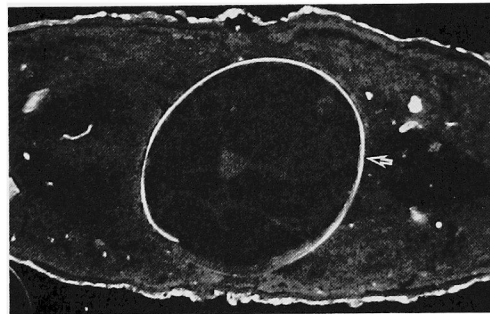
\*<sup>2</sup> number of fish dead/tested.

As shown in Table 2, the first 4 samples, viz. samples from Hiroshima, Shimane, Ehime, and Kumamoto Prefectures, gave the same result in experimental infection. In these groups, mortalities reached 70% or higher within 10 days after the exposure to the filtrate, and all survivors had opaque fins and skin. Histopathologically, both naturally and experimentally infected larvae showed extensive epidermal hyperplastic growth and vacuole degeneration in the cytoplasm, but there were no remarkable lesions in the gills and internal organs. These histopathological changes are consistent with those described previously in the first case of viral epidermal hyperplasia.<sup>1)</sup> In control groups receiving HBSS, mortalities were 8% or less and no epidermal hyperplasia was observed. Herpesvirus-like particles were found in the nucleus and cytoplasm of the epidermal cells in both naturally and experimentally affected larvae, the average diameter of the particles ranging 100–107 nm (capsid) and 158–182 nm (enveloped virion). Although these figures of the particle size are relatively smaller than those observed in the previous study,<sup>1)</sup> these 4 outbreaks were diagnosed as viral epidermal hyperplasia. On the other hand, there was no evidence of any viral infection for Niigata's outbreak, and the cause of the mortality remains unknown.

The major purpose of this study was to investigate whether FAT procedure is applicable to the diagnosis of the present viral disease, whose causative agent has not been isolated in cell lines. The virus particles were able to be collected from epidermal cells of affected flounder larvae by sucrose gradient centrifugation. Capsomer number of the particles was calculated as 162 from its negatively stained figure (Fig. 1). A rabbit antiserum produced against the virus suspension had a problem for direct application to FAT test because of strong false staining in



**Fig. 1.** Electron micrograph of a negatively stained virus particle. bar = 100 nm.



**Fig. 2.** Positive fluorescence at the epidermal layer of the skin of a diseased flounder by FAT. Abdominal wall (arrow) is also stained brightly but easily differentiated from specific reaction under a fluorescence microscopy.

uninfected control specimens. However, this was solved by thorough absorption of antiserum with epithelial cells of normal flounder. FAT reaction with the absorbed antiserum was positive only in the superficial epidermal layer of the skin of diseased fish (Fig. 2). It is probably due to a large quantity of the virus particles present

in these superficial cells. When FAT test was applied to the diagnosis of 5 cases in flounder larvae, the result completely coincided with those derived from electron microscopy and experimental infection in that 4 out of 5 cases were due to viral epidermal hyperplasia. Although antigenic cross reactions should be examined with other herpesviruses, this FAT procedure seems to be applicable for rapid diagnosis of the present viral disease, and consequently it became apparent that a series of outbreaks of viral epidermal hyperplasia in recent 5 years was caused by a single serotype of the pathogen (Flounder Herpesvirus: FHV) or the pathogens sharing major common antigen(s). In addition, we tried to apply this FAT test to paraffin embedded specimens to make this method more widespread, but resulted in failure, probably due to heat-lability of the virus antigens.

#### Acknowledgements

We thank the staff of the Prefectural Fish Farming Centers of Shimane, Kumamoto, and Niigata, and Japan Sea-Farming Association (Hakata Island Station) for supplying fish samples, and also Dr H. Matsuda, Hiroshima University, for his valuable technical advice on this study.

#### References

- 1) Y. Iida, K. Masumura, T. Nakai, M. Sorimachi, and H. Matsuda: *J. Aquat. Anim. Health*, **1**, 7-12 (1989).
- 2) T. Miyazaki, K. Fujiwara, J. Kobara, N. Matsumoto, M. Abe, and T. Nagano: *J. Aquat. Anim. Health*, **1**, 85-93 (1989).
- 3) Y. Iida, T. Nakai, M. Sorimachi, and K. Masumura: *Dis. Aquat. Org.*, **10**, 59-63 (1991).
- 4) W. B. Schill, G. L. Bullock, and D. P. Anderson: in "Methods for the Microbiological Examination of Fish and Shellfish" (ed. by Austin and Austin), Ellis Horwood Limited, Chichester, 1989, pp. 98-140.