

**Early clinical outcomes of 3D-conformal radiotherapy using accelerated hyperfractionation without intracavitary brachytherapy for cervical cancer**

K. Matsuura, M.D., Ph.D.,<sup>a,b</sup> H. Tanimoto, M.D., Ph.D.,<sup>c</sup> K. Fujita, M.D., Ph.D.,<sup>b</sup> Y. Hashimoto, M.D.,<sup>a</sup> Y. Murakami, M.D.,<sup>a</sup> M. Kenjo, M.D.,<sup>a</sup> Y. Kaneyasu, M.D., Ph.D.,<sup>a</sup> K. Wadasaki, M.D., Ph.D.,<sup>a</sup> and K. Ito., M.D., Ph.D.<sup>a</sup>

<sup>a</sup>Department of Radiology, Hiroshima University, Hiroshima, Japan

<sup>b</sup>Department of Radiology, Higashihiroshima Medical Center, Higashihiroshima, Japan

<sup>c</sup>Department of Obstetrics and Gynecology, Hiroshima City Hospital, Hiroshima, Japan

## ABSTRACT

**Purpose/Objective:** To evaluate the outcome of cervical cancer patients unable to undergo conventional intracavitary brachytherapy (ICBT) treated with 3D-conformal radiotherapy (3DCRT) alone using accelerated hyperfractionation (AHF).

**Methods and Materials:** We reviewed the records of 7 patients who had received definitive radiotherapy with 3DCRT alone using AHF for cervical cancer between 2002 and 2005. FIGO stage was IB (1), IIB (2), IIIA (1), IIIB (2), and IVA (1). The reason we did not perform ICBT was due to patient refusal. In 1 patient with stage IB, a total dose of 65.4 Gy was delivered by local irradiation (LI) only. In 1 patient with stage IIIA, a total dose of 60 Gy was delivered by LI only. In 5 patients with Stage IIB-IV, a median total dose of 70.8 Gy was delivered by combination of whole pelvic irradiation (median dose of 45 Gy) with LI. Median overall treatment time was 42 days.

**Results:** Median follow-up for survival patients was 17 months. Out of 7 patients, 6 patients had CR and 1 patient had PR. The response rate was 100%. The 2-year local control rate was 85.7%. Of these patients, 5 are alive without disease and 1 is alive with lung metastasis.

**Conclusions:** Our outcomes suggest that 3DCRT using AHF may be a promising as a definitive treatment for cervical cancer when ICBT is not able to be performed.

Keywords: cervical cancer, external radiotherapy, 3D-conformal radiotherapy

## INTRODUCTION

Although the standard radical treatment for cervical cancer is a combination of external radiotherapy (ERT) and intracavitary brachytherapy (ICBT), we sometimes need to treat with ERT alone in cases where ICBT is not feasible for several reasons. When 2D treatment planning with X-ray simulator was mainstream, for definitive treatment with ERT alone, anterior-posterior parallel opposing fields or 4 box fields were mostly used. However, using this irradiation technique brought with it the problem that most portions of the rectum and bladder were irradiated with an equal dose of the target volume. Therefore, we could not irradiate the target with a high dose with ERT alone and were unable to get treatment results that matched results from a combination of ERT and ICBT.

Recently, 3D-conformal radiotherapy (3DCRT) was enabled with progress and spread of radiotherapy treatment planning device. By using 3DCRT, it may be possible to improve treatment outcomes with dose reduction of normal surrounding tissue and increase of target dose. However, it has been reported that prolongation of overall treatment time in patients with cervical cancer deteriorates local control and that

shortening of overall treatment time can improve local control. By using accelerated hyperfractionation (AHF), it may be possible to improve treatment outcomes by shortening overall treatment time. In this report, early clinical results of 3DCRT alone using AHF in patients with cervical cancer were evaluated.

### **METHODS AND MATERIALS**

Between March 2002 and January 2005, 7 patients with cervical cancer were treated with 3DCRT alone using AHF. The median age was 81 years, ranging from 73 to 99 years. Before starting of treatment, we explained to all 7 patients that standard definitive radiotherapy method for cervical cancer was a combination of ERT and ICBT, but all of them refused to receive ICBT. Therefore they chose to receive treatment by ERT alone. Histologic evaluation revealed all cases to be squamous cell carcinoma. For staging purposes, a radiation oncologist and a gynecologic oncologist performed a physical examination. Staging was performed according to the International Federation of Gynecology and Obstetrics (FIGO) classification. One patient had stage IB, 2 had stage IIB, 1 had stage IIIA, 2 had stage IIIB and 1 had stage IVA. None of the patients underwent chemotherapy. All patients received CT (computed tomography) and MRI (magnetic resonance imaging) before treatment as pretreatment procedures. Patients and

tumor characteristics are shown in table 1.

#### *Treatment planning and treatment*

For 3DCRT planning, Pinnacle<sup>3</sup> (ADAC, Milpitas, CA, USA) was used. For treatment, Mevatoron M2 linear accelerator (SIEMENS, Concord, CA, USA) with 6-MV energy was used. For 5 patients with Stage IIB-IV, a median total dose of 70.8 Gy (range, 66-73) was delivered by combination of whole pelvic irradiation (WPI) (median dose of 45 Gy) at 1.8 Gy per fraction, following local irradiation (LI) at 1.2-1.6 Gy per fraction using concomitant boost AHF, at least 6 hours after WPI. 3DCRT treatment plans for an example patient are shown in Fig. 1 and fractionation schedule for an example patient is shown in Fig. 2. For 1 patient with stage IB, a total dose of 65.4 Gy/52 fractions was delivered by LI only using escalating dose AHF, twice a day with a 6 hour interval. For the one patient with stage IIIA, a total dose of 60 Gy/40 fractions was delivered by LI only using AHF due to high age, twice a day with a 6 hour interval. Median overall treatment time was 42 days (range, 28-46). A four-field technique was used to irradiate the whole pelvis sparing the small bowel. For LI, multiple fields or dynamic conformal arc fields were used to reduce the total dose to the surrounding tissue, especially the rectum and bladder.

The CTV (clinical target volume) of WPI included the entire uterus, at least the

upper one third of the vagina, the parametrial tissue, and regional nodes (common and external iliac, hypogastric, obturator, and presacral nodes). The CTV of WPI was expanded uniformly by 1 cm in all directions to produce planning target volume (PTV). The CTV of LI included cervical tumor and parametrium invasion area. The PTV of LI was defined on each CT slice by drawing 0.5-1.0 cm margin around the CTV extending from 1.0 cm cephalad to the upper end of the CTV to caudal to the lower end of the CTV.

#### *Follow-up*

Follow-up examinations with physical examinations, cytology and CT scans were performed in all patients. The first examination took place 4-6 weeks after treatment. Subsequently, the patients were seen every 1-2 months.

#### *Statistics*

Statistical evaluation of local control rate and survival was performed using Kaplan-Meier methods, with the day of treatment as the starting point.

## **RESULTS**

Clinical outcomes are shown in table 2.

#### *Clinical response*

Of the 7 patients, complete response (CR) of the tumor was achieved in 6 patients (85.7%), and 1 patient had partial response (PR) (14.3%). Therefore, the response rate (CR+PR) was 100%.

#### *Local control and survival*

Median follow-up for survivors was 17 months (range, 15-37). Of 6 CR patients, all patients were locally controlled during the follow-up period and the 2-year local control rate was 85.7%.

Five patients with CR are alive without disease. In 1 patient with CR, lung metastasis was diagnosed at 18 months after radiotherapy. She is alive with disease. In 1 patient with PR, pelvic abscess was noted after 2 months and she died of severe infection caused by abscess at 6 months. The 2-year actuarial overall survival was 85.7%.

#### *Adverse effects*

All patients tolerated treatment very well, no severe adverse effects (CTCAE 3.0 Grade 3 or larger) were encountered. However, acute toxicity of grade 1 diarrhea was seen in 4 patients and acute toxicity of grade 1 and grade 2 urinary frequency were seen in 4 patients and in 1 patient respectively. Late toxicity of grade 2 rectal hemorrhage was seen in 2 patients.

## DISCUSSION

A combination of ERT and ICBT is established as the standard radical treatment for cervical cancer, and particularly the role of ICBT is important and it is proved that the use of ICBT was highly significantly associated with decreased local failure [1-3]. However, in an actual clinical setting one sometimes may need to treat with ERT alone in cases where ICBT is not feasible for reasons of refusal, stump cancer, narrow vagina, or for any other reason. Today, some reports of treatment results with ERT alone for cervical cancer have been published [4-6], but the results were not satisfying. In cases of ERT alone, it is necessary to irradiate more than 70 Gy to get satisfactory local control [4]. However, late complications involving the rectum and bladder rapidly increase with irradiation of more than 60 Gy [7], and we cannot irradiate with a dose of more than 70 Gy safely. Therefore, it was thought that local control rate of ERT alone without ICBT for cervical cancer was low.

Progress in radiotherapy technology has been remarkable and we are now able to perform highly precise ERT using the 3D treatment planning systems. With 3D treatment planning, we can set the multiple adequate fields which agrees with the target volume shape, avoiding the surrounding normal tissue as far as possible. Therefore, with 3DCRT we can obtain a dose distribution which resembles that of ICBT and we are



expecting improvements in local control by concentration of dose to the target with reduction in the normal surrounding tissue dose. For cancer of the prostate which is located in the same position as the uterine cervix in the pelvis anatomically, 3DCRT has already been used for treatment and dosage of more than 70 Gy has been tried sparing the rectum and bladder with comparable treatment results of 3DCRT for prostate cancer with minimal complications having been reported [8-10]. These results suggest that it may be possible to obtain good results with 3DCRT alone for cervical cancer. Nowadays, intensity modulated radiotherapy (IMRT), whose conformality is better than 3DCRT, is clinically used, and it has been reported that it is able to further reduce surrounding normal tissue dose and to concentrate target dose by IMRT in comparison with 3DCRT [11, 12]. Some reports of IMRT for cervical cancer have been published, but there are no reports of definitive IMRT without ICBT. Now, IMRT for cervical cancer is mostly used for only WPI followed by ICBT [13-15], but we think that IMRT could be used for not only WPI but also LI instead of ICBT in case of ERT alone. In definitive treatment with ERT alone for cervical cancer, if IMRT is used for LI, it seems that we can obtain better local control with minimal rectal complication in comparison with 3DCRT.

It has been reported that prolongation of overall treatment time in patients with

cervical cancer deteriorates local control and survival [16-20]. This effect may be related to the accelerated repopulation of tumor cells during a course of fractionated radiotherapy [21, 22], and it has been reported that shortening of overall treatment time can improve local control. Additionally, Nishimura et al. reported that radiotherapy must be delivered in the range of 66 Gy to 70 Gy in 6 weeks to obtain optimal local control with minimum adverse effects [20]. In Japan, patients with cervical cancer treated by a combination of ERT and ICBT are generally irradiated in about 6.5-7 weeks [23]. In cases of ERT alone, if conventional fractionation (1.8-2.0 Gy/f) is used for irradiation, 7-8 weeks is needed to irradiate 70 Gy and it is thought that local control of ERT alone will be poorer than that of ERT and ICBT. We have therefore postulated using AHF to shorten overall treatment time. The rationale for AHF is that overall treatment time is shortened thereby decreasing the accelerated repopulation and AHF may result in better local control. Today, some reports of radiotherapy results with AHF for cervical cancer have been published [24, 25]. Kavanagh et al treated cervical cancer with concomitant boost accelerated superfractionated (CBASF) radiotherapy followed by ICBT and they concluded that CBASF radiotherapy produced a trend toward improved local control when compared with conventional fractionated radiotherapy [25]. However, late adverse effects are associated with AHF. Therefore, when we treat cervical cancer by

ERT alone with AHF, using 3DCRT may offer the best outcome in terms of local control with acceptable adverse effects.

Early clinical outcomes of patients with cervical cancer treated with 3DCRT using AHF were good. In conclusion, although more patients with longer follow-up periods are needed to evaluate the usefulness and safety of this radiotherapy method, our outcome suggests that 3DCRT alone using AHF is promising as a definitive treatment for cervical cancer, if ICBT is unable to be performed due to patient's refusal, stump cancer, narrow vagina, or any other reason.

#### **REFERENCES**

[1]Hanks JE, Herring DF, Kramer S. Patterns of care outcome studies: Results of the national practice in cancer of the cervix. *Cancer* 1983;51:959-967.

[2]Coia L, Won M, Lanciano R, et al. The Patterns of care outcome study for cancer of the uterine cervix: Results of the second national practice survey. *Cancer* 1990;66:2451-2456.

[3]Maebayashi K, Mitsuhashi N, Toita T, et al. The patterns of care study for carcinoma of the uterine cervix treated with radiotherapy and without surgery. *Gan No Rinsho* 2001;47:669-674. Japanese.

[4]Castro JR, Issa P, Fletcher GH. Carcinoma of the cervix treated by external

irradiation alone. *Radiology* 1970;95:163-166.

[5]Akine Y, Hashida I, Kajiura Y, et al. Carcinoma of the uterine cervix treated with external irradiation alone. *Int J Radiat Oncol Biol Phys* 1986;12:1611-1616.

[6]Montana GS, Fowler WC, Varia MA, et al. Carcinoma of the cervix, stage III. Results of radiation therapy. *Cancer* 1986;57:148-54.

[7]Hareyama M, Sakurai T, Nishio M, et al. Results and complications of cervix carcinoma treated by whole pelvis external irradiation alone. *Nippon Igaku Hoshasen Gakkai Zasshi* 1980;40:19-23. Japanese.

[8]Zelevsky MJ, Leibel SA, Gaudin PB, et al. Dose escalation with three-dimensional conformal radiation therapy affects the outcome in prostate cancer. *Int J Radiat Oncol Biol Phys* 1998;41:491-500.

[9]Perez CA, Michalski JM, Purdy JA, et al. Three-dimensional conformal therapy or standard irradiation in localized carcinoma of prostate: preliminary results of a nonrandomized comparison. *Int J Radiat Oncol Biol Phys* 2000;47:629-637.

[10]Zelevsky MJ, Cowen D, Fuks Z, et al. Long term tolerance of high dose three-dimensional conformal radiotherapy in patients with localized prostate carcinoma. *Cancer* 1999;85:2460-2468.

[11]Zelevsky MJ, Fuks Z, Happersett L, et al. Clinical experience with intensity

modulated radiation therapy (IMRT) in prostate cancer. *Radiat Oncol* 2000;55:241-249.

[12]Zelevsky MJ, Fuks Z, Hunt M, et al. High-dose intensity modulated radiation therapy for prostate cancer: early toxicity and biochemical outcome in 772 patients. *Int J Radiat Oncol Biol Phys* 2002;53:1111-1116.

[13]Lujan AE, Mundt AJ, V D, et al. Intensity-modulated radiotherapy as a means of reducing dose to bone marrow in gynecologic patients receiving whole pelvic radiotherapy. *Int J Radiat Oncol Biol Phys* 2003;57:516-521

[14]Mundt AJ, Lujan AE, Rotmensch J, et al, Intensity-modulated whole pelvic radiotherapy in women with gynecologic malignancies. *Int J Radiat Oncol Biol Phys* 2002;52:1330-1337.

[15]Roeske JC, Lujan A, Rotmensch J, et al. Intensity-modulated whole pelvic radiation therapy in patients with gynecologic malignancies. *Int J Radiat Oncol Biol Phys* 2002;48:1613-1621.

[16]Girinsky T, Rey A, Roche B, et al. Overall treatment time in advanced cervical carcinomas: a critical parameter in treatment outcome. *Int J Radiat Oncol Biol Phys* 1993;27:1051-6.

[17]Lanciano RM, Pajak TF, Martz K, et al. The influence of treatment time on outcome for squamous cell cancer of the uterine cervix treated with radiation: a

patterns-of-care study. *Int J Radiat Oncol Biol Phys* 1993;25:391-7.

[18]Sugawara T, Mizutani Y, Nakazawa M. The effect of treatment time on pelvic recurrence in patients with stage III-IV uterine cervix cancer. *J Jpn Soc Ther Radiol Oncol* 1993;5:117-123.

[19]Perez CA, Grigsby PW, Castro-Vita H, et al. Carcinoma of the uterine cervix. I. Impact of prolongation of overall treatment time and timing of brachytherapy on outcome of radiation therapy. *Int J Radiat Oncol Biol Phys* 1995;32:1275-88.

[20]Nishimura Y, Okajima K, Hiraoka M. Optimal overall treatment time in fractionated radiotherapy for head and neck cancers, esophageal cancer, and uterine cervical cancer. *J Jpn Soc Ther Radiol Oncol* 1996;8:303-315.

[21]Withers HR, Taylor JM, Maciejewski B. The hazard of accelerated tumor clonogen repopulation during radiotherapy. *Acta Oncol* 1988;27:131-46.

[22]Petereit DG, Sarkaria JN, Chappell R, et al. The adverse effect of treatment prolongation in cervical carcinoma. *Int J Radiat Oncol Biol Phys* 1995;32:1301-1307.

[23]Kaneyasu Y, Hirokawa Y, Kashimoto K, et al. National survey of high-dose rate brachytherapy for uterine cervical cancer. *J Jpn Soc Ther Radiol Oncol* 2004;16:237-248.

[24]Macleod C, Bernshaw D, Leung S, et al. Accelerated hyperfractionated

radiotherapy for locally advanced cervix cancer. *Int J Radiat Oncol Biol Phys* 1999;44:519-524.

[25]Kavanagh BD, Segreti EM, Koo D, et al. Long-term control and survival after concomitant boost accelerated radiotherapy for locally advanced cervix cancer. *Am J Clin Oncol* 2001;24:113-119.

### **Figure legends**

Figure 1: Axial CT image showing isodose areas for (a) WPI, (b) LI, (C) boost LI.

Cervical tumor on CT slice is shown by the light blue line, small bowel by the green line, rectum by the red line and bladder by the yellow line.

Figure 2: The circle shows WPI, the square shows LI for concomitant boost AHF and the triangle shows boost LI to final target volume. Ideal overall treatment time is six weeks.

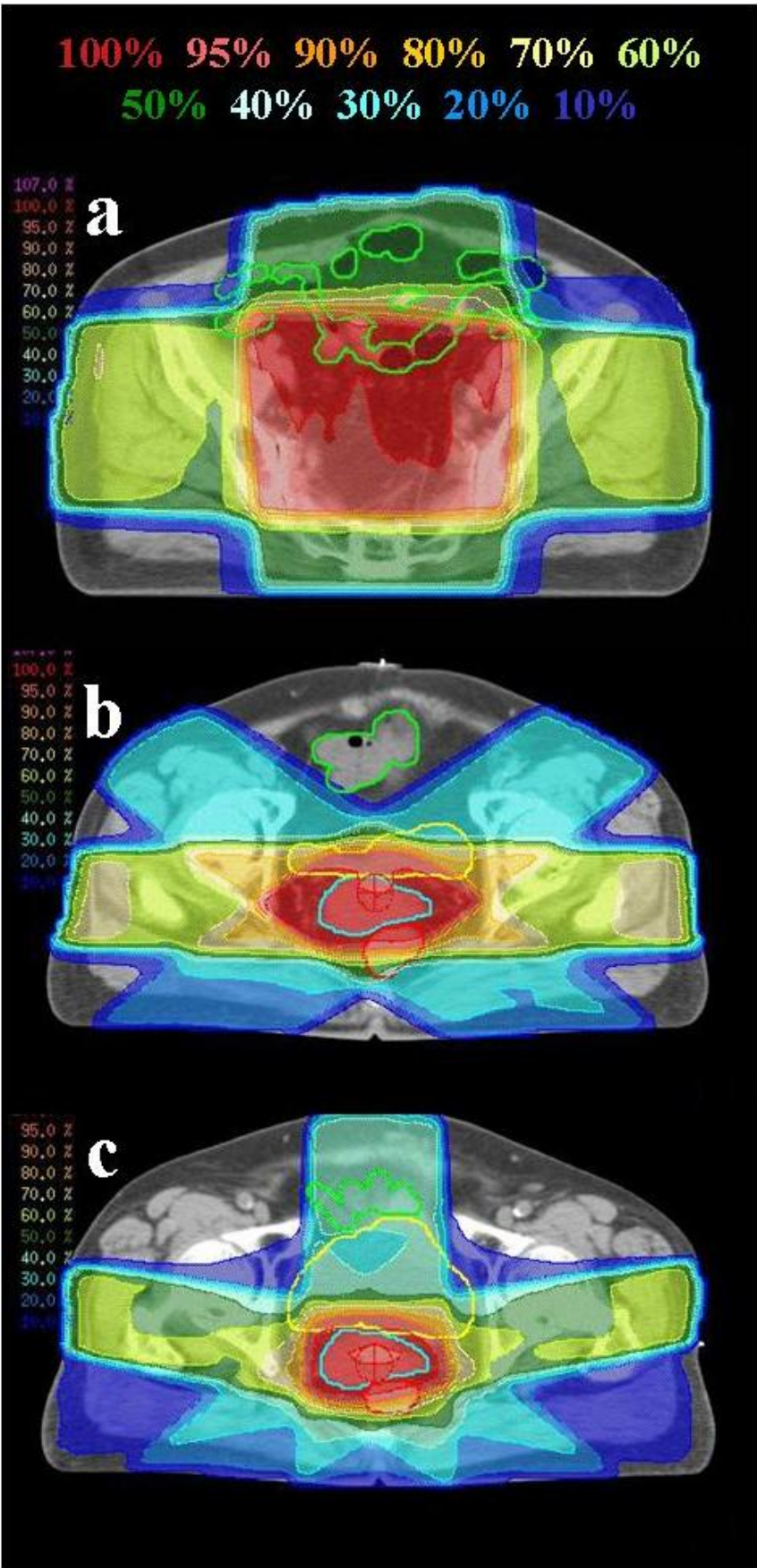


Figure 1



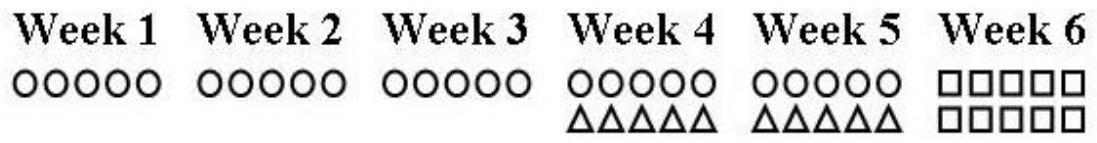


Figure 2

**Table 1:** Patients and tumor characteristics

Patient no.	Age (years)	PS	FIGO stage	Maximum tumor size (cm)	Hydronephrosis	Lymph Node Metastasis
1	82	1	IIIB	7	-	-
2	74	0	IIB	5	-	-
3	81	1	IIIB	6	-	-
4	83	1	IB	1.5	-	-
5	79	0	IVA	8	-	-
6	73	0	IIB	4	-	-
7	99	1	IIIA	3.5	-	-

Abbreviations: PS, performance status; FIGO, International Federation of Gynecology and Obstetrics.

**Table 2:** Clinical outcomes

Patient No.	Clinical response	Local recurrence	Regional recurrence	Distant metastasis	Outcome or survival	Months
1	CR	-	-	Lung (18M)	Alive with disease	37
2	CR	-	-	-	Alive/NED	34
3	PR	+	-	-	Died of cancer	6
4	CR	-	-	-	Alive/NED	25
5	CR	-	-	-	Alive/NED	17
6	CR	-	-	-	Alive/NED	17
7	CR	-	-	-	Alive/NED	15

Abbreviations: CR, complete response; PR, partial response; NED, no evidence of disease.