

Eyelid Lengthening Combined with Penetrating Keratoplasty for Exposure Keratopathy in Graves' Ophthalmopathy — A case report

Mina SUZUKI, Atsushi MINAMOTO, Yumi ISHIDA, Sayaka AOKI, Ken YAMANE
and Hiromu K. MISHIMA

Department of Ophthalmology and Visual Science, Graduate School of Biomedical Sciences, Hiroshima University, 1-2-3, Kasumi, Minami-ku, Hiroshima 734-8551, Japan

ABSTRACT

Upper eyelid retraction is a well-known component of Graves' disease. With greater degrees of retraction, corneal exposure is usually increased. We report here on a patient with corneal perforation following exposure keratopathy due to upper eyelid retraction. The patient was treated with penetrating keratoplasty and an upper eyelid lengthening procedure using Gore-tex® dura substitute as an interpositional graft material. The exposure keratopathy resolved postoperatively and this condition has been maintained for 45 months since the operation, with a good cosmetic outcome and symmetry of the palpebral fissures.

Key words: *Eyelid lengthening, Polytetrafluoroethylene, Graves' ophthalmopathy*

Upper eyelid retraction may cause functional and cosmetic problems in patients with Graves' ophthalmopathy. Various surgical procedures have been described to correct eyelid retraction^{1,2,7,9,11,12}.

We treated a patient who had exposure keratopathy due to unilateral upper eyelid retraction from Graves' disease. The patient eventually demonstrated corneal perforation. Lamellar keratoplasty with a cryopreserved cornea alone was performed as the first procedure. It resulted in recurrent exposure keratopathy with persistent epithelial defect and stromal thinning. We then adopted penetrating keratoplasty combined with an eyelid lengthening procedure using Gore-tex® (PTFE: polytetrafluoroethylene) dura substitute as an interpositional graft material to correct the upper eyelid retraction. The exposure keratopathy resolved, and the condition has remained stable for 45 months since the operation, with a good cosmetic outcome and symmetry of the palpebral fissures.

CASE REPORT

A 66-year-old woman was referred to our hospital for corneal perforation with unilateral eyelid retraction in the left eye, on October 10, 1998. She had been treated for exposure keratopathy in the left eye with eyelid closure by surgical tape for one

and a half years. On examination, best-corrected visual acuity was 0.7 RE, and s.l. LE. Slitlamp biomicroscopy revealed perforation of the central cornea in the left eye with tissue debris around the site of perforation (Fig. 1) and flat anterior chamber. The crystalline lens was invisible. A lamellar keratoplasty with a cryopreserved cornea was performed the next day. Intraocular pressure (IOP) rose to 60 mmHg on the second postoperative day. On the third postoperative day, pars

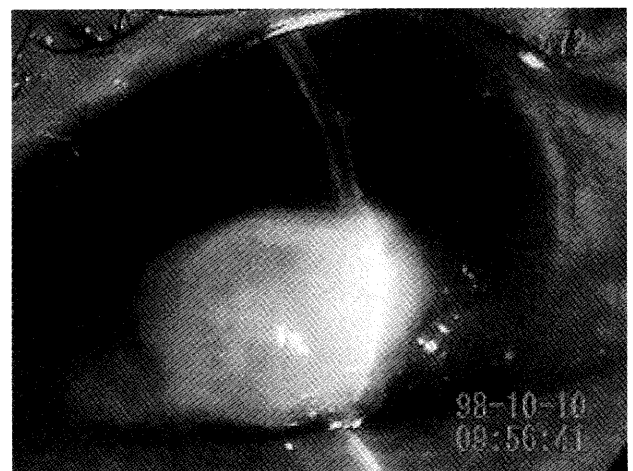


Fig. 1. The central left cornea is perforated; tissue debris is seen around the site of perforation.

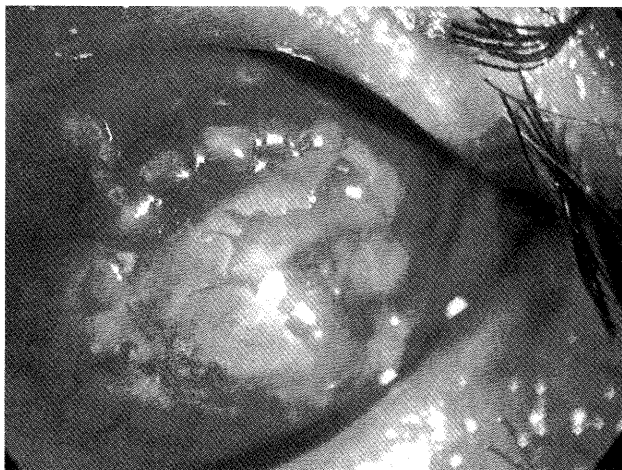

Fig. 2. The central donor lamellar graft shows persistent epithelial defect and stromal thinning.

plana phacofragmentation with vitrectomy was performed. After this operation, IOP lowered to the normal range. The patient was diagnosed as having Graves' disease by magnetic resonance imaging of the orbit (fusiform enlargement of the extraocular muscles), a radioactive iodine uptake test (59.5%), and serum tests including thyroid function tests (freeT3; 7.0 pg/ml, freeT4; 2.1 pg/ml, TSH; insensitive) and thyroid antibodies (thyroid receptor antibody; positive, TSH-binding inhibitory immunoglobulin; 20.9%).

Postoperatively, exposure keratopathy recurred and gradually worsened with persistent epithelial defect and stromal thinning of the central cornea (Fig. 2). The amount of the left upper eyelid retraction was 3 mm. We then performed penetrating keratoplasty with an organ-cultured donor cornea, combined with an upper eyelid lengthening procedure using Gore-tex® (PTFE: polytetrafluoroethylene, W.L. Gore & Associates, Flagstaff, AZ) dura substitute as an interpositional graft material to correct upper eyelid retraction. First, an incision was made through the skin and orbicularis oculi muscle at the level of the upper eyelid crease. Then, the levator aponeurosis was dissected off the tarsal plate and separated from the underlying Mueller's muscle, and the medial and lateral horns were transected. The peripheral vascular arcade was identified and avoided. The 0.3 mm thick dura substitute was fashioned to 10 mm in width and 11 mm in length. This interpositional graft material was sutured to the tarsal plate and the levator muscle with three interrupted 7-0 nylon sutures (Fig. 3). The skin was closed with 6-0 nylon sutures. Immediately following the lengthening procedure, a penetrating keratoplasty was performed. The full-thickness donor cornea was secured with 16 interrupted 10-0 nylon sutures.

After the operation, bilateral symmetry of the palpebral fissures was achieved and no recurrence

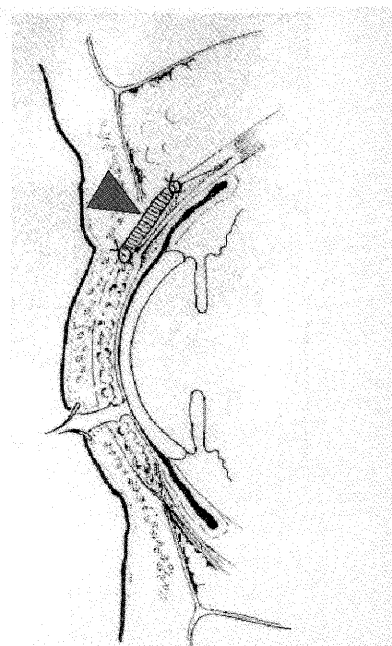


Fig. 3. Interpositional graft material (arrowhead) was sutured to the tarsal plate and the levator muscle with interrupted 7-0 nylon sutures.

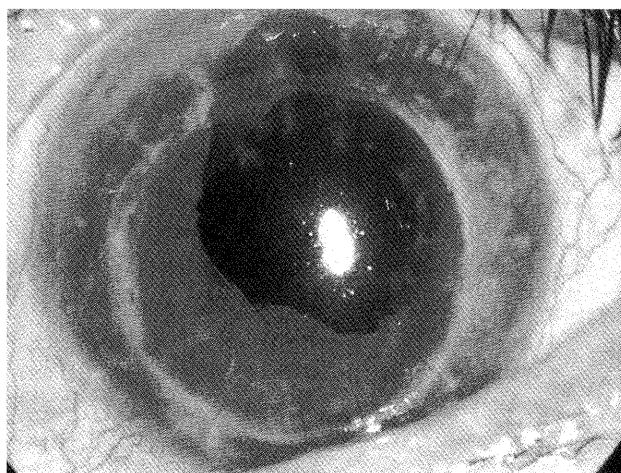


Fig. 4. The graft cornea has remained clear for 45 months postoperatively.

of exposure keratopathy has been noted for 45 months (Fig. 4). At present, the patient is being treated only with topical artificial tears.

DISCUSSION

Upper eyelid retraction usually does not require lid lengthening with spacer grafts for the correction of the retraction itself. It may be treated by Mueller's muscle resection or by combined levator tenotomy and Muellerectomy. In the present case, the cornea had already developed severe exposure keratopathy that led to corneal perforation. A lamellar keratoplasty with a cryopreserved cornea resulted in recurrent exposure keratopathy. Therefore, to prevent further progression of exposure keratopathy, we adopted keratoplasty combined with correction of the upper eyelid

retraction by spacer grafts to achieve sufficient lid closure.

A variety of autogenous graft materials, such as auricular or nasal cartilage, has been used in the correction of eyelid retraction^{1,2,7,9,11,12}. However, their use as interpositional grafts may result in a bulky eyelid. Homologous sclera may be used as either a fresh or preserved product, and it can be easily obtained. However, tissue reactions to scleral tissue can occur and result in graft shrinkage. In addition, donor-to-host disease transmission is possible with the use of homologous sclera⁶.

Polytetrafluoroethylene (PTFE) is a material consisting of nodules of PTFE connected by tiny fibrils. It has been used as a vascular prosthesis. It is an ideal tissue because it allows connective tissue to grow through its pores, and vascularization often occurs in the graft. Because of its inert characteristic and hydrophobicity, only minimal inflammation occurs. The PTFE graft also tends to have poor epithelialization and demonstrates poor adhesion between graft and surrounding tissue. It may therefore be suitable for interpositional graft material within the eyelid⁸. Karesh et al and others have reported that this material was well tolerated within the lower eyelids. Moreover, histopathologic examination of the graft showed capillary and connective ingrowth into the graft matrix^{3,5,10}. Because PTFE is a synthetic material, it is readily available and free from problems associated with homologous sclera.

Corneal epithelial defects in Graves' disease are most probably caused by the increased width of the palpebral fissure due to proptosis and/or eyelid retraction, which accelerates tear film evaporation and increases tear film osmolarity with resulting ocular damage⁴. If left untreated, this condition can ultimately lead to ulceration and corneal perforation, as seen in our patient. We have shown that the penetrating corneal graft remained clear with no recurrence of exposure keratopathy for as long as 45 months postoperatively, together with a good cosmetic outcome. The use of a PTFE dura substitute may, therefore, be useful in eyelid lengthening surgery to treat upper eyelid retraction complicated by severe exposure keratopathy.

REFERENCES

1. Crawford, J.S. and Easterbrook, M. 1976. The use of bank sclera to correct lid retraction. *Can. J. Ophthalmol.* **11**: 304–328.
2. Doxanas, M.S. and Dryden, R.M. 1981. The use of sclera in the treatment of dysthyroid eyelid retraction. *Ophthalmology* **88**: 887–894.
3. Fabrega, M.A., Glaros, D.S. and Karesh, J.W. 1988. Biocompatibility of polytetrafluoroethylene grafts: *in vitro* and *in vivo* studies. *ARVO Abstracts. Invest. Ophthalmol. Vis. Sci.* **29** (Suppl): 212.
4. Gilbard, J.P. and Farris, R.L. 1983. Ocular surface drying and tear film osmolarity in thyroid eye disease. *Acta Ophthalmol. (Copenh)* **61**: 108–116.
5. Karesh, J.W. 1987. Polytetrafluoroethylene as a graft material in ophthalmic plastic and reconstructive surgery: an experimental and clinical study. *Ophthalmic Plast. Reconstr. Surg.* **3**: 179–185.
6. Karesh, J.W., Fabrega, M.A., Rodrigues, M.M. and Galros, D.S. 1989. Polytetrafluoroethylene as an interpositional graft material for the correction of lower eyelid retraction. *Ophthalmology* **96**: 419–423.
7. Matsuo, K., Hirose, T., Takahashi, N., Iwasawa, M. and Satoh, R. 1987. Lower eyelid reconstruction with a conchal cartilage graft. *Plast. Reconstr. Surg.* **80**: 547–552.
8. Nguyen, Q.D. and Foster, C.S. 1999. Scleral patch graft in the management of necrotizing scleritis. *Int. Ophthalmol. Clin.* **39**: 109–131.
9. Putterman, A.M. 1980. Surgical treatment of dysthyroid eyelid retraction and orbital fat hernia. *Otolaryng. Clin. North Am.* **13**: 39–51.
10. Van der Lei, B. and Wildevuur, C.R. 1988. Microvascular polytetrafluoroethylene prostheses: the cellular events of healing and prostacyclin production. *Plast. Reconstr. Surg.* **81**: 735–741.
11. Waller, R.R. 1982. Eyelid malpositions in Graves' ophthalmopathy. *Trans. Am. Ophthalmol. Soc.* **80**: 855–930.
12. Zbylski, J.R., LaRossa, D.D. and Rich, J.D. 1978. Correction of lower eyelid ptosis in the anophthalmic orbit with an autogenous ear cartilage graft. *Plast. Reconstr. Surg.* **61**: 220–224.

(Received May 27, 2004)

(Accepted July 12, 2004)